

# Immunoglobulin A Vasculitis Complicated with *Clostridium difficile* Infection: a Rare Case Report and Brief Review of the Literature

Camelia Cojocariu<sup>1,2</sup>, Carol Stanciu<sup>2</sup>, Codrina Ancuta<sup>1,3</sup>, Mihai Danciu<sup>1,2</sup>, Stefan Chiriac<sup>1</sup>, Anca Trifan<sup>1,2</sup>

1) Gr. T. Popa University of Medicine and Pharmacy,  
2) St. Spiridon Emergency Hospital, Institute of Gastroenterology and Hepatology, and  
3) Rehabilitation Hospital, Iasi, Romania

**Address for correspondence:**  
Prof. Carol Stanciu  
St. Spiridon Emergency Hospital, Institute of Gastroenterology and Hepatology,  
Iasi, Romania  
[stanciucarol@yahoo.com](mailto:stanciucarol@yahoo.com)

## ABSTRACT

Immunoglobulin A (IgA) vasculitis, formerly called Henoch-Schönlein purpura, is a leukocytoclastic type of vasculitis affecting small vessels with a deposition of immune IgA complexes, clinically characterized by the classic tetrad of nonthrombocytopenic palpable purpura, arthralgia (or arthritis), and gastrointestinal and renal involvement. Although the cause of the disease remains unknown, immune complexes of IgA and unidentified antigens seem to play a central pathogenic role. The diagnosis is easily established in the presence of purpura, but may be challenging in its absence, especially when colicky abdominal pain precedes the cutaneous lesions. IgA vasculitis is usually a self-limited disease with a benign course and symptomatic treatment is sufficient for most; in severe cases, however, corticosteroids are necessary.

We describe the case of a young adult male presenting with severe abdominal pain, vomiting and fever (38.4°C). Clinical examination, abdominal ultrasound and plain abdominal radiography excluded an acute abdomen. The occurrence of arthralgia involving both knees and erosive duodenitis at endoscopy, 48 hours upon admission, suggested the diagnosis of IgA vasculitis, confirmed on the following day by the presence of typical purpuric rash on the lower extremities. Corticosteroid therapy led to the resolution of all gastrointestinal and joint manifestations as well as to a significant improvement of cutaneous purpura. However, during the 3rd week of corticosteroid treatment, the patient developed watery diarrhea and the clinical suspicion of *Clostridium difficile* infection (CDI) was confirmed. The treatment with metronidazole led to the resolution of diarrhea. The peculiarity of this case resides in several aspects: the gastrointestinal and joint manifestations preceded purpura, making diagnosis more difficult; CDI is an extremely rare complication of IgA vasculitis, being, in fact, the second case reported in adults in the literature.

**Key words:** Henoch-Schönlein purpura – IgA vasculitis – *Clostridium difficile* – gastrointestinal involvement.

**Abbreviations:** CDI: *Clostridium difficile* infection; CRP: C-reactive protein; EGD: esophagogastroduodenoscopy; ESR: erythrocyte sedimentation rate; IgA: immunoglobulin A; WBC: white blood cell.

Received: 08.02.2016  
Accepted: 02.03.2016

## INTRODUCTION

Immunoglobulin A (IgA) vasculitis, formerly known as Henoch-Schönlein purpura, is a nongranulomatous immunoglobulin A-mediated complex small-vessels vasculitis, clinically characterized by the classic tetrad of nonthrombocytopenic palpable purpura, arthralgia (or arthritis), and gastrointestinal and renal involvement. The term IgA

vasculitis was chosen to replace the eponym *Henoch-Schönlein purpura* by the 2012 revised Chapel Hill International Consensus Conference for Nomenclature of Vasculitides [1]. It relates to the IgA1-dominant immune deposits affecting small vessels and typically involving skin, joints, gastrointestinal tract and kidneys. The cause and pathogenesis are still unknown, although precipitating factors such as drug intake and/or upper respiratory tract infections have been associated with the development of IgA vasculitis [2]. Some studies suggested that glycosylation of the hinge region of IgA1 is involved in the pathogenesis of the disease [3].

IgA vasculitis is commonly seen in children and very rarely in adults, the annual incidence varying greatly, from 3-26/100,000 in children to 0.8-1.8/100,000 in adults [4, 5].

Clinical features and severity of the disease also differ, being more severe in adults as compared to children [6, 7].

IgA vasculitis is mainly a clinical diagnosis, easily made in the presence of skin purpura, turning more difficult when the onset is accompanied by gastrointestinal manifestations, without cutaneous purpuric rash [8]. On esophagogastroduodenoscopy (EGD), the second part of the duodenum is most frequently and severely involved, and the presence of erosive duodenitis is helpful for diagnosing IgA vasculitis in patients without pathognomonic skin purpura. On histopathology there is leukocytoclastic vasculitis with IgA-immune deposits in the walls of the small vessels (capillaries, arterioles, venules) on immunofluorescence staining. IgA vasculitis is usually a self-limited disease; the treatment is often symptomatic, although, in rare (and severe) cases, corticosteroids are necessary.

IgA vasculitis complicated by *Clostridium difficile* infection (CDI) is extremely rare. To our knowledge, so far, there are only four cases in children and one in an adult published in the literature [9-12]. This makes our case the second of its type (in an adult with IgA vasculitis complicated by CDI) reported in the literature.

We will review the currently existing data on the epidemiology, pathogenesis, diagnosis and treatment of IgA vasculitis and discuss the risk factors of CDI development in patients with this condition.

## CASE PRESENTATION

A 19-year-old male presented in the Emergency Department with severe intermittent diffuse abdominal pain, vomiting and fever (38.4°C). Two weeks before, he had had a sore throat, for which his primary care physician prescribed oral antibiotics (amoxicillin). On clinical examination, vital signs were stable, the abdomen was distended and tender, without guarding, and the review of systems was unremarkable. Of note, there was no skin rash. Laboratory analyses (normal ranges between parentheses) showed the following: leucocytosis with white blood cell (WBC) count of 18,450 cells/ $\mu$ L (4,000-10,000 cells/ $\mu$ L) and 81% neutrophils (45-80%); elevated erythrocyte sedimentation rate (ESR) 39 mm/h (1-13 mm/h) and C-reactive

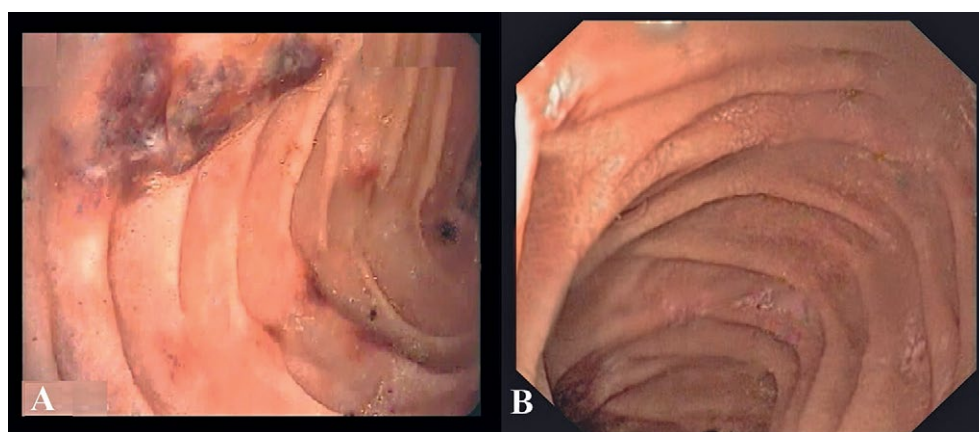
protein (CRP) 8.84 mg/dL (0.01-0.50 mg/dL); the rest of the lab tests, including hematologic, liver and renal function tests, serum electrolytes and coagulation parameters were within normal limits. Urinalysis showed microscopic hematuria [25 erythrocytes/HPF (<5/HPF)]. Plain abdominal radiograph showed no signs of bowel obstruction, and abdominal ultrasound excluded an intussusception.

The patient was admitted to our institution where, the following day, he had diarrhea streaked with blood. Sigmoidoscopy showed redness of the mucosa and petechiae, and stool testing for *Clostridium difficile* (*C. difficile*) toxins A and B was negative. On the 3rd day of hospitalisation, the patient complained of arthralgia in both knees, and a repeated set of laboratory tests showed a huge increase in the number of WBC (36,400 cells/ $\mu$ L) with 89% neutrophils, as well as elevated ESR (54 mm/h) and CRP level (9.61 mg/dL). Abdominal pain, aggravated by meals, continued to worsen despite symptomatic therapy, and the patient accepted to undergo an EGD, which showed severe erosive duodenitis (Fig. 1A). Based on joint and gastrointestinal symptoms, IgA vasculitis was clinically suspected and confirmed a day after (4th day of hospitalisation) by the occurrence of a purpuric rash on the lower extremities (Fig. 2).

The patient received intravenous methylprednisolone (125 mg/day), which determined a spectacular resolution of abdominal pain and arthralgias within 48 hours, as well as a great improvement in laboratory results. Intravenous corticosteroid therapy was replaced by oral prednisone with a gradual reduction in dosage. However, the 3rd week of treatment was marked by episodes of watery diarrhea and, this time, stool testing for *C. difficile* confirmed the presence of toxins A and B. Treatment with metronidazole (500 mg x 3/day for 10 days) led to the resolution of symptoms. By the end of the 4th week of his hospital stay, purpura disappeared and a repeated upper endoscopy showed normal duodenal mucosa (Fig. 1B), all laboratory tests were normal and the patient was discharged in good health.

## DISCUSSION

We hereby report a case of IgA vasculitis in a young adult, characterized by some peculiarities such as the onset of the



**Fig. 1.** Endoscopic appearance of the second part of the duodenum: A) (before treatment): multiple erosions, diffuse redness, submucosal hemorrhage, petechiae, small ulcerations; B) (after treatment): significant improvement of endoscopic appearance

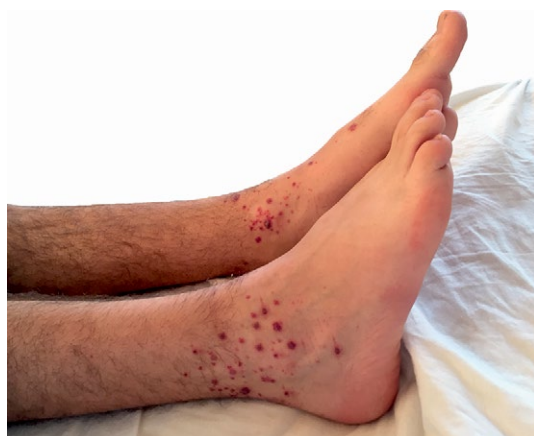

Fig. 2. Palpable purpura on both ankles.

disease with gastrointestinal and joint manifestations prior to the occurrence of skin purpura, complicated by CDI during corticosteroid therapy. To the best of our knowledge, this is the second published case of IgA vasculitis complicated by CDI in adults. Upon a thorough search, we found only five cases reported so far: four children [9-11] and one adult [12]. The authors suggested that antibiotic therapy, intestinal lesions (mucosal ischemia) caused by IgA vasculitis and corticosteroid therapy could have led to a change in intestinal microbiota and, consequently, to overgrowth of *C. difficile*, increasing the risk of CDI. The use of antibiotic therapy remains the most important risk factor for the development of CDI [13]. Our patient received antibiotics (amoxicillin) for a pharyngitis, prescribed by his primary care physician; in addition, it was the patient's 3rd week of corticosteroid therapy, which may have played a key role in the developing of CDI.

Formerly called Henoch-Schönlein purpura, IgA vasculitis is a self-limited systemic, nongranulomatous, immunoglobulin A-mediated complex small-vessel vasculitis, with multiorgan involvement. The etiology of the disease remains unknown, but it was often associated with previous bacterial or viral infections (most frequently upper respiratory infections), medication, tumors, hematological malignancies, and vaccinations [3, 6]. The exaggerated immune response to the above mentioned triggering factors leads to IgA1 and C3 immune complex deposition in small vessels (arterioles, venules, capillaries) of the skin, joints, gastrointestinal tract and kidneys [3, 14].

IgA vasculitis is common in children, and very rare in adults. Childhood disease and adult disease differ. In children, the IgA vasculitis is generally benign and self-limited, while in adults, clinical presentation tends to be atypical, with higher rates of severe gastrointestinal, renal, and joint involvement [6, 15].

IgA vasculitis is mainly a clinical diagnosis, easily set in a patient presenting with the classic tetrad of nonthrombocytopenic purpura, joint, gastrointestinal, and renal involvement. However, when the presentation is with atypical features, tissue biopsy is helpful, showing leukocytoclastic vasculitis (the presence of granulocytes in walls of small vessels) with IgA deposition on immunofluorescence [16]. There are several diagnostic criteria proposed by the European League Against Rheumatism (EuLAR), Pediatric Rheumatology Society (PRES), and the American College of Rheumatology [8, 17].

Differential diagnosis includes Crohn's disease (there is no palpable purpura), IgA nephropathy (no palpable purpura), and hypersensitivity vasculitis (absence of IgA deposition).

Skin lesions are the most common presentation and include nonthrombocytopenic rash, which evolves from erythema to papules, then to nonblanching palpable purpura with petechiae and ecchymosis. Purpura is the presenting symptom in half of the cases, often with symmetrical distribution, localized on the lower extremities, frequently around the ankles and buttocks, but it can also involve the upper extremities.

Gastrointestinal involvement occurs in about 2/3 of cases. Abdominal colicky pain worsened by meals is frequent and often associated with nausea, vomiting, and gastrointestinal bleeding (hematemesis or melena). Symptoms are caused by bowel ischemia and edema, and in very few cases, serious complications such as perforation, infarction or intussusceptions may occur [18, 19]. On upper gastrointestinal endoscopy, the most important finding is severe erosive duodenitis (in the second part of the duodenum), characteristic, but not pathognomonic for IgA vasculitis [20]. Other endoscopic findings include erythema, petechiae, ulcers, and ecchymotic lesions seen in the gastric antrum, second portion of the duodenum, ileum, and colon. On CT imaging, bowel involvement is seen as a circumferential, regular, symmetrical wall thickening with target appearance (however, the target sign is not specific for vasculitis) with engorgement of mesenteric vessels. In 10% of cases, gastrointestinal manifestations precede skin purpura and, in such cases, a differential diagnosis should be made with other causes of acute abdomen [8, 21]. At the disease onset, our patient experienced severe abdominal pain, four days before the occurrence of purpura.

Joint involvement (arthralgia, arthritis) is present in 2/3 of the patients, more often in adults than in children. Typically, it involves the knees and ankles, and is symmetrical in distribution.

Renal involvement is found in 40-50% of patients, ranging from microscopic hematuria (the earliest and most common symptom) to progressive glomerulonephritis. Proteinuria is often associated to hematuria. Renal failure is rare in children, while it may be present in about 30% of adult cases [22].

Treatment is often symptomatic because the disease is self-limited and has a benign course. Oral corticosteroid therapy is indicated in patients with severe joint, rash, as well as gastrointestinal and renal involvement [23]. If no benefit is obtained from corticosteroid therapy alone, immunosuppressive drugs (such as cyclosporine A, cyclophosphamide, and mycophenolate mofetil) are recommended and may be useful especially in those with rapidly progressive glomerulonephritis. Other agents (dapsone, rituximab) have also been shown to induce remission of symptoms [22-25].

## CONCLUSION

We present a very rare case of IgA vasculitis complicated by CDI. The latter may have been caused by the changes in gut microbiota induced by antibiotic therapy administered prior to hospital admission and the corticosteroids administered for the treatment of the IgA vasculitis. Not only is this the second case of adult IgA vasculitis complicated by CDI, but

the gastrointestinal and joints, manifestations occurring several days before skin purpura make it even more distinctive.

**Conflicts of interest:** None to declare.

**Authors' contribution:** C.C. and C. A. diagnosed and treated the patient; C.S. designed and wrote the report; S.C. collected literature data; M.D. performed histological assessment; A.T. reviewed the manuscript for its intellectual content. All authors read and approved the final version of the manuscript.

## REFERENCES

- Jennette JC, Falk RJ, Bacon PA, et al. 2012 revised International Chapel Hill Consensus Conference Nomenclature of Vasculitides. *Arthritis Rheum* 2013; 65: 1-11. doi: [10.1002/art.37715](https://doi.org/10.1002/art.37715)
- Gonzales-Gay MA, Calvino MC, Vazquez-Lopez ME, et al. Implication of upper respiratory tract infections and drugs in the clinical spectrum of Henoch-Schönlein purpura in children. *Clin Exp Rheumatol* 2004; 22: 781-784.
- Saulsbury FT. Clinical update: Henoch-Schönlein purpura. *Lancet* 2007; 369: 976-978. doi: [10.1016/S0140-6736\(07\)60474-7](https://doi.org/10.1016/S0140-6736(07)60474-7)
- Gardner-Medwin J, Dolezalova P, Cummins C, Southwood TR. Incidence of Henoch-Schönlein purpura, Kawasaki disease, and rare vasculitides in children of different ethnic origins. *Lancet* 2002; 360: 1197-1202. doi: [10.1016/S0140-6736\(02\)11279-7](https://doi.org/10.1016/S0140-6736(02)11279-7)
- Watts RA, Lane S, Scott DG. What is known about the epidemiology of the vasculitides? *Best Pract Res Clin Rheumatol* 2005; 19: 191-207. doi: [10.1016/j.berh.2004.11.006](https://doi.org/10.1016/j.berh.2004.11.006)
- Garcia-Porrúa C, Calvino MC, Llorca J, Couselo JM, Gonzales-Gay MA. Henoch-Schönlein purpura in children and adults: clinical differences in a defined population. *Semin Arthritis Rheum* 2002; 32: 149-156. doi: [10.1053/sarh.2002.33980](https://doi.org/10.1053/sarh.2002.33980)
- Schaier M, Freitag J, Dikow R, et al. Henoch-Schönlein purpura in adults is not uncommon in elderly patients with an adverse prognosis. *Clin Nephrol* 2011; 76: 49-56. doi: [10.5414/CN106900](https://doi.org/10.5414/CN106900)
- Mills JA, Michel BA, Bloch DA, et al. The American College of Rheumatology 1990 criteria for the classification of Henoch-Schönlein purpura. *Arthritis Rheum* 1990; 33: 1114-1121. doi: [10.1002/art.1780330809](https://doi.org/10.1002/art.1780330809)
- Narchi H, Beattie TJ, Taylor RG, Evans TJ, Azmy AF. Pseudomembranous colitis in association with Henoch-Schönlein purpura. *Scott Med J* 1988; 33: 308-309.
- Boey CC, Ramanujam TM, Looi LM. Clostridium difficile-related necrotizing pseudomembranous enteritis in association with Henoch-Schönlein purpura. *J Pediatr Gastroenterol Nutr* 1997; 24: 426-429. doi: [10.1097/00005176-199704000-00012](https://doi.org/10.1097/00005176-199704000-00012)
- Alsaied T, Weber J, George A, Villegas M, Vossmeier TM. An adolescent with abdominal pain, rash, joint swelling, severe bloody diarrhea, and impressive leukocytosis. *Clinical Pediatr* 2014; 53: 1206-1208. doi: [10.1177/0009922814536266](https://doi.org/10.1177/0009922814536266)
- Hayakawa T, Imaeda H, Nakamura M, et al. Association of pseudomembranous colitis with Henoch-Schönlein purpura. *J Gastroenterol* 2005; 40: 641-645. doi: [10.1007/s00535-005-1599-7](https://doi.org/10.1007/s00535-005-1599-7)
- Khanna S, Pardi DS. The growing incidence and severity of Clostridium difficile infection in inpatient and outpatient settings. *Expert Rev Gastroenterol Hepatol* 2010; 4: 409-416. doi: [10.1586/egh.10.48](https://doi.org/10.1586/egh.10.48)
- Watson L, Richardson AR, Holt RC, Jones CA, Beresford MW. Henoch-Schönlein purpura—a 5-year review and proposed pathway. *PLoS One* 2012; 7: e29512. doi: [10.1371/journal.pone.0029512](https://doi.org/10.1371/journal.pone.0029512)
- Blanco R, Martínez-Taboada VM, Rodríguez-Valverde V, García-Fuentes M, González-Gay MA. Henoch-Schönlein purpura in adulthood and childhood: two different expressions of the same syndrome. *Arthritis Rheum* 1997; 40: 859-864. doi: [10.1002/art.1780400513](https://doi.org/10.1002/art.1780400513)
- Sohagia AB, Gunturu SG, Tong TR, Hertan HI. Henoch-Schönlein purpura – a case report and review of the literature. *Gastroenterol Res Pract* 2010; 2010: 597648. doi: [10.1155/2010/597648](https://doi.org/10.1155/2010/597648)
- Ozen S, Ruperto N, Dillon MJ, et al. EULAR/PRReS endorsed consensus criteria for the classification of childhood vasculitides. *Ann Rheum Dis* 2006; 65: 936-941. doi: [10.1136/ard.2005.046300](https://doi.org/10.1136/ard.2005.046300)
- Esaki M, Matsumoto T, Nakamura S, et al. GI involvement in Henoch-Schönlein purpura. *Gastrointest Endosc* 2002; 56: 920-923. doi: [10.1016/S0016-5107\(02\)70376-3](https://doi.org/10.1016/S0016-5107(02)70376-3)
- Chen SY, Kong MS. Gastrointestinal manifestation and complications of Henoch-Schönlein purpura. *Chang Gung Med J* 2004; 27: 175-181.
- Chen XL, Tian H, Li JZ, et al. Paroxysmal drastic abdominal pain with tardive cutaneous lesions presenting in Henoch-Schönlein purpura. *World J Gastroenterol* 2012; 18: 1991-1995. doi: [10.3748/wjg.v18.i16.1991](https://doi.org/10.3748/wjg.v18.i16.1991)
- Prathiba Rajalakshmi P, Srinivasan K. Gastrointestinal manifestations of Henoch-Schönlein purpura: a report of two cases. *World J Radiol* 2015; 7: 66-69. doi: [10.4329/wjr.v7.i3.66](https://doi.org/10.4329/wjr.v7.i3.66)
- Pillebout E, Verine J. Purpura rhumatoid de l'adulte. *Rev Med Interne* 2014; 35: 372-381. doi: [10.1016/j.revmed.2013.12.004](https://doi.org/10.1016/j.revmed.2013.12.004)
- Audemand-Verger A, Pillebout E, Guillemin L, Thervet E, Terrier B. IgA vasculitis (Henoch-Schönlein purpura) in adults: diagnostic and therapeutic aspects. *Autoimmun Rev* 2015; 14: 579-585. doi: [10.1016/j.autrev.2015.02.003](https://doi.org/10.1016/j.autrev.2015.02.003)
- Pindi Sala T, Michot JM, Snanoudj R, et al. Successful outcome of a corticoid-dependent Henoch-Schönlein purpura adult with rituximab. *Case Rep Med* 2014; 2014: 619218. doi: [10.1155/2014/619218](https://doi.org/10.1155/2014/619218)
- Bech AP, Reichert IJ, Cohen Tervaert JW. Dapsone for the treatment of chronic IgA vasculitis (Henoch-Schönlein). *Neth J Med* 2013; 71: 220-221.