

# MRI imaging in endometriosis: personal study and pictorial review

Raluca Ozana  
Chistol<sup>1,2</sup>,  
Cristina  
Furnica<sup>3</sup>,  
Maria  
Magdalena  
Leon<sup>4</sup>

1. Department of Radiology,  
"Sf. Spiridon" University  
Hospital, Iasi (Romania)

2. "Gr.T.Popa" University  
of Medicine and Pharmacy,  
Iasi (Romania)

3. Department of Anatomy,  
"Gr.T.Popa" University  
of Medicine and Pharmacy,  
Iasi (Romania)

4. Department of Internal  
Medicine,  
"Gr.T.Popa" University  
of Medicine and Pharmacy,  
Iasi (Romania)

Correspondence:  
Raluca Ozana Chistol  
e-mail: ralucachistol@  
gmail.com

## Abstract

Endometriosis represents a frequently encountered pathology of the women at reproductive age that corresponds to the ectopic development of endometrial glands outside the uterine cavity. The purpose of the current study was to evaluate the efficiency of MRI imaging in diagnosing endometriotic lesions. The current study was performed during September 2011 - January 2012 on a total of 38 patients that underwent an 1.5T examination for endometriosis suspected at clinical or ultrasound examination. MRI diagnosed endometriosis in 26 out of the 38 patients, adenomyosis associated to endometriosis in two cases, adenomyosis not associated to endometriosis in one case, abdominal wall endometriotic implant associated to endometriosis in one case and no endometriosis lesions in eight cases. MRI is a method that can realize an accurate presurgical mapping of all localizations of endometriosis. A correct and complete interpretation of the MRI examination facilitates an adapted surgical treatment. The originality of the current study consists in reevaluating the diagnostic criteria for adenomyosis, describing the association of deep endometriosis with uterine adenomyosis and reconsidering the MRI protocol for research of endometriotic lesions.

**Keywords:** adenomyosis, endometriosis, endometrioma, endometriotic implants, MRI

## Introduction

Endometriosis represents a frequently encountered pathology of the women on reproductive age and corresponds to an ectopic development of endometrial glands outside the uterine cavity. The pathogenesis of abdominal endometriosis still represents a subject of debate and there has been proposed three theories: retrograde menstrual/postsurgical migration of endometrial cells into the peritoneal cavity, ovaries or scars, metaplastic differentiation of the Wolff and Muller ducts remaining and hormonal inductive transformation of undifferentiated peritoneal cells into endometrial cells<sup>(1)</sup>.

In practice, three types of localization are identified: external intraperitoneal endometriosis (adnexial or peritoneal), external subperitoneal endometriosis, also known as deep endometriosis (rectovaginal septum, sacrouterine ligaments, digestive, round ligaments, vesico-uterine pouch), and uterine adenomyosis, previously considered as internal endometriosis and now treated as a separate entity<sup>(2,3)</sup>.

Chronic pelvic pain during menstruation is the main clinical symptom. Pain can occur in any moment, especially in the pre- and post-menstrual period.

Endometriosis should also be suspected in all patients addressing for infertility and dyspareunia.

## Material and methods

The study was performed during September 2011 - January 2012 when a total of 38 patients (19-51 years) underwent an MRI 1.5T (magnetic resonance imaging) examination for endometriosis suspected at clinical or ultrasound examination. An informed consent was obtained prior to including into the current study. Pelvic MRI was performed using a Siemens MAGNETOM Symphony 1.5T. Hyoscine N-butylbromide (Buscopan 20 mg/ml) was administered by intravenous injection in all cases in order to reduce intestinal motility. The study protocol included T2 TSE (Turbo Spin Echo) weighted sequences in all the three planes,

Received:  
February 12, 2012

Revised:  
March 28, 2012

Accepted:  
April 6, 2012

T2 TSE sequence with fat saturation in the transversal plane, T1 TSE and T1 TSE with fat saturation sequences in the transversal plane. Slice thickness was of 4 mm in all cases. Injection of contrast agent was not necessary in any of the cases.

## Results

MRI diagnosed lesions of endometriosis in 26 out of the 38 patients (68.42%), adenomyosis associated to endometriosis in two cases (5.26%), adenomyosis not associated to deep endometriosis in one case (2.63%), abdominal wall endometriotic implant associated to deep endometriosis in 1 case (2.63%) and no endometriotic lesion in eight cases (21.05%).

Concerning the anatomical distribution of MRI diagnosed endometriotic lesions, most of them interested the rectovaginal septum (18 cases, 69.23%), the sacrouterine ligaments (15 cases, 57.69%), torus uterinus (12 cases, 46.16%), the adnexes (13 cases, 50%), the pouch of Douglas (9 cases, 34.61%), the posterior vaginal fornix (5 cases, 9.23%), the rectosigmoid serosal

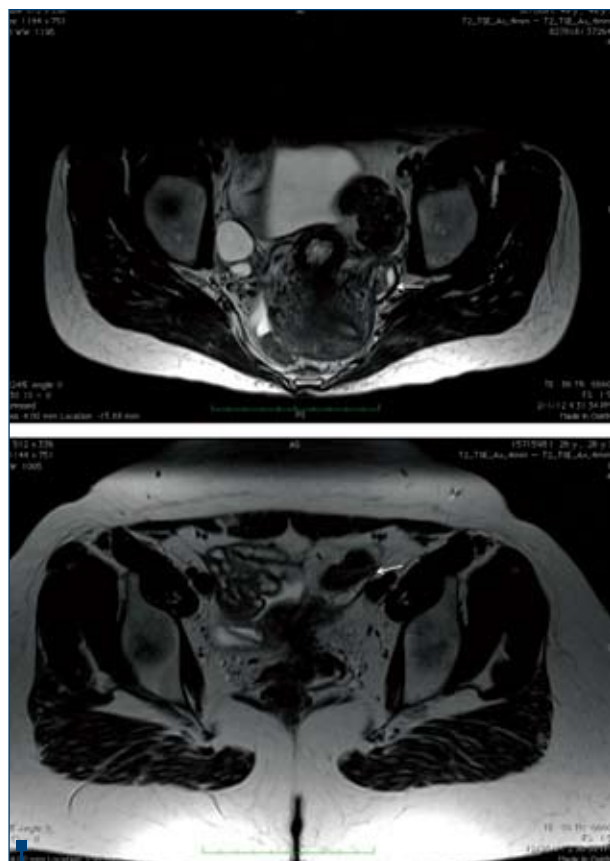surface (five cases, 9.23%), the small intestine serosal surface (two cases, 7.69%), the bladder surface (two cases, 7.69%) and the anterior vaginal fornix (one case, 3.84%) (Figure 1).

Many of the cases presented with pelvic fluid (17 cases - 65.38%) and two patients with intestinal involvement presented peritoneal ascites.

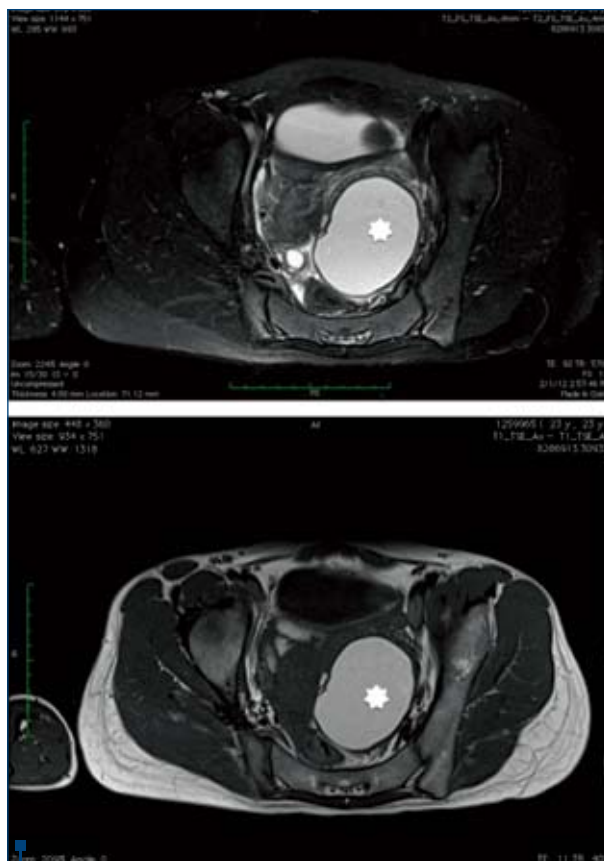
Adnexial involvement consisted in endometriomas (endometriotic cysts) in two cases, endometriomas associated to endometriotic implants in five cases and only endometriotic implants at the rest of 6 patients.

Endometriomas appeared hyperintense in both T1 and T2 weighted sequences with and without fat saturation as they are characterized by a rich glandular component and the presence of hemoglobin degradation products (Figure 2).

Endometriotic implants presented as spiculated, retractile fibrous masses hypointense in both T1 and T2 weighted sequences with and without fat saturation and they were encountered in 9 of the 26 cases



**Figure 1.** Thickening of the left ovarian fossa (a, left) and of the left round ligament (b, right) (T2 weighted sequence)



**Figure 2.** Voluminous endometrioma of the left ovary: high intensity signal in both T2 fat sat (a, left) and T1 (b, right) weighted sequences

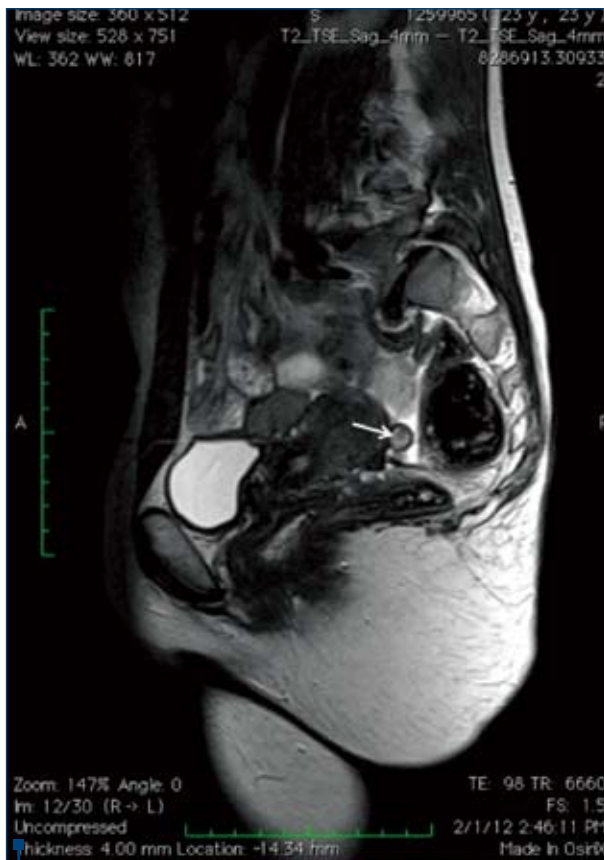


Figure 3. Hemorrhagic endometriotic implant in contact with the fundus of the uterus (T2 weighted sequence)

(34.61%). These implants are responsible for filling of the Douglas pouch (traction of the uterus and rectum), and for the intestinal and ovarian adhesions.

Endometriotic implants were mixed (fibrous masses with hemorrhagic spots) in 7 cases (26.92%) (Figure 3).

Most of the patients (21 patients, representing 80.77%) presented thickening of sacrouterine ligaments, rectovaginal septum, peritoneum, round ligaments or ovarian fosses.

## Discussions

Different authors have proposed many classifications of endometriosis in the last 10 years, but we will be referring in our discussions to the classification proposed by Del Frate in 2006 that divides deep endometriosis into posterior and anterior lesions<sup>(3)</sup>. Anterior lesions are represented by the endometriosis of the bladder detrusor and were encountered in only 2 of 26 deep endometriosis cases (7.7%), comparable with the frequency reported by the international literature of 6.4% in all cases<sup>(4,5)</sup>.

Posterior endometriosis is further subdivi-

ded into retroperitoneal and intraperitoneal lesions. Intraperitoneal lesions are located in the pouch of Douglas, on the rectosigmoid serosal surface and less frequently on the small intestine serosal surface<sup>(2)</sup>, situation confirmed by our study as we identified small intestine lesions in only two cases (Figure 4).

Rectosigmoid endometriotic implants appeared as low signal; often-nodular thickenings of the wall in both T1 and T2 weighted sequences. Three of the five patients with rectosigmoid endometriosis also had endometriotic implants in the pouch of Douglas, an association that needs further investigation.

The local inflammation induced by endometriotic lesions could lead to a total obstruction of the pouch of Douglas, making culdoscopy extremely difficult, if not impossible as Chapron states in his research<sup>(5)</sup>. The adhesences that occur attract backward the posterior surface of the uterus (retroflexion) and the anterior surface of the rectosigmoid colon, forward. All the intestinal loops in

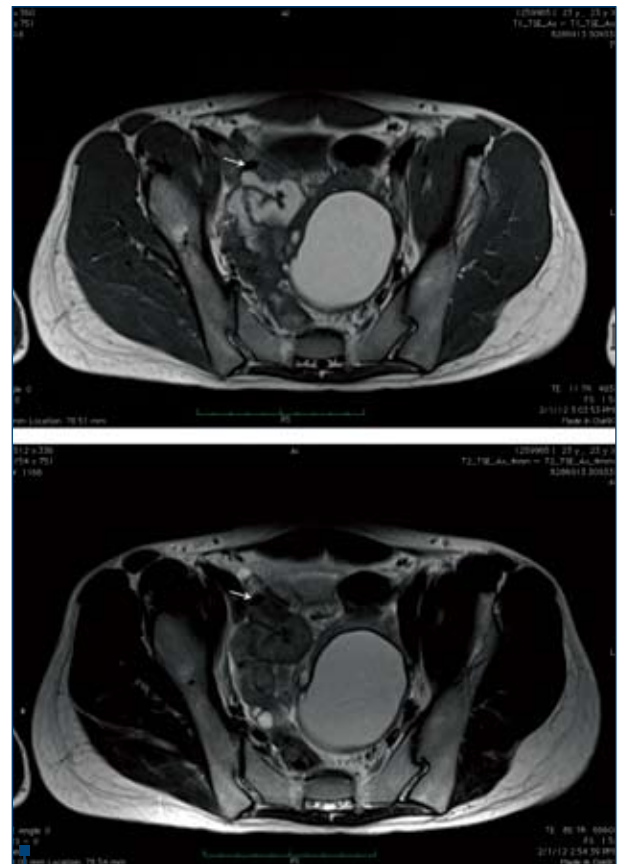

Figure 4. Same patient as in previous image presenting an endometriotic implant with low intensity signal in both T1 (a, left) and T2 (b, right) weighted sequences on the small bowel surface in the right iliac fossa



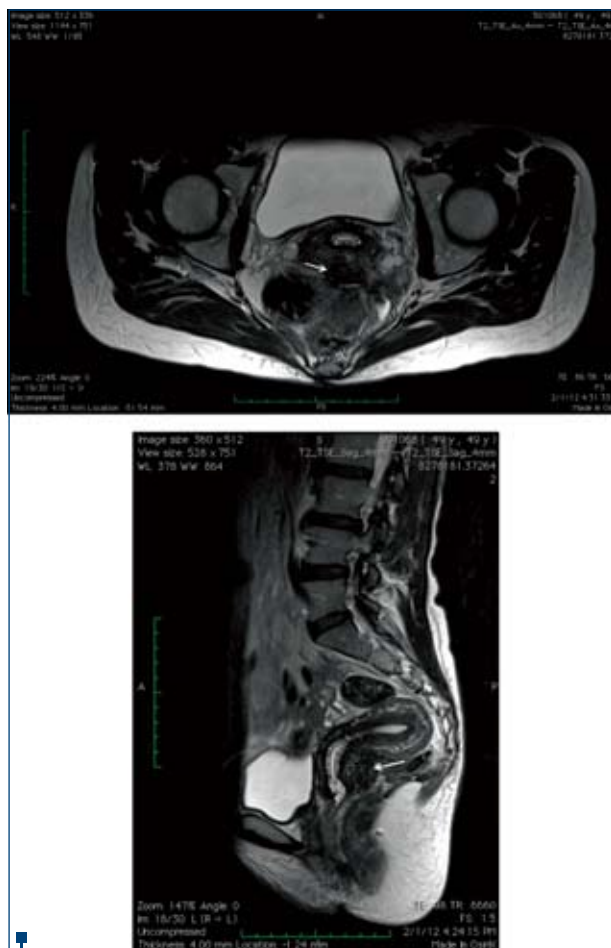

Figure 5. Voluminous endometriotic nodule with hemorrhagic spots developed on the torus uterinus (a, left and b, right), (T2 weighted sequences)

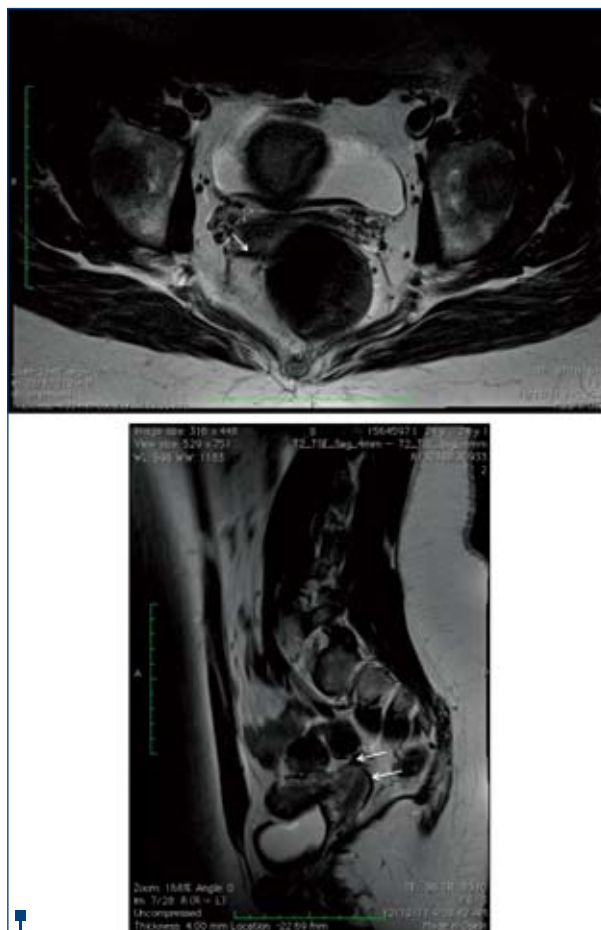

Figure 6. Thickening of the left and nodular thickening of the right sacrouterine ligament (a, left). Thickening the torus uterinus and retractor endometriotic implant attracting the sigmoid colon (b, right) - T2 weighted sequences

the region are attracted towards, while the pouch of Douglas and the posterior vaginal fornix ascends. This particular form of endometriosis was associated in our study with a severe clinical presentation (severe dysmenorrhea, pain)<sup>(6)</sup>.

Retroperitoneal endometriosis is further divided into three types of lesions<sup>(3)</sup>:

- **type I** - rectovaginal septum lesions;
- **type II** - torus uterinus (retrocervical area of the uterus where the two uterosacral ligaments are unifying) and sacrouterine ligaments lesions;
- **type III** - hourglass-shaped lesions ("diabolo like").

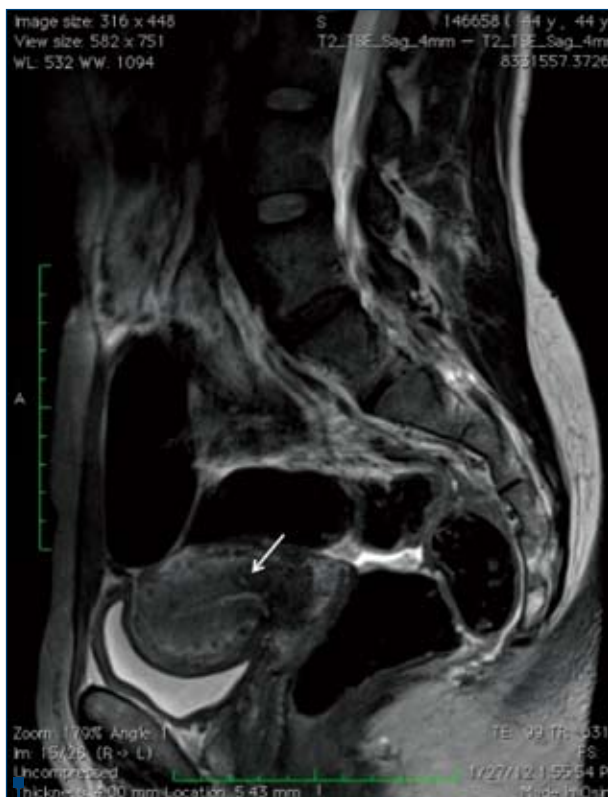
In a recent work, Kinkel<sup>(7)</sup> found an incidence of rectovaginal septum lesions of 14.5%, compared to 69.23% in the current study. The different population could explain this discordance as MRI continues to be a hardly accessible method in most of the Romanian centers, patients frequently being examined in advanced stages, when

endometriotic lesions are disseminated in the pelvis.

Endometriosis usually has a predilection for the torus uterinus, the reported frequency in the literature being of 69.2%<sup>(7)</sup> versus 46.16% in our work. This localization associated in most of the cases (8 out of 12 patients) an involvement of the sacrouterine ligaments (it rarely occurs separately as the torus uterinus represents in fact the insertion of the sacrouterine ligaments on the posterior part of the cervico-uterine junction) (Figure 5).

Sacrouterine ligaments thickening is frequently encountered in patients that already had pelvic surgery for a different pathology as it signifies a chronic inflammatory status. Their aspect should be judged in clinical context and additional morphological changes like a nodular aspect are to be identified in order to affirm an endometriotic lesion at this level (Figure 6).

Hourglass-shaped lesions (diabolo) occur when endometriotic implants extend from



**Figure 7.** Adenomyosis in a patient with endometriosis: thickening of the junctional zone with hyperintense spots similar to the normal endometrium (T2 weighted sequence)

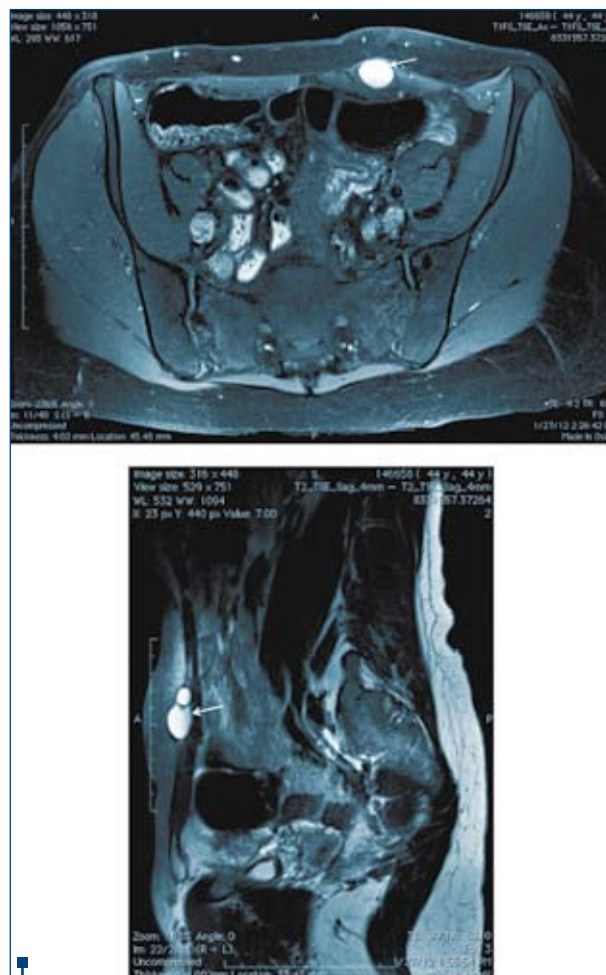
the torus uterinus to the anterior wall of the rectosigmoid colon, creating an aspect “diabolo-like”<sup>(3, 8)</sup>. Anatomically, these lesions are situated under the pouch of Douglas, could be voluminous and penetrate the rectal wall. This type of lesions is hardly to pass undiagnosed.

Two particular conditions are to be discussed separately: the association between adenomyosis and endometriosis of the abdominal wall.

Adenomyosis and endometriosis could be causally related as Leyendecker suggested in his work<sup>(9)</sup>. An abnormal function of the junctional zone (the innermost layer of myometrium) determines disturbed uterine contractions that could disseminate endometrial glands and allow the endometrium to penetrate the myometrium<sup>(10,11)</sup>. We considered a thickness of the junctional zone of more than 13 mm associated to the presence of hyperintense spots at this level highly specific for adenomyosis (Figure 7). The reported prevalence of adenomyosis in patients with endometriosis was of 34.6% on a group of 153 patients analyzed by Larsen<sup>(12)</sup>, of 79% in another group of 160 women with endometriosis studied by Kunz<sup>(13)</sup> and of 27% in the research performed by Bazot on 163 patients<sup>(11)</sup>. These discrepancies are

explained by the different criteria used, as Kunz and Larsen considered that a junctional zone maximum of >11 mm and of >12 mm respectively was sufficient for the diagnosis of adenomyosis. As no consensus actually exists concerning the MRI diagnosis criteria of adenomyosis, it is difficult to compare different studies.

In our study, we encountered a particular situation, an endometriotic implant of the left rectus abdominis in a patient that previously had laparoscopy for endometriosis. According to case reports as no extensive study actually exists, endometriosis of the abdominal wall could have different localizations: umbilical, the rectus abdominis muscle, laparoscopy trocar orifices or post-operative scars and could be the result of translocation of endometrial or decidual tissue during surgical procedures. This type of endometriosis is often mistaken for other abnormal conditions such as a suture granu-



**Figure 8.** Hemorrhagic endometriotic nodule in the left rectus abdominis muscle in the patient that previously had laparoscopy for endometriosis: T1 fat sat (a, left) and T2 (b, right) weighted sequences

loma, parietal hernia, or metastatic lesions (Figure 8)<sup>(14,15)</sup>.

Concerning the technical aspect, some of the authors<sup>(16)</sup> recommend vaginal opacification with 20 ml sterile ultrasound gel and of the rectum with 50 ml. We consider that this practice increases the examination time and brings supplementary discomfort to the patient with no practical benefice as the new IRM devices have a very good spatial resolution. Even if it is not mentioned in the literature, we suggest performing an evacuation enema the morning of the exam as chronic constipation and the presence of a fecaloma could pose problems in diagnosing small serosal lesions.

Caramella affirmed in 2008<sup>(17)</sup> that his team did not use antiperistaltic agents as this could slow the intestinal transit after the examination. In our study, we did not use Buscopan in one case and the T2 axial sequence had to be repeated as intestinal motility artifacts made the interpretation impossible.

Although it allows a better evaluation of inflammatory changes, we consider that a systematic injection of gadolinium-based contrast agents does not increase detection rate of endometriotic lesions. Post contrast examination could be useful in patients having chronic inflammatory changes of the

pelvic region as this might simulate peritoneal and ligamentous thickening associated with endometriosis.

The originality of the current study consists in reevaluating the diagnostic criteria for adenomyosis, describing the association of deep endometriosis with uterine adenomyosis and reconsidering the MRI protocol for research of endometriotic lesions.

## Conclusions

MRI imaging can accurately identify endometriotic lesions, no matter the topography.

In order to make a clear differential diagnosis with other pelvic lesions (like teratomas or cystic lesions) T1 and T2 both TSE and fat sat sequences are necessary.

For a precise anatomical localization it is mandatory to perform T2 sequences in all the three planes, most of the lesions (especially of the rectovaginal septum, torus uterinus, sacrouterine ligaments) being identifiable on the sagittal sequence. Intestinal and round ligaments lesions are easily seen on the axial sequence.

A correct and complete interpretation of the MRI examination facilitates an adapted surgical treatment, as transvaginal laparoscopy could prove impossible in case of Douglas filling. ■

## References

1. Hummelshoj L, Prentice A, Groothuis P. Update on endometriosis. *Women's Health* 2006; 2(1): 53-6.
2. Balleyguier C, Chapron C, Eiss D. Imagerie de l'endométriose. *EMC-Radiologie* 2004;1:36-49.
3. Del Frate C, Girometti R, Pittino M, et al. Deep retroperitoneal pelvic endometriosis: MR imaging appearance with laparoscopic correlation. *Radiographics* 2006;26:1705-1718.
4. Bazot M, Darai E, Hourani R, et al. Deep pelvic endometriosis: MR imaging for diagnosis and prediction of extension of disease. *Radiology* 2004; 232:379-389.
5. Chapron C, Fauconnier A, Vieira M, Barakat H, Dousset B, Pansini V, et al. Anatomical distribution of deeply infiltrating endometriosis: surgical implications and proposition for a classification. *Hum Reprod* 2003; 18(1):157-61.
6. Kataoka ML, Togashi K, Yamaoka T, et al. Posterior cul-de-sac obliteration associated with endometriosis: MR imaging evaluation. *Radiology* 2005;234:815-823.
7. Kinkel K, Frei KA, Balleyguier C et al. Diagnosis of endometriosis with imaging: a review. *Eur Radiol* 2006;16:285-298.
8. Marcal L, Nothaft Maria Angela, Coelho F, Choi H. Deep pelvic endometriosis: MR imaging. *Abdom Imaging* 2010; 35: 708-715.
9. Leyendecker G, Wildt L, Mall G. The pathophysiology of endometriosis and adenomyosis: tissue injury and repair. *Arch Gynecol Obstet*. 2009 Oct;280(4):529-38.
10. Larsen SB, Lundorf E, Forman A, Dueholm M. Adenomyosis and junctional zone changes in patients with endometriosis. *Eur J Obstet Gynecol Reprod Biol* 2011; 157: 206-211.
11. Bazot M, Fiori O, Darai E. Adenomyosis in endometriosis - prevalence and impact on fertility. Evidence from magnetic resonance imaging. *Hum Reprod* 2006; 21: 1101-2.
12. Larsen SB, Lundorf E, Forman A, Dueholm M. Adenomyosis and junctional zone changes in patients with endometriosis. *Eur J Obstet Gynecol Reprod Biol* 2011; 157: 206-211.
13. Kunz G, Beil D, Huppert P, Noe M, Kissler S, Leyendecker G. Adenomyosis in endometriosis - prevalence and impact on fertility. Evidence from magnetic resonance imaging. *Hum Reprod* 2005; 20: 2309-16.
14. Durand X, Daligand H, Aubert P, Baranger B. Endométriose de la paroi abdominale. *Journal de Chirurgie Viscérale* 2010; 147: 354-359.
15. Abrao MS, Goncalves MO, Dias JA Jr, et al. Comparison between clinical examination, transvaginal sonography and magnetic resonance imaging for the diagnosis of deep endometriosis. *Hum Reprod* 2007; 22: 3092-3097.
16. Takeuchi H, Kuwatsuru R, Kitade M et al. A novel technique using MRI jelly for evaluation of rectovaginal endometriosis. *Fertil Steril* 2005; 83: 442-447.
17. Caramella T, Novellas S, Fournol M et al. Endométriose pelvienne profonde en IRM. *J Radiol* 2008; 89: 473-479.