

Pentalogy of Cantrell associated with unilateral anophthalmia

Case report and literature review

Mihaela Grigore, MD, PhD^{a,*}, Cristina Furnica, MD, PhD^b, Irina Esanu, MD, PhD^c, Dumitru Gafitanu, MD, PhD^a

Abstract

Rationale: Pentalogy of Cantrell, a very rare congenital condition, has an estimated incidence of 5.5 per 1 million live births. It includes five defects: a midline supraumbilical wall defect, a diaphragmatic defect, a cleft distal sternum, a defect in the diaphragmatic pericardium, and an intracardiac defect. Very few cases of this condition have been reported in the literature, most of them diagnosed in the second or third trimester of pregnancy.

Patient concerns: We present a case of pentalogy of Cantrell associated with cranioschisis and unilateral anophthalmia diagnosed at 14 weeks of amenorrhea.

Diagnoses: The combination of abdominal and vaginal sonography established the diagnosis of 14 weeks of amenorrhea with a plurimaleformative syndrome including: ectopia cordis, large suprablilical anterior abdominal wall defect, omphalocele, anomaly of the shape of the skull, and anomalies of the brain.

Interventions: After counseling the parents, the pregnancy was interrupted, as requested by the family.

Outcomes: Pathological examination of the fetus after the therapeutic abortion confirmed the diagnosis.

Lessons: Because of the poor prognosis of Cantrell's pentalogy, early antenatal sonographic detection is important and allows for elective abortion before viability.

Abbreviations: 2D = two-dimensional, 3D = three-dimensional.

Keywords: Cantrell penology, early prenatal diagnosis, three-dimensional ultrasound, unilateral anophthalmia

1. Introduction

Pentalogy of Cantrell is a very rare congenital condition that involves 5 abnormalities: a midline supraumbilical wall defect, a diaphragmatic defect, a cleft distal sternum, a defect in the diaphragmatic pericardium, and an intracardiac defect.^[1] Very few cases with all 5 anomalies have been reported in the literature. Most reported cases have been incomplete forms of Cantrell's pentalogy. We present a case of pentalogy of Cantrell associated with cranioschisis and unilateral anophthalmia diagnosed at 14 weeks of amenorrhea. The parents provided informed consent to the publication of this case. There were no other ethical requirements.

Editor: Manal Elshmaa.

The authors have no conflicts of interest to disclose.

^a Department of Obstetrics and Gynecology, ^b Department of Anatomy,

^c Department of Internal Medicine, University of Medicine and Pharmacy, "Grigore T. Popa" Iasi, Romania.

* Correspondence: Mihaela Grigore, University of Medicine and Pharmacy "Grigore T. Popa" Iasi, Department of Obstetrics and Gynecology, Str. Universitatii 16, 700115, Iasi, Romania (e-mail: mihaela.grigore@edr.ro).

Copyright © 2018 the Author(s). Published by Wolters Kluwer Health, Inc.

This is an open access article distributed under the Creative Commons Attribution-NoDerivatives License 4.0, which allows for redistribution, commercial and non-commercial, as long as it is passed along unchanged and in whole, with credit to the author.

Medicine (2018) 97:31(e11511)

Received: 21 June 2017 / Accepted: 20 June 2018

<http://dx.doi.org/10.1097/MD.00000000000011511>

2. Case report

A 42-year-old, gravida 3, para 2, came for medical examination because of amenorrhea. The woman had a child with a cardiac malformation—pulmonary artery stenosis. Pelvic examination established the diagnosis of pregnancy, and an ultrasound was performed using both two-dimensional (2D) and three-dimensional (3D) abdominal and endovaginal probes (Voluson 730 Pro, abdominal probe RAB, endovaginal probe RIC, General Healthcare). The combination of abdominal and vaginal sonography established the diagnosis of 14 weeks of amenorrhea with a plurimaleformative syndrome. The malformations observed during the examination were: ectopia cordis, large suprablilical anterior abdominal wall defect, omphalocele, anomaly of the shape of the skull, and anomalies of the brain. Doppler examination and 3D ultrasound were particularly useful for observing the anomalies (Figs. 1 and 2). The diagnosis of Cantrell pentalogy was formulated and after counseling the parents, the pregnancy was interrupted on the request of the family. The syndrome and the associated malformations were presented to the parents and the prognosis for each malformation was discussed with them. After counseling the parents, the pregnancy was interrupted, as requested by the family. Although a karyotype examination was discussed, the family refused the examination.

Pathological examination of the fetus after the therapeutic abortion confirmed the diagnosis and the malformations described by ultrasonographic examination (Fig. 3). The fetus showed asymmetric head and the pouch of the amniotic membranes near the skull and unilateral anophthalmia (Fig. 3). Unfortunately, because of the size of the heart, it was

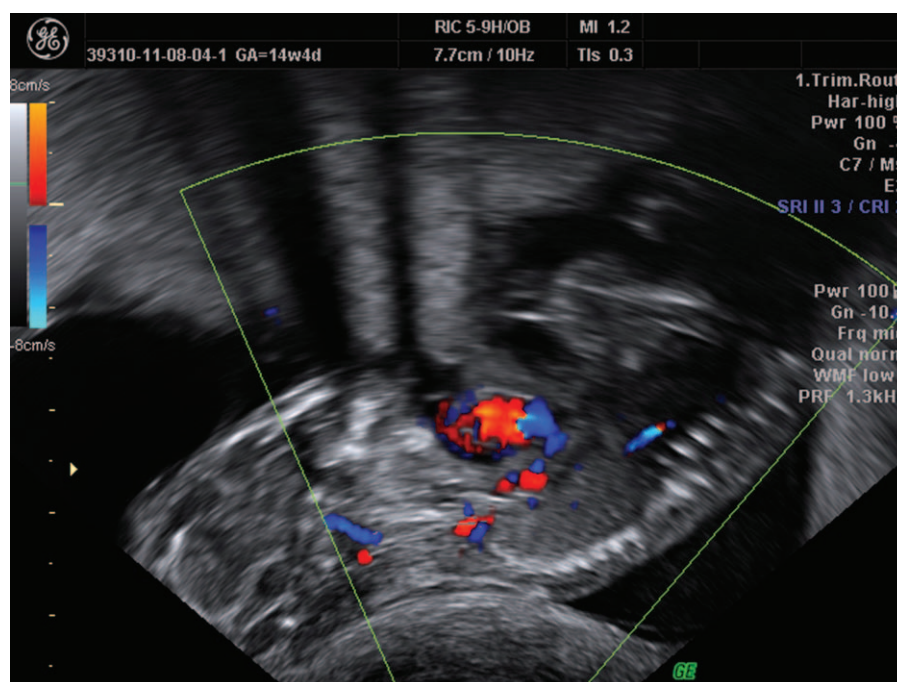


Figure 1. Pregnancy 14 weeks of amenorrhea. Color Doppler ultrasound is helpful for the diagnosis of ectopia cordis. The arrow indicates the ectopic heart and the head.

not possible to establish if there was an intracardiac malformation present.

3. Discussion

Pentalogy of Cantrell was first described in 1958 by Cantrell et al.^[1] This rare congenital defect has an estimated incidence 5.5 per 1 million live births.^[2] It involves malformations of the abdominal wall, sternum, diaphragmatic pericardium, and heart. The condition varies in its severity, from incomplete to severe expression, with or without involvement of other organ systems.

The pathogenesis is not fully elucidated. One widely accepted theory, suggested by Cantrell, is a developmental failure of a segment of the lateral mesoderm around gestational age 14 to 18 days. As a consequence, the transverse septum of the diaphragm does not develop, and the paired mesodermal folds of the upper abdomen do not migrate ventromedially.^[1] The variety of the associated anomalies sustain the hypothesis that multiple factors

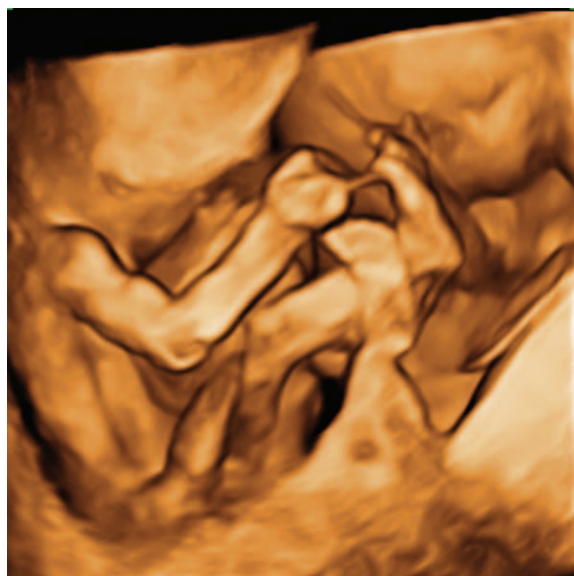

Figure 2. Pregnancy 14 weeks of amenorrhea. Three-dimensional ultrasound-A large defect of the anterior abdominal wall is visible.

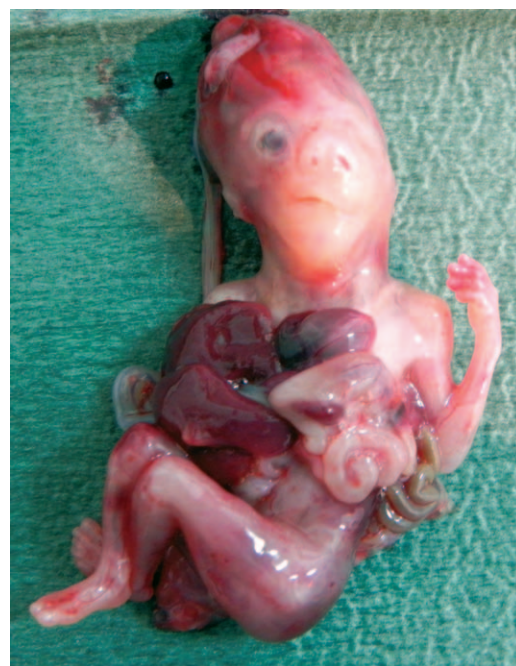

Figure 3. Macroscopic image of the fetus. Large abdominal wall defect with evisceration of the liver, spleen, and a major part of the gastrointestinal tract. Anophthalmia is visible.

are responsible for Cantrell pentalogy, including mechanical teratogens, major gene mutation, chromosomal abnormalities, such as trisomy 13 and 18, and disrupted vessels defects.^[3] Two cases described in the literature were associated with trisomy 18. In both cases, other anomalies were present, including bilateral clubfeet, spina bifida, hydrocephalus, abnormal ears, horseshoe kidneys, hypogenesis of the corpus callosum, and vermian-cerebellar hypoplasia (Dandy–Walker variant).^[4,5]

In the Cantrell pentalogy, the sternum defects may vary from a simple notch of the manubrium to absence of the entire sternum. Abdominal wall defects include omphalocele, which is the most common, diastasis recti, epigastric hernia, umbilical hernia, or a combination of defects. Ventral defects of the diaphragm and absent pericardium are the most common diaphragmatic and pericardial defects, respectively.^[6] The spectrum of these morphological abnormalities includes the Cantrell pentalogy in the category of the superior celosomies.^[7]

Our case was characterized by complete absence of the pericardium and diaphragm. In Cantrell pentalogy, ectopia cordis is characterized by complete or partial displacement of the heart outside the body. There are several types of ectopia cordis described: cervical, cervicothoracic, thoracic, and thoracoabdominal. In our case, the heart was outside the body in the thoracic area. The most common intracardiac defects, as described by Cantrell, are ventricular defects and atrial defects, followed by tetralogy of Fallot and left ventricle diverticulum.^[1] Recently, cases with hypoplastic left syndrome and single ventricle malformation have been described.^[8,9] Figueroa studied more than 21 cases of Cantrell pentalogy and found that the most common cardiac anomalies were doubled outlet right ventricle in 5 patients and atrial septal defect in 4 patients.^[10] Combined with the congenital defects described by Cantrell, many cases have other associated anomalies, many of which worsen the prognosis. Additional anomalies include: craniofacial defects and central nervous system anomalies (cleft lip and/or palate, encephalocele, hydrocephalus, and craniorachischisis), limb defects (clubfoot, absence of tibia or radius, hypodactily) abdominal organ defects (gallbladder agenesis and polysplenia), renal anomalies (unilateral kidney evisceration).^[11–16]

In the case presented, the fetus presented with cranioschisis and unilateral anophthalmia. Along with the asymmetric head a pouch of the amniotic membranes near the skull was present.

Because most of the cases described in the literature are not complete forms of Cantrell pentalogy, in 1972, Toyama suggested a classification of this condition: complete, probable, and incomplete. A complete diagnosis requires the presence of all 5 defects described by Cantrell. The probable classification is given when 4 defects are present, and when various combinations of defects are present including a sternal abnormality, and an incomplete classification is given.^[17]

The pentalogy of Cantrell can be diagnosed with ultrasound, which reveals the association between an omphalocele and an ectopic heart. Color Doppler examination, which visualizes the heart outside the thorax, is very useful especially for making the differential diagnosis with other plurimalformative syndromes like limb body wall complex body syndrome.^[18] Pleural and pericardial effusion are common, and some authors consider them to be indirect markers for the pentalogy.^[19] Additionally, 3D ultrasound can be useful to confirm the diagnosis providing a complete prenatal view of the anomaly. Using 3D ultrasound in obstetrics has many advantages, including as enhanced diagnosis of fetal anomalies, accurate volume measurement of organs with irregular shape, and offering the possibility of storing the volumes.^[20]

It is important to inform the patients during prenatal counseling about the possibility that some sonographic aspects could improve during the course of pregnancy.^[21] The diagnosis in the first trimester of pregnancy should be made after 12 weeks of gestation because physiologic umbilical hernia is a normal event in fetal development until this time.^[22] Most cases have been reported in the literature in the second trimester, although one case was reported during the first trimester of pregnancy.^[23] In our case, the diagnosis was established at 14 weeks of amenorrhea with 2D color Doppler ultrasound and 3D ultrasound.

The prognosis varies according to the severity of the anomalies. Few fetuses survive, and even fewer survive with good quality of life. The prognosis is poorer in the complete form of pentalogy and in cases with other associated anomalies.^[15] When the diagnosis of pentalogy of Cantrell is established prenatally, a multidisciplinary approach is essential. Early postnatal fetal cardiac and systemic evaluation is mandatory to determine the prognosis and plan the management. Correction of midline defects, diaphragmatic defects, and associated anomalies is the main treatment. Early diagnosis in the first trimester is possible using ultrasound and is desirable because it offers the option of arresting the pregnancy progress earlier where the impact, psychological and gestational is reduced. In any case the request of the family, showing their will, is mandatory for the procedure.

4. Conclusion

Pentalogy of Cantrell is a rare anomaly, and antenatal diagnosis is very important. Both 2D and 3D are very valuable tools for early diagnosis. Because of the poor prognosis of Cantrell's pentalogy, early antenatal sonographic detection is important and allows for elective abortion before viability. The family request for the procedure is mandatory after a proper counseling realized in a multidisciplinary fetal center.

Acknowledgment

The scientific research was financed by the “Grigore T. Popa” University of Medicine and Pharmacy Iasi, Romania, under the contract no. 29031/28.12.2016.

Author contributions

Conceptualization: Mihaela Grigore, Cristina Furnica, Irina Esanu, Dumitru Gafitanu.

Writing – original draft: Mihaela Grigore, Cristina Furnica, Irina Esanu, Dumitru Gafitanu.

Writing – review & editing: Mihaela Grigore.

References

- [1] Cantrell JR, Haller JA, Ravitch MM. A syndrome of congenital defects involving the abdominal wall, sternum, diaphragm, pericardium, and heart. *Surg Gynecol* 1958;107:602–14.
- [2] Carmi R, Boughman JA. Pentalogy of Cantrell and associated midline anomalies: a possible ventral midline developmental field. *Am J Med Genet* 1992;42:90–5.
- [3] Chen CP. Syndromes and disorders associated with omphalocele(II): OEIS complex and pentalogy of Cantrell. *Taiwan J Obstet Gynecol* 2007;46:103–10.
- [4] Fox JE, Gloster ES, Mirchandani R. Trisomy 18 with Cantrell pentalogy in a stillborn infant. *Am J Med Genet* 1988;31:391–4.
- [5] Hou YJ, Chen FL, Ng YY, et al. Trisomy 18 syndrome with incomplete Cantrell. *Pediatr Neonatol* 2008;49:84–7.

- [6] Bhat RY, Rao A, Muthuram . Cantrell syndrome in one set of monozygic twins. *Singapore Med J* 2006;47:1087–8.
- [7] Morales JM, Patel SG, Duff JA, et al. Ectopia cordis and other midline defects. *Ann Thorac Surg* 2000;70:111–4.
- [8] Grethel EJ, Hornberger LK, Farmanr DL. Prenatal and postnatal management of a patient with pentalogy of Cantrell and left ventricular aneurysm. A case report and literature review. *Fetal Diag Ther* 2007;22:269–73.
- [9] Marino AL, Levy RJ, Berger JT, et al. Pentalogy of Cantrell with a single-ventricle cardiac defect: collaborative management of a complex disease. *Pediatr Cardiol* 2011;32:498–502.
- [10] Figuera JR, Cruz EF, Garcia LD, et al. Cardiac malformations in patients with pentalogy of Cantrell and ectopia cordis. *Rev Esp Cardiol* 2011;64:615–8.
- [11] Polat I, Gul A, Cebeci A, et al. Prenatal diagnosis of pentalogy Cantrell in three cases, two with craniorachishisis. *J Clin Ultrasound* 2007;33: 308–11.
- [12] Atis A, Demirayak G, Saglam B, et al. Craniorachishisis with a variant of pentalogy of Cantrell with lung extrophy. *Fetal Pediatr Pathol* 2011;30:431–6.
- [13] Uygur D, Kis S, Sener E, et al. An infant with pentalogy of Cantrell and limb defects diagnosed prenatally. *Clin Dysmorphol* 2004;13:57–8.
- [14] van Hoorn JH, Moonen RM, Huysentruyt JR, et al. Pentalogy of Cantrell: two patients and a review to determine prognostic factors for optimal approach. *Eur J Pediatr* 2008;167:29–35.
- [15] Bittmann S, Ulus H, Springer A. Combined pentalogy of Cantrell with tetralogy of Fallot, gallbladder agenesis, and polysplenia: a case report. *J Pediatr Surg* 2004;39:107–9.
- [16] Madžarac V, Matijević R, Škrtić A, et al. Pentalogy of Cantrell with unilateral kidney evisceration: a case report and review of the literature. *Fetal Pediatr Pathol* 2016;35:43–9.
- [17] Toyama WM. Combined congenital defects of the anterior wall, sternum, diaphragm, pericardium and heart: a case report and review of the syndrome. *Pediatrics* 1972;50:778–92.
- [18] Grigore M. Early diagnosis of limb body wall complex: a case report. *Clin Exp Obstet Gynecol* 2014;41:354–6.
- [19] Siles C, Boyd PA, Maninning N. Omphalocele and pericardial effusion: possible sonographic markers for the pentalogy of Cantrell or its variants. *Obstet Gynecol* 1996;87:840–2.
- [20] Grigore M, Iliev G. Diagnosis of sacrococcygeal teratoma using two and three-dimensional ultrasonography: two cases reported and a literature review. *Med Ultrason* 2014;16:274–7.
- [21] Zidere V, Allan LD. Changing findings in pentalogy of Cantrell in fetal life. *Ultrasound Obstet Gynecol* 2008;32:835–7.
- [22] Grigore M, Iliev G, Gafitanu , et al. The fetal abdominal wall defects using 2D and 3D ultrasound. Pictorial essay. *Med Ultrason* 2012; 14:341–7.
- [23] Liang RI, Huang SE, Chang FM. Prenatal diagnosis of ectopia cordis at 10 weeks of gestation using two-dimensional and three-dimensional ultrasonography. *Ultrasound Obstet Gynecol* 1997;10:137–9.