

THE ROLE OF VITAL STAINING IN THE EARLY DIAGNOSIS OF ORAL CANCER

Mihaela Monica Scutariu¹, Amelia Elena Surdu¹, Gabriela Ifteni^{2,*},
Doriana Agop-Forna³, Oana-Elena Ciurcanu³

“Grigore T. Popa” University of Medicine and Pharmacy Iasi
Faculty of Dental Medicine

1. Department of Implantology, Removable Prosthesis, Dental prosthesis technology

2. Department of Odontology- Periodontology, Fixed Prosthesis, Gnatology, Aesthetics

3. Department of Oral and Maxillofacial Surgery

*Corresponding author. Email: gabriela.ifteni@umfiasi.ro

THE ROLE OF VITAL STAINING IN THE EARLY DIAGNOSIS OF ORAL CANCER (Abstract): The early diagnosis of oral cancer is a priority for the entire dental system. Dental specialists, who most often are the first to examine the patients with oral tumors, are responsible for their patients' future and it is not only expected but also desired that they fulfil their role with a lot of commitment, competence and professionalism. On the other hand, it is also essential to continue developing, assessing and improving the main means of primary and secondary prophylaxis and to identify and diagnose oral cancer at an early stage. Since nowadays the fight against oral and maxillofacial cancer can only be won if it is diagnosed at an incipient stage and it is followed by a radical multimodal and effective treatment, the population must be more sensitive to the oncogenic risk factors of the oral cavity and to the early manifestations of cancer. **Keywords:** VITAL STAINING, EARLY DIAGNOSIS, ORAL CANCER.

The early diagnosis refers to the diagnose made as soon as possible after a clinical manifestation when the lesion can be seen and/or palpated or when it can be noticed using laboratory tests, before reaching the maximum T₁ limit, with N₀ and M₀ (1). The toluidine blue vital staining (RICHART) relies on its affinity for cell nuclei and for those nuclei undergoing mitosis (2, 3). Colour intensity is directly proportional with nuclei density, size and their division phase, that is, with their degree of malignity. The method can identify lesions of 1 mm³ this way reducing the lower limit of detecting tumors up to the “infraclinical” stage, at an age of the tumor

of almost 6 months (4).

In dentistry, toluidine blue vital staining is to be considered in the diagnostic process, completing in a useful and necessary manner the clinical examination. It requires further investigations of the suspected lesion (5, 6).

To ease the detection and the identification of risk lesions, additional methods have been introduced: toluidine blue vital staining is the most studied method that can support the early detection of premalignant lesions and squamous cell carcinoma (7, 8, 9). Toluidine blue is a cationic metachromatic dye that may selectively bind to free anionic groups such as sulfate, phosphate

and carboxylate radicals of large molecules (10). *In vivo*, toluidine blue stains nucleic and deoxyribonucleic acids which can be retained in intracellular spaces of dysplastic epithelium. Dysplastic and malignant tissues retain toluidine blue because of the loss of tumor suppressor genes that predict the progression of precancerous lesions towards carcinoma or represent the squamous cell carcinoma themselves during the diagnosis (11, 12).

MATERIAL AND METHODS

Toluidine blue is recommended for the following reasons:

- It determines premalignant oral lesions at risk of turning into squamous cell carcinoma;
- It identifies mucosal lesions with high risk molecular models with a significant potential of turning into cancer (for both high and low risk dysplasia) (13, 14);
- It evaluates the extent and the margins of carcinoma and premalignant lesions;
- It guides the biopsy site selection and accelerates the decision to biopsy (15).

The toluidine blue vital staining or the Richart test was used on 268 patients divided into three groups of physically examined patients (tab. I):

TABLE I
Groups of patients

	<i>Patients</i>
Group I	25
Group II	156
Group III	87
<i>Total</i>	268

From the total 268 clinical lesions, 53 had a hyperplastic vegetant appearance

while 192 had an ulcerative appearance; 23 patients presented white lesions. The diagnosis made after physical examination is presented below (tab. II):

TABLE II
Diagnosis after clinical exam

Diagnosis	Patients
Traumatic ulceration on the lower lip, tongue, cheek	103
Chronic cheilitis	24
Herpetic ulceration	15
Post-burn ulceration (hard palate, tongue)	9
Aphthous stomatitis	9
Ulcerous stomatitis	23
Leukoplakia	21
Lichen planus	11
Hyperplastic benign tumors (lip, tongue, vestibule, gingivoalveolar)	53
<i>Total</i>	268

The Richart test was used for:

- ✧ completing the physical exam of benign lesions that still presented a certain degree of malignant suspicion
- ✧ identifying small, ulcerative relapse signs
- ✧ the stomatoscopic analysis of certain lesions.

The following work technique was used: we cleaned the lesion with a piece of gauze soaked in 1% acetic acid; after cleaning the area, using the water spray of the dental unit (dentior), we have isolated the lesion and dried it with warm air. The lesion was colored using a sponge saturated with toluidine blue aqueous solution. The dye was kept for 2-3 minutes after which the lesion was washed once again using the spray and then dried uniformly and without applying any pressure with a solution of 1% acetic acid.

Here are some of the cases where the Richart method was used.

1. I. I., Iasi town, came in for consultation for an ulcerative lesion, painful manifestation on the left cheek, and swelling of the surrounding mucosa, present for a few days (fig. 1). After cleaning the dye (fig. 2) we noticed a second ulcerative lesion of 2 cm in diameter which stained dark blue

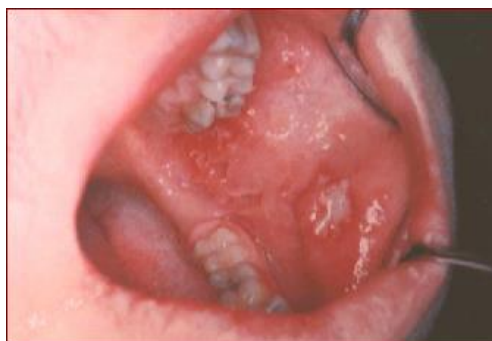

Fig. 1. The ulcerative lesion

(positive reaction) (fig. 3). A 7 days treatment including rinses with 5% tetracycline solution led to the healing of the ulceration. The diagnosis was ulcerative stomatitis. Although the dye was retained in the central area leading to a misinterpretation of malignant lesion, in fact it was an inflammation of the oral mucosa. In this case, the toluidine blue response was false positive.

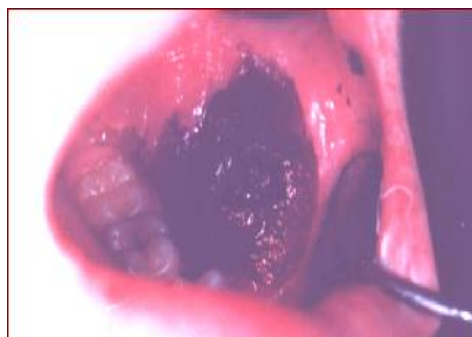

Fig. 2. Toluidine blue aqueous solution

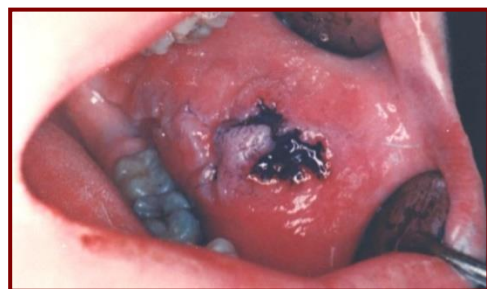

Fig. 3. Ulcerative lesion of 2 cm - stained dark blue (positive reaction)

2. S. N., Iasi county, pensioner, smoker for over 50 years and alcohol user presented with an ulcerative lesion of less than 1 cm in diameter, round, with slightly pronounced edges, without hardened base, unpainful, situated in the medial 1/3 segment of the lower lip, with the surrounding mucosa of normal appearance (fig. 3). The lesion had been present for almost 3 years. We proceeded using toluidine blue to dye the ulceration, washed the excess with

acetic acid, and it resulted a dark blue stain (positive reaction) (fig. 4). Exfoliating cytology made the diagnosis of inflammatory smear with hematins, superficial and intermediary epithelial cells of normal appearance. Treatment: removal of the ulceration using a type "V" resection on the lower lip and suture of the margins.

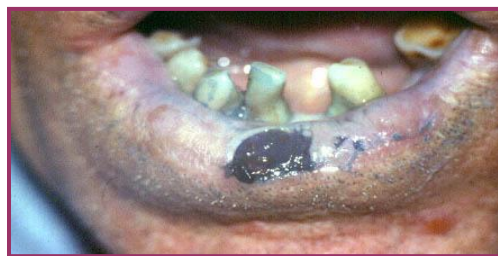

Fig. 4. Dark blue stain (positive reaction)

The histopathological examination made the diagnosis of moderately differentiated squamous cell carcinoma with intense superficial ulceration. In this case,

the intense positive staining and the carcinoma diagnosis correlated well.

3. C. V., from Vaslui County, retired, smoker, was examined for an oval superficial ulceration of less than 1 cm in size, located on the red part of the lower lip, the surrounding mucosa having a whitish leukoplastic appearance. The lesion was noticed a few months earlier, increased in size gradually, and was slightly bleeding (fig. 5). Physical examination was completed with the toluidine blue vital staining which, after the removal of the extra amount of substance with acetic acid, remained fixed in the ulceration area. The toluidine blue vital staining was considered positive (fig. 6).

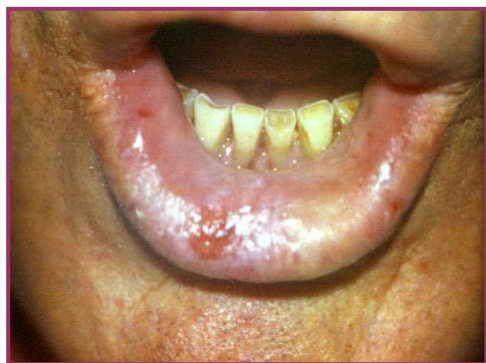

Fig. 5. Oval superficial ulceration

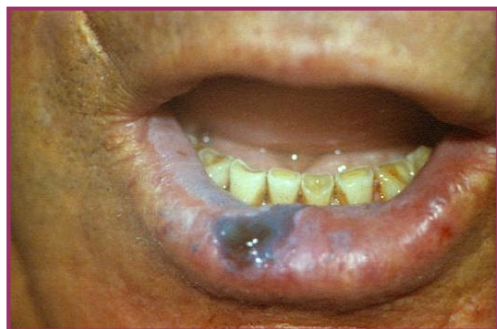

Fig. 6. Blue stain (positive reaction)

Treatment: excision of the ulceration from the lower lip until healthy tissue was reached. The histopathological examination

led to the diagnosis of chronic ulcerative cheilitis. Although the lesion retained the dye, the reaction was *false positive* as, in the end, it turned out to be a chronic inflammation and not a malignant ulceration.

4. H. M., Iasi town, retired, non-smoker, presented with a leukoplasic area from the left edge to the ventral side of the tongue and for an ulceration of less than 1 cm in diameter on the dorsal surface of the tongue, evaluated as superficial and painful. We used the Richart test. After using acetic acid to remove the excessive dye the remaining area appeared atypical: the ulceration did not retain the dye (negative reaction) and the tip of the tongue and certain areas on the edge of the tongue as well as the leukoplasic area stained light blue (positive reaction). When analyzing the reaction 24 hours later we found that the entire area that reacted to toluidine blue regained its normal appearance (as before staining). Treatment: excision of the ulceration along with the leukoplasic area on the edge of the tongue. The histopathological examination led to the following diagnose: leucoplakia and dysplastic lesions and intraepithelial invasive carcinoma. In this case, the *atypical* Richart test was the reason why we decided to biopsy.

5. I. D., from Bacau County, smoker for 10 years, type II diabetes and third-degree obesity presented with a 1.5 cm-long ulceration situated on the ventral side of the tongue in the left half, near the tip of the tongue. The patient noticed the appearance of lesion almost a year before, but it became painful and increased in size recently. Physical examination revealed that the ulceration was highly connected to 3.5 (tooth in lingual position). The ulceration was stained with toluidine blue and then washed with 1% acetic acid solution. The ulceration did not retain the stain (negative reaction) and the surrounding mucosa

stained light blue. Exfoliative cytology demonstrated it was an inflammatory smear. Indeed it was a traumatic ulceration caused by the presence of tooth 3.5 in a vicious position and the ulceration healed in 10 days after tooth extraction.

6. C.I., Suceava County, retired, 40-year smoker and alcohol consumer on daily basis (200 g.), noticed for 3 months before the presentation the appearance of a small ulceration on the right side of the tongue in relation to 4.4 (with deep chronic marginal periodontitis), 4.3, 4.2, 4.1 (residual tooth roots). The lesion gradually increased in size developing a crater-like appearance. The Richart test was used. After removing the dye with acetic acid, the dorsal part of the tongue and the right edge along with the ulceration were stained light blue (very light) stained – the reaction being interpreted as negative. The cytological exam indicated tumor cells in the oral smear with free atypical cells and in placard. Treatment: surgical removal of the ulcer area. The histopathological examination made the diagnosis of undifferentiated squamous cell carcinoma developed deep in the cho-

tion infiltrating strictly the muscle tissue. In this case, although the Richart test was negative, the ulceration was, in fact, a malignant lesion.

7. A. A., Iasi town, retired, smoker for 7 years, presented with a ulceration of 0.5 cm in diameter, irregular margins, the surrounding mucosa being slightly congestive, painful on palpation, situated on the edentulous alveolar crest corresponding to 4.8 (extracted 2 months earlier). During the examination the dental instrument was introduced 5 cm deep into the tooth socket. The dye was introduced and after washing it with acetic acid the ulceration appeared to have a normal (negative appearance). The cytological examination indicated an inflammatory smear. In this case, the negative result of the Richart test corresponded to the cytodiagnosis (inflammatory smear) and clinical course (the lesion healed 2 weeks later).

RESULTS

Considering the analyzed clinical lesions, the results for toluidine blue vital staining were as follows: (tables III-XI):

TABLE III
Clinical diagnosis versus true diagnosis: Ulcerations

Clinical diagnosis			True diagnosis		
Of 103 ULCERATIONS			87 malignant lesions and 16 inflammatory lesions		
Test	Stain	No. of patients	Lesion	No. of cases	Reaction
(+)	Dark blue	76	Malignant lesions	72	(+)
			Inflammatory lesions	4	False (+)
	Light blue	13	Malignant lesions	4	(+)
			Inflammatory lesions	9	False (-)
(-)	Uncoloured tissue	8	All cases were malignant lesions but did not retain the dye	8	False (-)
Uncertain	Atypical coloration	6	Malignant lesions	3	Atypical
			Mucosal inflammations	3	

The role of vital staining in the early diagnosis of oral cancer

TABLE IV
Clinical diagnosis versus true diagnosis: Cheilitis

<i>Clinical diagnosis</i>			<i>True diagnosis</i>
Of 24 CHEILITIS CASES			21 chronic inflammations and 3 cases that degenerated into carcinoma <i>"in situ"</i>
Test	Stain	No. of patients	
(+)	Blue	3	Carcinoma <i>"in situ"</i>
(-)	Uncoloured tissue	16	Cheilitis
Uncertain	Atypical coloration	5	Cheilitis

TABLE V
Clinical diagnosis versus true diagnosis: Leukoplakia

<i>Clinical diagnosis</i>			<i>True diagnosis</i>
Of 21 LEUKOPLAKIA CASES			12 leukoplakia and 9 cases that degenerated into carcinoma <i>"in situ"</i>
Test	Stain	No. of patients	
(+)	Dark blue	9	Carcinoma <i>"in situ"</i>
	Light blue	3	Leukoplakia – false reaction (+)
(-)	Uncoloured tissue	9	Leukoplakia

TABLE VI
Clinical diagnosis versus true diagnosis: Lichen Planus

<i>Clinical diagnosis</i>			<i>True diagnosis</i>
Of 11 LICHEN PLANUS CASES			
Test	Stain	No. of patients	
(+)	Light blue	5	Lichen planus – false reaction (+)
(-)	Uncolored tissue	6	Lichen planus

TABLE VII
Clinical diagnosis versus true diagnosis: Herpetic ulcerations

<i>Clinical diagnosis</i>			<i>True diagnosis</i>
Of 15 herpetic ulcerations			
Test	Stain	No. of patients	
(+)	Dark blue	5	Ulcerations – false reaction (+)
(-)	Uncolored tissue	10	Ulcerations

TABLE VIII
Clinical diagnosis versus true diagnosis: Post-burn Ulcerations

<i>Clinical diagnosis</i>			<i>True diagnosis</i>
<i>Of 9 post-burn ulcerations (hot food, cigars etc.)</i>			
Test	Stain	No. of patients	
(-)	Uncoloured tissue	9	Ulcerations

TABLE IX
Clinical diagnosis versus true diagnosis: Aphthous stomatitis

<i>Clinical diagnosis</i>			<i>True diagnosis</i>
<i>Of 9 APHTHOUS STOMATITIS</i>			
Test	Stain	No. of patients	
(+)	Light blue	6	Aphthae (inflammation) – false reaction (+)
(-)	Uncolored tissue	3	Aphthae (inflammation)

TABLE X
Clinical diagnosis versus true diagnosis Ulcerative stomatitis

<i>Clinical diagnosis</i>			<i>True diagnosis</i>
<i>Of 23 ULCERATIVE STOMATITIS</i>			
Test	Stain	No. of patients	
(+)	Light blue	9	Inflammatory lesions – false reaction (+)
(-)	Uncoloured tissue	10	Inflammatory lesions
Uncertain	Atypical coloration	4	Inflammatory lesions

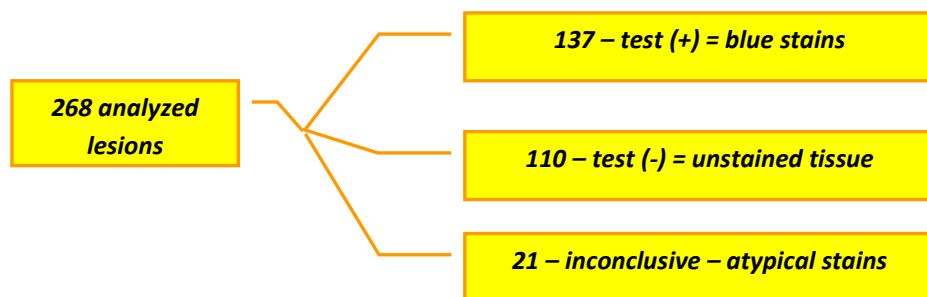
TABLE XI
Clinical diagnosis versus true diagnosis: Hyperplastic tumors

<i>Clinical diagnosis</i>			<i>True diagnosis</i>
<i>Of 53 HYPERPLASTIC TUMOURS</i>			<i>37 benign and 16 malignant</i>
Test	Stain	No. of patients	
(+)	Dark blue	6	Carcinoma “ <i>in situ</i> ”
	Light blue	2	Leukoplakia – false reaction (+)
(-)	Uncolored tissue	39	Benign lesions
			Malignant lesions – false reaction (-)

DISCUSSION

In conclusion, we can say that for the

268 analyzed lesions, the test results were:



From the total number of stains, some of them were *false*, as follows (tab. XII):

TABLE XII
Evaluation of the “blue stain” reaction

No of cases	Stain	No. of cases	Evaluation	%
137	stain (+) (for malignant and benign lesions)	96	Properly evaluated cases (+)	70%
		41	False cases (+)	21%
110	stain (-) (for inflammatory lesions, benign hyperplastic and malignant lesions)	94	Properly evaluated cases (-)	85%
		16	False cases (-)	12%
21	Atypical stain	3	Malignant lesions	
		18	Inflammatory lesions	

CONCLUSIONS

The dentist must diagnose and deal with precancerous lesions, and refer the patient, in useful time, to a specialized department of maxillofacial surgery (16, 17, 18, 19).

Toluidine blue staining must be considered a complementary method, useful to provide the dentist with an orientated diagnosis of pathogenic areas, that completes the physical examination.

If the false positive results do not provide the method a safety prerogative, we must then recognize its diagnostic role in locating abnormal areas on diffuse surfaces.

The simplicity of the method, the possibility of being used by any doctor, provides

added value, positioning it among the techniques that should become usual in any dental office.

The main indirect form the dentist has to fight against cancer is dominated by prophylactic principles and consists in the competent practice of dental medicine.

The prophylactic principle must guide any procedure, dental or periodontal, prosthetic or surgical, for the removal of mechanical, chemical and thermal irritants from the oral cavity (20, 21).

All the above mentioned elements combined with oral septicity, on a carcinogenic background, turn into possible favoring factors for the development of oral cancer.

REFERENCES

1. Aizawaa H., Yamadaa S-H., Xiaob T., Shimanea T., Hayashia K., Qia F., Tanakaa H., Kuritaa H. Difference in glycogen metabolism (glycogen synthesis and glycolysis) between normal and dysplastic/malignant oral epithelium, *Archives of Oral Biology* 2017; 83: 340–347.
2. Barrellier P., Rame J.P., Chasle J., Souquieres Y., Lecacheux B. – Le dépistage des cancers de la cavité buccale par le bleu de toluidine, *Actual. Odontostomatol* 1987, 36(137): 87-92.
3. Becker J., Schuppan D. – Altered expression of extracellular matrix proteins and integrins in oral lichen planus, *J.Oral Pathol. Med* 1995; 24(4): 159-164.
4. Binnie W.H. – Risk factors and markers for oral cancer in low incidence areas of the world, *Oral Cancer, vol. 2, Cambridge University Press*, 1991: 64-88.
5. Burlibaşa C., Țovaru S. Noi orientări privind formele de debut ale cancerului bucal, *Stomatologia*, Bucureşti, 1986; 1: 1-37.
6. Camile S. F., Nirav B., Yastira L., An VU, Keziah J., Vishal G., John B., Alexander J., Deepak K., Advances in Early Detection and Diagnostic Adjuncts in Oral Cavity Cancer, *Contemporary Oral Oncology: Biology, Epidemiology, Etiology, and Prevention*, DOI 10.1007/978-3-319-14911-0_9
7. Chen Y-W, Lin J-S., Wu G-H., Lui M-T, Kao S-Y, Fong Y.. Application of In Vivo Stain of Methylene Blue as a Diagnostic Aid in the Early Detection and Screening of Oral Squamous Cell Carcinoma and Precancerous Lesions, *J Chin Med Assoc*, November 2007; 70(11): 399-503
8. Costan V.V., Ciofu M., Toader P.M., Filioreanu A. M., Danciu M., Taranu T., Popa C., Popescu E. Specific features in the diagnosis and treatment of malignant transformed leukoplakias. *Oral Oncology*, 2013; 49(1): S 66.
9. Hînganu D., Eva I., Stan C., Hînganu M.V., Morphological aspects of the rectal neovascularization in colorectal cancer – anatomical-surgical and imaging implications. *Rom J Morphol Embryol* 2016; 57(1): 161-165.
10. Filioreanu A.M., Popescu E., Cotruz C. – Immunohistochemical and Transmission Electron Microscopy Study Regarding Myofibroblast in Fibroinflammatory Epulis and Giant Cell Peripheral Granuloma. *Romanian Journal of Morphology and Embryology*, 2009; 50(3): 363-368.
11. Crăcană A, Sulea D, Nicolau A, Popa E, Popescu E. Risk Factors in the Emergence of Oral Cancer – Retrospective Study. *Romanian Journal of Oral Rehabilitation* 2016; 8(3): 48 -63.
12. Elimairi I, Altay MA, Abdoun O , Elimairi A, Tozoglu S. Dale A. Baur, Queresly F. Clinical relevance of the utilization of vital Lugol's iodine staining in detection and diagnosis of oral cancer and dysplasia, DOI 10.1007/s00784-016-1925, *Clin Oral Invest*, 2017; 21: 589–595.
13. Gogălniceanu D, Trandafir V, Trandafir D, Popescu E. Generalized gingival hyperplasia–Precocious clinical manifestation in acute leukemia. Case presentation. *Rev. Med. Chir. Soc. Med. Nat., Iasi* 2010; 114(2): 576-579.
14. Krishnamoorthy B., Suma G.N., Yadav B. ''Vital'' staining - A simple chair side oral cancer screening technique, *Journal of Dental Specialities*, 2014; 2(1): 108-110.
15. Laskaris G., Laskaris M., Theodoridou M. – Oral hairy leukoplakia in a child with AIDS, *Oral Surg. Oral Med., Oral Path. Oral Radiol. Endod.*, 1995, 79(5): 570-571.
16. Lingen M. W., Kalmar J.R., Karrison T., Speight P. M. Critical evaluation of diagnostic aids for the detection of oral cancer, *Oral Oncology*, 2008; 44: 10-22.
17. Hînganu M.V., Stan C.I., Țaranu T., Hînganu D., Morphological changes in support mechanism of superficial face layers in Moebius syndrome. *Rom J Morphol Embryol* 2017; 58(3): 851-855.
18. Francu L.L., Hînganu D., Hînganu M.V., Anatomical evidence regarding sustentaculum facies. *Rom J Morphol Embryol* 2013; 54(3): 757–761.
19. Cobzeanu M.D., Costinescu V., Rusu C.D., Mihailovici S., Grigoraş M., Miron L., Păduraru D., Aramă A. Laryngotraheal non-Hodgkin lymphoma, *Chirurgia*, 2010; 105(1): 131-136.

20. Maeda K., Suzuki T., Ooyama Y., Nakakuki K., Yamashiro M., Okada N., AMAGASA T. Colorimetric analysis of unstained lesions surrounding oral squamous cell carcinomas and oral potentially malignant disorders using iodine. *International Association of Oral and Maxillofacial Surgeons. Int. J. Oral Maxillofac. Surg.* 2010; 39: 486-492.
21. Tiepeng X., Hiroshi K., Tetsu S., Yoshitaka N., Takeshi K. Vital staining with iodine solution in oral cancer: iodine infiltration, cell proliferation, and glucose transporter 1, *Int J Clin Oncol* 2013; 18: 792–800.

NEWS

INTRALEAFLET HEMORRHAGES ARE A COMMON FINDING IN SYMPTOMATIC AORTIC AND MITRAL VALVES

Worldwide, heart valve disease is an important clinical problem and responsible for a significant mortality and morbidity. Post inflammatory valvular disease, usually rheumatic of origin, is declining in the industrialized countries but still has a high incidence in developing countries, varying from 2.5 to 3.2 cases per 1,000. Traditionally, the pathogenesis of degenerative heart valve disease was thought to be the result of time-dependent “wear-and-tear” of the leaflets, which results in thickening of valve tissue due to fibrosis, calcification, and a low-grade inflammatory response. High rates of intraleaflet hemorrhage (ILH) have recently been reported in degenerative aortic valve disease. In that study, ILH was related to the severity of stenosis and preexistent valve tricuspid or congenitally bicuspid morphology. Hemorrhages in valve tissue, as noted by Akahori et al., could relate to “wear-and-tear” processes leading to small fissures, ruptures, or friction in the highly calcified valves. Alternatively, such hemorrhages could also relate to presence of microvessels since microvessels have been described in degenerative aortic valve tissue. Because nowadays, it is not known whether hemorrhages occur in degenerative aortic valves only or whether they can also be encountered in mitral valves and in other disease states such as rheumatic heart disease, the authors investigated the prevalence, extent, and age of ILH in a consecutive series of 105 surgically resected aortic and mitral valves. In addition, they investigated the presence of microvessels and the integrity of their vessel wall as a potential source of hemorrhages. Finally, all data were related to the pathological diagnosis of valve disease. The results showed, that the prevalence of ILH is very high in resected heart valves, both aortic and mitral valves presented an association of ILH with microvessels, microvascular leakage, and calcifications. The authors concluded that repetitive microvascular-leakage-related ILH may contribute to valve dysfunction on the (very) long term (Stam OCG, van Rijswijk JW, de Mol BAJM, van der Wal AC. Intraleaflet hemorrhages are a common finding in symptomatic aortic and mitral valves. *Cardiovascular Pathology* 2017, 30: 12-18).

Doina Butcovan