

Microanatomic aspects of arterial blood supply in rectal carcinomas – predictive models

M. V. HÎNGANU, DELIA HÎNGANU, L. L. FRÂNCU

*Department of Anatomy,
 "Grigore T. Popa" University of Medicine and Pharmacy, Iassy*

Abstract

Rectum is divided into three distinctive regions (pelvic peritoneal, pelvic subperitoneal and perineal) regarding the regions where it is crossing through. Those three parts are individually not only due to their relation but due to their blood supply, also. The differences occur among them when one of them is involved into a neoplastic process. Both types of pelvic rectal tumors behave quite in the same way but those involving perineal rectum are much different. This is because they purchase a smaller number of anastomosis; when a tumor monopolizes a wide vessel the possibility to grow and become a metastasis is much more likely. These two processes (growth and metastasis) are directly related to the size of its supplying artery. On the other hand, a pelvic rectal tumor is more likely to metastasis by blood flow than a perineal rectal one. The last one will rather send clone cells by lymphatic drainage or will disseminate into the soft tissues around it. In this study, we want to propose an anatomical mathematical model for each of the rectal tumors, depending on their stages also. We used specimens from 24 patients and analyzed them using arteriography; we connected the results of mathematical counting of micro vessels density in a specific area with already known medical aspects regarding their diagnosis, treatment and evolution. The goal of the study concerns the prognosis of the patients (with or without surgical treatment) and the example is useful in rectal tumors staging.

Keywords: growing tumors, mathematic example, neoangiogenesis, rectal cancer.

✉ Introduction

The complex processes of angiogenesis as the outgrowth of new vessels from a pre-existing vascular network is fundamental to the understanding of vascularization in many physiological and pathological processes. In normal situations, angiogenesis is the process whereby new blood vessels are formed during embryogenesis, fetal development and placenta growth, for example. Under pathological conditions, angiogenesis is basic to wound healing, rheumatoid disease and thrombosis. In particular it is a key player during the initiation and progressive growth of most types of solid tumors and metastasis [1, 2], tumor cells and blood vessels forming together a highly integrated ecosystem.

Blood is a complex fluid, the rheological properties of which lead to interesting feedback mechanisms during perfusion. Shear stresses generated within the capillary bed by the flowing blood strongly influence vessel adaptation and network remodeling [3]. These shear stresses are instead affected by blood viscosity, the distribution of which depends upon a non-uniform distribution of hematocrit (the volume fraction of the red blood cells in the blood) within the host vasculature. Solid tumors are known to progress through two distinct phases of growth – the avascular phase and the vascular phase. Endothelial cells change their dormant state in fast growing state, as a result of the signals received from the tumor cells and the associated inflammatory cells and there is known a large number of components which induces angiogenesis.

The transition from the dormant avascular state to the vascular state, wherein the tumor possesses the ability to

invade the surrounding tissue and the metastasis to distant parts of the body depends upon its ability to induce new blood vessels from the surrounding tissue to sprout towards and then gradually penetrating the tumor, thus providing it with an adequate blood supply and microcirculation. In order to accomplish this neovascularization, it is now a well-established fact that the tumors secrete a number of diffusible chemical substances into the surrounding tissues and extracellular matrix [4].

For these reasons, the microvascular intratumoral density was suggested as a criterion for prognosis in different types and locations of cancer, being used in evaluating the evolving of the breast cancer [5–7], renal cancer [8–10], rectal cancer [11], bladder [12, 13] or prostate cancer [14–16].

There were described several methods for identifying tumor vessels based on the ability of endothelial cells of vascular tissue to release antigens which can serve as markers on tissue included in paraffin, CD34 considered to be the best marker for neovascularization [17].

Regarding to the above considerations, we applied three different methods of evaluation of neoangiogenesis on angiography images of resection specimen. From the special literature data we noted that this type of measures have not been tried before in cancers in this location.

✉ Materials and Methods

This paper is part of our studies on the vasculature of colorectal carcinomas quantifying high-density neovascular area using through three different methods, each one applied by default topographies of moderately

differentiated rectal carcinoma (upper, middle and lower). We have to mention that all these cases were TNM staging IIIA and the patient ages were quite similar.

We performed quantitative evaluation of the neoangiogenesis process on the rectal neoplasm using the angiography method on the resection specimen. We applied the methods of calculating the length of the neoangiogenesis vessels, the calculation of area of development of neoangiogenesis through triangulation and Monte-Carlo method, and the techniques applied on angiography images of resection specimen.

Results

In the first processing stage, we made the imaging processing of captured images from *in vitro* angiography, and then we calculated the length of the most important neoformation vessel. It was found that in the superior rectal cancer the maximum length is 1019.2157 mm (Figure 1), in the middle rectal cancer it is 924 mm (Figure 2), in inferior rectal cancer it is 670.3964 mm (Figure 3). The progressive decrease of the length of neoformation vessel stands out in tumors from the superior part of rectum, toward the middle and then the lower part.

The made measurements revealed that the higher length was quantified on upper rectal cancer, followed by the middle and lower.

The following stage was the application of the triangulation method only on the areas with high-density

of neoformation vessel. In this case, we obtained a value of the area of maximum density of neoformation vessels, as it follows: in the superior rectal cancer it is 475 987.6199 mm² (Figure 4), in middle rectal cancer it is 380 084.6006 mm² (Figure 5) and in inferior rectal cancer it is 99 703.2271 mm² (Figure 6).

The triangulation method showed a progressive reduction in the value of the area with maximum density of neoformation vessels in the same direction, from the upper rectal cancer, to the middle rectal cancer and then to the lower rectal cancer.

In the last stage of the study, on the same areas of maximum neovascularization we applied Monte-Carlo method to calculate it. The results are very close to those obtained by triangulation method: on the superior rectal neoplasm we obtained a value of 530 866.2526 mm² (Figure 7), for the middle rectal neoplasm the value is 334 281.198 mm² (Figure 8) and for inferior rectal neoplasm is 116 990.2554 mm² (Figure 9).

Monte-Carlo method showed a progressive reduction in the value of the area of maximum neovascularization on the same sense, from the superior rectal cancer, to the middle rectal cancer and then to the lower rectal cancer, the changes being significant and similar to those obtained by the triangulation method.

In middle rectal carcinomas, we applied the Monte Carlo method to make a determination on the area uncompromised by neoangiogenesis (Figure 10).

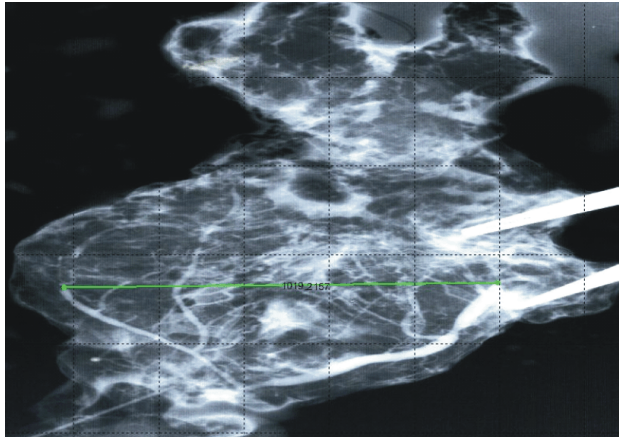


Figure 1 – The length assessment of the most important neoformation vessel in the superior rectal carcinoma.

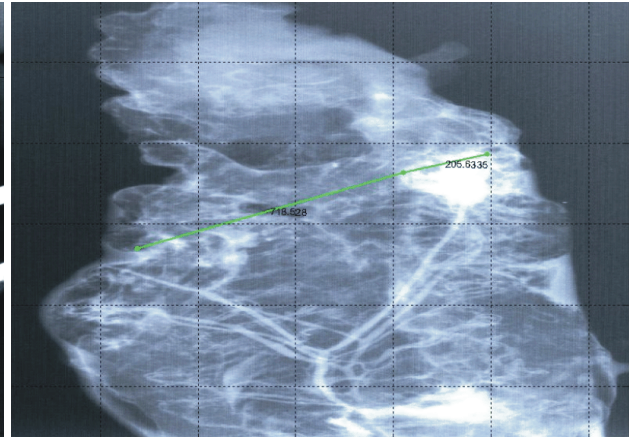


Figure 2 – The length assessment of the most important neoformation vessel in the middle rectal carcinoma.

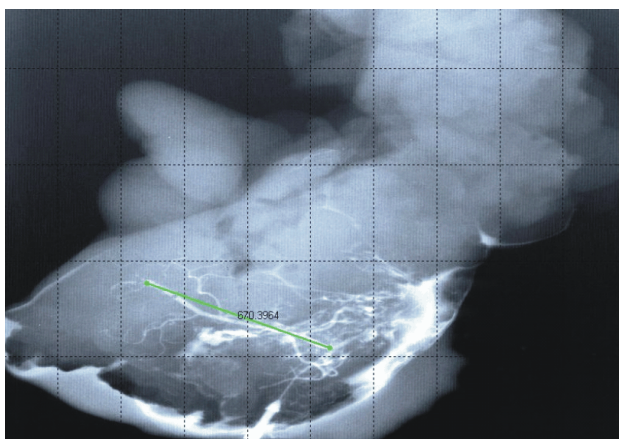


Figure 3 – The length assessment of the most important neoformation vessel in the inferior rectal carcinoma.

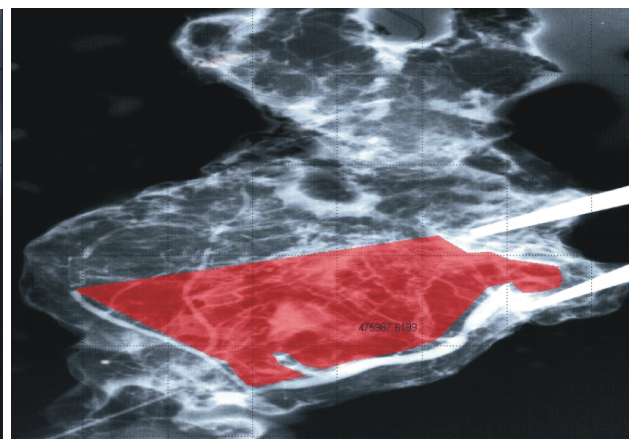


Figure 4 – Triangulation applied on the superior rectal carcinoma.

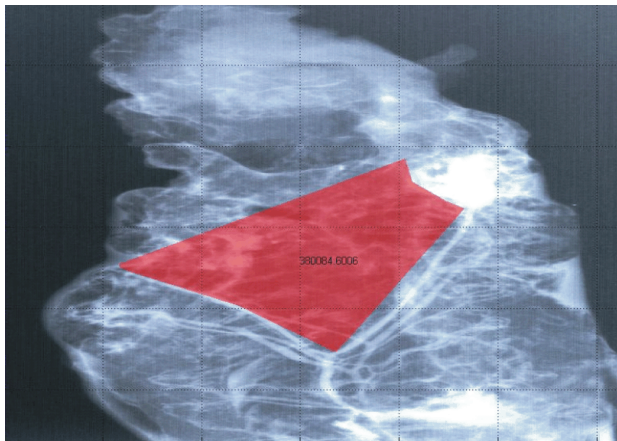


Figure 5 – Triangulation applied on the middle rectal carcinoma.

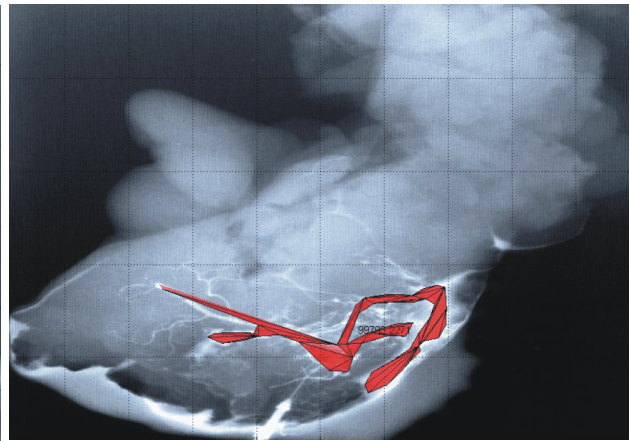


Figure 6 – Triangulation applied on the inferior rectal carcinoma.

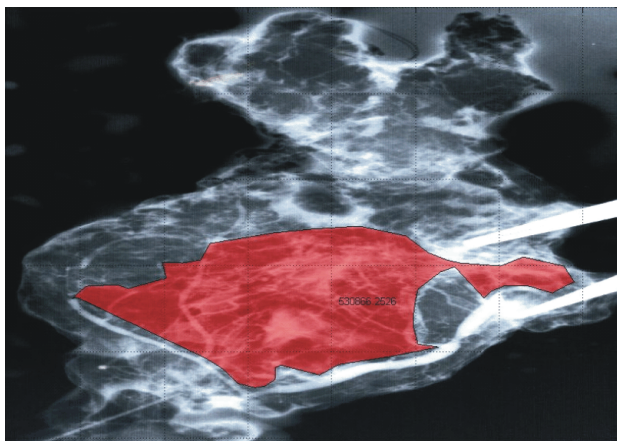


Figure 7 – Monte-Carlo method applied on the superior rectal carcinoma.

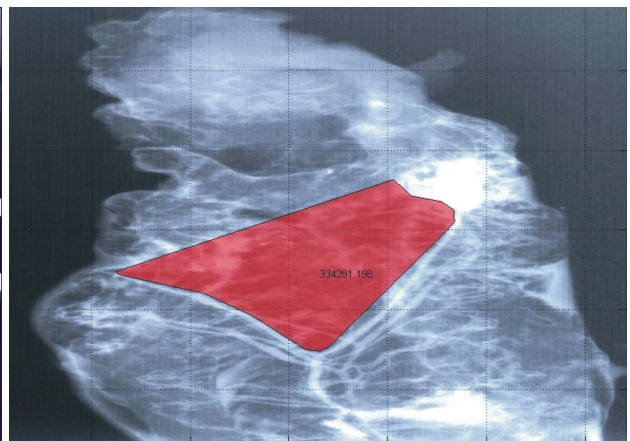


Figure 8 – Monte-Carlo method applied on the middle rectal carcinoma.

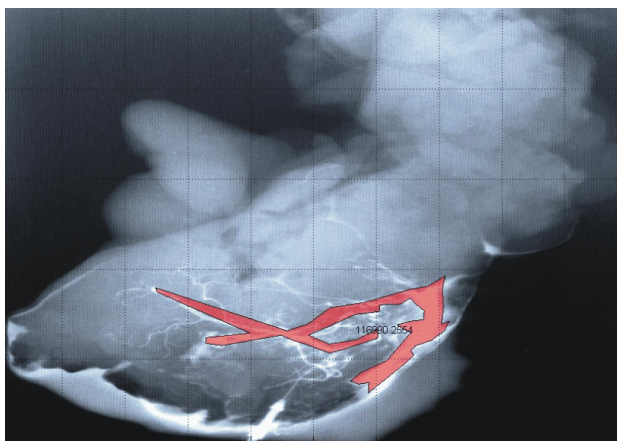


Figure 9 – Monte-Carlo method applied on the inferior rectal carcinoma.

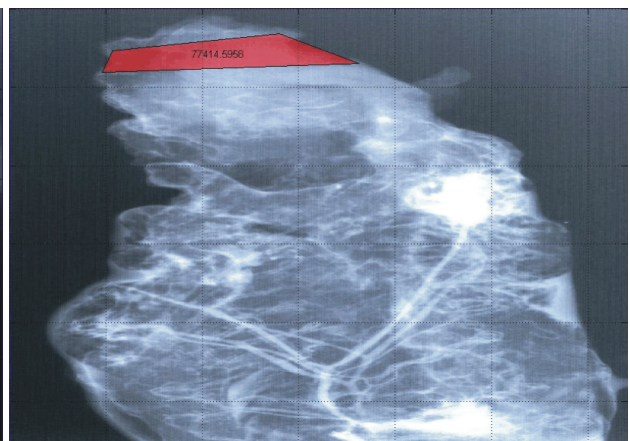


Figure 10 – Normal rectal area.

In this situation, normal area of rectal wall is approximately 4.5–5 times smaller than the area of neovascularization. The other two types of rectal carcinomas shows different aspects: in superior rectal carcinomas we did not found on the images processed a zone without neoformation vessels, and in inferior rectal carcinomas is a *vice-versa* situation.

Discussion

Quantification of the maximum neoangiogenesis area realized throughout the former three mentioned methods

sustains high potential for metastasis *via* blood flow of the superior and the inferior rectal tumors and explains their larger size compared to the inferior rectal ones.

Comparison of microquantifying on histological sections, previously performed, with microvascular density on surgery specimen noted a significant correlation. Vascular index is considered a worse indicator for evaluating of lymphatic metastases and venous micro-invasion.

Although neoangiogenesis is an important step in tumor genesis, a prerequisite for tumor progression, is not the only factor that determines recurrence and

metastasis. Evaluation of microvascular density may have errors due to heterogeneity micro vascular distribution. For this reason, it is necessary to analyze multiple images and sections of tumor, in order to obtain representative measurements with a high-degree of accuracy.

In colorectal cancer, neovascularization is a critical event during tumor genesis, with an early peak in malignant process [18, 19].

Clinical trials performed for tumoral staging correlates high intensity of tumor genesis with tumor aggressiveness, a high microvascular density having a predictive role in development of metastases.

On the same material, we performed studies regarding tumoral microvessels, by immunohistochemistry and quantitative microanatomical methods, which support the significant increase of tumoral microvascular density with increasing of histological degree, with an inverse proportion with differentiation degree. In addition, we noted a variation of intratumoral vascular density depending on the degree of differentiation. Interpretation of our results in terms of literature data allows us to consider that neoangiogenesis remains an independent predictive and prognostic factor that should be considered in determining the treatment of patients with colorectal cancer.

As we said before, the quantification of the tumoral microvascular density is considered to be an indicator for the most of the malignant neoplasms, although sometimes the results are contradictory. In addition, the angiogenesis is heterogeneous in the same tumor [20, 21] and the microvascular density assessment/evaluation is less useful in achieving new data regarding architectural complexity defined by the degree of the ramification, irregularity and tortuosity [22]. The malignant tumors have a high-vascular complexity compared to the adjacent normal vasculature; the vessels are getting chaotic or random branches [9, 22].

Clinical, surgical and imaging observations support the presence of a pelvic vascular paraneoplastic syndrome, kind as arterial, venous or lymphatic; the inferior rectal tumors pediculated arteries to their base, the middle and the inferior rectal tumors give inflammatory phenomena, like vasculitis or perivasculitis, especially on the path veins.

Any paraneoplastic vascular change on both rectal and pelvic vessels represents the guiding criteria of oncological surgery, being in accordance with surgical technique that is dictated by it.

Our results obtained by using the quantification of the tumoral angiogenesis *via* those three methods could group the patients after the most useful type of treatment and also re-orientate their perspective management for those with low microvascular density. However, we believe that the antiangiogenetic therapy requires individually customizing.

✉ Conclusions

Our studies demonstrate the objective progressive decrease in the length of the neoformation blood vessels and of the area of maximum neovascular density from the tumors located in the superior rectum and its middle and inferior parts. Compared to the affected area of neoangiogenesis, uncompromised area missing in the

upper rectal carcinoma, is less in the middle, and is greater in lower rectal carcinoma. Colorectal and superior rectal carcinomas have a better oncologic prognosis, because arteriography showed metastasis tumor invasion only in the advanced cases; on the other hand, middle rectal tumors and especially inferior ones have a truly vascular pedicle, which shows up from the early phases.

References

- [1] Folkman J, *Tumor angiogenesis: therapeutic implications*, N Engl J Med, 1971, 285(21):1182–1186.
- [2] Liao Z, Boileau TW, Erdman JW Jr, Clinton SK, *Interrelationships among angiogenesis, proliferation, and apoptosis in the tumor microenvironment during N-methyl-N-nitrosourea androgen-induced prostate carcinogenesis in rats*, Carcinogenesis, 2002, 23(10):1701–1712.
- [3] Adam JA, *A mathematical model of tumor growth. II. Effects of geometry and spatial nonuniformity on stability*, Math Biosci, 1987, 86(2):183–211.
- [4] McDougall SR, Anderson ARA, Chaplain MAJ, Sherratt JA, *Mathematical modelling of flow through vascular networks: implications for tumor-induced angiogenesis and chemotherapy strategies*, Bull Math Biol, 2002, 64(4):673–702.
- [5] Bosari S, Lee AKC, DeLellis RA, Wiley BD, Heatley GJ, Silverman ML, *Microvessel quantitation and prognosis in invasive breast carcinoma*, Hum Pathol, 1992, 23(7):755–761.
- [6] Hall NR, Fish DE, Hunt N, Goldin RD, Guillou PJ, Monson JRT, *Is the relationship between angiogenesis and metastasis in breast cancer real?* Surg Oncol, 1992, 1(3):223–229.
- [7] Milliaris D, Kamas A, Kalekou H, *Angiogenesis in invasive breast carcinoma: is it associated with parameters of prognostic significance?* Histopathology, 1995, 26(2):165–169.
- [8] Herbst C, Kosmehl H, Stiller KJ, Berndt A, Eiselt M, Schubert J, *Evaluation of microvessel density by computerised image analysis in human renal cell carcinoma. Correlation to pT category, nuclear grade, proliferative activity and occurrence of metastasis*, J Cancer Res Clin Oncol, 1998, 124(3–4):141–147.
- [9] Sabo E, Boltenko A, Sova Y, Stein A, Kleinhaus S, Resnick MB, *Microscopic analysis and significance of vascular architectural complexity in renal cell carcinoma*, Clin Cancer Res, 2001, 7(3):533–537.
- [10] Lidgren A, Hedberg Y, Grankvist K, Rasmuson T, Vasko J, Ljungberg B, *The expression of hypoxia-inducible factor 1alpha is a favorable independent prognostic factor in renal cell carcinoma*, Clin Cancer Res, 2005, 11(3):1129–1135.
- [11] Sökmen S, Sarioglu S, Füzün M, Terzi C, Küpelioğlu A, Aslan B, *Prognostic significance of angiogenesis in rectal cancer: a morphometric investigation*, Anticancer Res, 2001, 21(6B):4341–4348.
- [12] Bakkar AA, Wallerand H, Radvanyi F, Lahaye JB, Pissard S, Lecerf L, Kouyoumdjian JC, Abbou CC, Pignon JC, Jaurand MC, Thiery JP, Chopin DK, de Medina SG, *FGFR3 and TP53 gene mutations define two distinct pathways in urothelial cell carcinoma of the bladder*, Cancer Res, 2003, 63(23):8108–8112.
- [13] Goddard JC, Sutton CD, Furness PN, O'Byrne KJ, Kockelbergh RC, *Microvessel density at presentation predicts subsequent muscle invasion in superficial bladder cancer*, Clin Cancer Res, 2003, 9(7):2583–2586.
- [14] Mazzucchelli R, Montironi R, Santinelli A, Lucarini G, Pignatelli A, Biagini G, *Vascular endothelial growth factor expression and capillary architecture in high-grade PIN and prostate cancer in untreated and androgen-ablated patients*, Prostate, 2000, 45(1):72–79.
- [15] Bono AV, Celato N, Cova V, Salvatore M, Chinetti S, Novario R, *Microvessel density in prostate carcinoma*, Prostate Cancer Prostatic Dis, 2002, 5(2):123–127.
- [16] Du Z, Fujiyama C, Chen Y, Masaki Z, *Expression of hypoxia-inducible factor 1alpha in human normal, benign, and malignant prostate tissue*, Chin Med J (Engl), 2003, 116(12):1936–1939.
- [17] de la Taille A, Katz AE, Bagiella E, Buttyan R, Sharir S, Olsson CA, Burchardt T, Ennis RD, Rubin MA, *Microvessel density as a predictor of PSA recurrence after radical prostatectomy. A comparison of CD34 and CD31*, Am J Clin Pathol, 2000, 113(4):555–562.

- [18] Pavlopoulos PM, Konstantinidou AE, Agapitos E, Kavantzias N, Nikolopoulou P, Davaris P, *A morphometric study of neo-vascularization in colorectal carcinoma*, Cancer, 1998, 83(10): 2067–2075.
- [19] Goh V, Padhani AR, Rasheed S, *Functional imaging of colorectal cancer angiogenesis*, Lancet Oncol, 2007, 8(3):245–255.
- [20] Wang Y, Reed M, Wang P, Stenger JE, Mayr G, Anderson ME, Schwedes JF, Tegtmeier P, *p53 domains: identification and characterization of two autonomous DNA-binding regions*, Genes Dev, 1993, 7(12B):2575–2586.
- [21] Costello P, McCann A, Carney DN, Dervan PA, *Prognostic significance of microvessel density in lymph node negative breast carcinoma*, Hum Pathol, 1995, 26(11):1181–1184.
- [22] Baish JW, Jain RK, *Fractals and cancer*, Cancer Res, 2000, 60(14):3683–3688.

Corresponding author

Delia Hînganu, MD, PhD, Department of Anatomy, “Grigore T. Popa” University of Medicine and Pharmacy, 16 University Street, 700115 Iassy, Romania; Phone +40744–797 516, e-mail: delia_f24@yahoo.com

Received: April 20, 2013

Accepted: August 3, 2013

