



GRIGORE T. POPA UNIVERSITY OF
MEDICINE AND PHARMACY IASI

HABILITATION THESIS

Grigore Mihaela, MD, PhD
Associate Professor

2019



GRIGORE T. POPA UNIVERSITY OF
MEDICINE AND PHARMACY IASI

HABILITATION THESIS

MODERN CONCEPTS IN GYNECOLOGY. CLINICAL APPLICATIONS

Grigore Mihaela, MD, PhD
Associate Professor

Summary	1
Rezumat	3
Section I – Scientific, professional and academic achievements	5
I.1.Introduction	5
I.2.1. Studies in cervical cancer	8
I.2.1.1. Primary prevention and secondary prevention of cervical cancer	8
I.2.1.1 Background	8
I.2.1.2 Primary prevention in Romania- the impact of HPV vaccination	11
I.2.1.2.1.Introduction.....	11
I.2.1.2.2. Material and methods.....	13
I.2.1.2.3. Results.....	14
I.2.1.2.4. Discussion.....	18
I.2.1.3 Secondary prevention in Romania- the role of cervical screening	26
I.2.1.3.1. Introduction.....	26
I.2.1.3.2. Material and methods.....	28
I.2.1.3.3. Results.....	29
I.2.1.3.4. Discussion.....	36
I.2.2. The role of colposcopy in the diagnosis of precancerous cervical lesions	42
I.2.2.1. Background.....	42
I.2.2.2. The role of inner border sign and ridge sign in detecting high-grade cervical intraepithelial neoplasia	44
I.2.2.2.1. Introduction.....	44
I.2.2.2.2. Material and methods.....	45
I.2.2.2.3. Results.....	46
I.2.2.2.4. Discussion.....	47
I.2.3. The management of preneoplastic cervical lesion and cervical cancer	49
I.2.3.1. Background.....	49
I.2.3.2. Material and methods.....	51
I.2.3.3. Results.....	52
I.2.3.4. Discussion.....	56
I.3. Studies in minimally invasive surgery in gynecology	63
I.3.1. Introduction	63
I.3.2.Pro and cons for endometrial ablation	66
I.3.2.1.Background.....	66
I.3.2.2. Material and methods.....	68
I.3.2.3. Results.....	69
I.3.2.4. Discussion.....	84
I.3.3.The role of minimally invasive surgery in rare clinical conditions	87
I.3.3.1. Introduction.....	87
I.3.3.2. Material and methods.....	88

I.3.3.3. Results.....	89
I.3.3.4. Discussion.....	92
I.4. Studies in three-dimensional ultrasound and modern imagistic techniques in obstetrics and gynecology.....	97
I.4.1. Introduction.....	97
I.4.2. 3D ultrasound and HD/live technologies in obstetrics.....	99
I.4.2.1. Background.....	99
I.4.2.2. Material and methods.....	101
I.4.2.3. Results.....	103
I.4.2.4. Discussion.....	111
I.4.3. 3D ultrasound and novel technologies in uterine and ovarian pathologies	117
I.4.3.1. Background.....	117
I.4.3.2. Material and methods.....	121
I.4.3.3. Results.....	121
I.4.3.4. Discussion.....	127
I.4.4. 3D ultrasound in infertility and endometriosis.....	131
I.4.4.1. Background.....	131
I.4.4.2. Material and methods.....	132
I.4.4.3. Results.....	133
I.4.4.4. Discussion.....	135
Section II – Future projects in the academic, professional and research fields.....	138
II.1. Improvements in the academic field.....	138
II.2. Further professional development.....	139
II.3. Perspectives for future research.....	139
II.4. Final remarks.....	143
Section III – References.....	144

Summary

The habilitation thesis presents my academic, scientific and medical activity in the postdoctoral period (2001-2018). The aim of the thesis is to describe an integrative picture of my work in this period with an emphasis on achievements in the field of scientific research. The thesis is structured on three sections subdivided into chapters, as follows:

Section I represents a summary of scientific activity after PhD thesis until accreditation for the title of Associate Professor.

Chapter 1 contains a synthetic review of the academic, scientific and medical achievements in the 18 years of postdoctoral period.

Chapter 2 presents one of my main research areas of interest: cervical cancer and precancerous diseases. This theme was a constant component of my clinical, academic and research activity. Cervical cancer prevention represents a major epidemiological problem in Romania. For the last 30 years, Romania had the highest cervical cancer mortality in Europe, with rates 6 times higher than the average cervical cancer mortality in the European Union countries.

Given the importance of the matter in Romania, I have invested a significant amount of time in pursuing related topics from the beginning of my medical and scientific career. For instance, I completed an internship on cervix pathology in Germany, which enabled me to develop relevant skills in the fields of colposcopy, the treatment of preneoplastic cervical lesions, and cytopathology. At the end of the internship, I sat in an exam leading to the formal recognition of my professional competence in cytology by the German Society of Cytology, and resulting in my becoming a member of the International Academy of Cytology. Subsequently, my track record with regard to the cervix pathology consisted in both clinical and didactic activities (including the publication of monographs, the organization of international courses and workshops, and the lecturing in postgraduate courses on this topic). I have also committed substantial time and effort into researching the pathology of the cervix, thus achieving a comprehensive, integrative view. Specifically, my research in this subject was subdivided in three main sub directions:

- Primary and secondary prevention of cervical cancer.
- The role of colposcopy in the diagnosis of precancerous cervical lesions.
- The management of preneoplastic cervical lesion and cervical cancer.

This chapter presents my personal contributions in the area: research grant, research projects, articles published in high-impact factor journals, such as: *Journal of Medical Screening* (IF-2,68), *European Journal of Public Health* (IF 2,72) *Journal of Cancer Education* (IF- 1,54), *European Journal of Gynecologic Oncology* (IF-0,64)

Chapter 3 presents my work progress and the studies in the field of minimally invasive surgery in gynecology with special emphasis on techniques of endometrial ablation. Over the past twenty years gynecologic surgery has evolved from abdominal approach to the current focus on minimally invasive surgical techniques. My ongoing interest in advancing my clinical expertise is manifested in my pursuit of specializations in the field of endoscopic surgery, both in Romania at abroad (France, Germany, Belgium). The aim has been to acquire recognized professional competences (e.g. Diplome Européenne d'Endoscopie Opératoire, ESGE level II Gynecologic surgeon), as well as to introduce minimally invasive surgical techniques

at my workplace (e.g. laparoscopic myomectomy and hysterectomy). I published several paper published in prestigious journals and with my colleagues form Cohrane Gynecologic Group I elaborated a systematic review on techniques of “first-generation” and “second generation” of endometrial ablation published in *Cochrane Database Systematic Review* (IF 7,66).

Chapter 4 presents the current state of the art and several studies on novel imagistic techniques like three-dimensional (3D) ultrasound, HDlive. The research studies was divided in five directions:

- 3D ultrasound and HDlive technologies in obstetrics
- 3D ultrasound and novel technologies in uterine and ovarian pathologies
- 3D ultrasound in infertility and endometriosis.

Some of the important articles in this area that I wrote were published in high-impact factor journals, such as: *Ultrasound in Obstetrics and Gynecology* (IF 3,32), *Clinical Imaging* (IF 0,7), *Medical Ultrasonography* (IF 1,54), *Clinical Antomy* (IF 1,5).

Section II includes a series of specific strategies of the three important fields: the didactic activity, the healthcare clinical activity and the scientific research activity.

In the chapter dedicated to the didactic activity I present the development directions regarding the partnership with the students, residents or training physicians.

My future medical clinical activity will be based on the accumulation of new knowledge and development of new skills and competencies.

The scientific research will focus on three main areas: cervical cancer, 3D ultrasound, and minimally invasive surgery. There are main future directions of research: studies on vaginal microbiota and its role in HPV infections, HPV-self sampling methods and their possible role in increase participating in screening programs, isthmocele- role of 3D ultrasound in planning surgery and best way to achieve a good result.

Section III includes the bibliographic references supporting the studies presented in the habilitation thesis.

Rezumat

Teza de abilitare prezintă activitatea mea academică, științifică și medicală în perioada post-doctorală (2001-2018). Scopul acesteia este de a descrie într-un mod integrat munca și rezultatele mele din acest interval de timp, cu accent mai ales asupra realizărilor din domeniul cercetării științifice. Lucrarea este structurată în trei secțiuni divizate în capitole, după cum urmează:

Secțiunea I prezintă un sumar al activităților științifice desfășurate după obținerea gradului doctoral până la momentul acreditării în calitate de conferențiar universitar.

Capitolul 1 conține un sumar sintetic al tuturor realizărilor în plan academic, științific și medical obținute în cei optsprezece ani de la obținerea titlului doctoral.

Capitolul 2 prezintă unul din domeniile asupra cărora m-am concentrat în mod deosebit în toți acești ani, și anume cancerul de col uterin și afecțiunile precanceroase ale acestuia. Această temă a fost una din ariile predilecte și constante de interes în activitățile mele clinică, academică și de cercetare. Prevenirea cancerului de col uterin reprezintă o problemă majoră de sănătate publică în România. În ultimii 30 ani România a fost țara cu cea mai mare mortalitate asociată cu această formă de cancer, cu o rată a mortalității de șase ori mai mare decât media Uniunii Europene luată în ansamblu.

Data fiind importanța acestei probleme în România, am investit un capital semnificativ de timp în studierea temei cancerului de col uterin încă de la debutul carierei mele medicale și științifice. Aceste eforturi au cuprins un stagiul de pregătire în patologia colului efectuat în Germania, stagiul care mi-a permis să dezvolt abilități în domeniile colposcopiei, tratamentului leziunilor cervicale preneoplazice și citopatologiei. La finalul acestui stagiul am susținut un examen care a atestat oficial recunoașterea competenței profesionale în citologie de către Societatea Germană de Citologie ceea ce a condus la acordarea calității de membru al Academiei Internaționale de Citologie. Ulterior, activitatea mea în domeniul patologiei colului uterin a constat atât în activități clinice, cât și didactice (incluzând publicarea de monografii, organizarea de cursuri și ateliere de activitate clinică internaționale, precum și lectorat în cadrul cursurilor postuniversitare pe această temă).

Am alocat, de asemenea, deosebit de mult timp și efort în activitatea de cercetare a patologiei colului uterin reușind să acumulez o cantitate de cunoștințe ce îmi permit să am o viziune integrată și cuprinzătoare a acestui domeniu. Pentru a detalia, activitatea mea de cercetare s-a desfășurat următoarele direcții:

- Prevenirea primară și secundară a cancerului de col uterin.
- Rolul colposcopiei în diagnosticarea leziunilor cervicale precanceroase.
- Managementul leziunilor cervicale preneoplazice și a cancerului de col uterin.

Acest capitol prezintă contribuția mea personală în acest domeniu: bursă de cercetare, proiecte de cercetare, articole publicate în reviste cu factor de mare impact, cum ar fi: *Journal of Medical Screening* (IF-2,68), *European Journal of Public Health* (IF 2,72) *Journal of Cancer Education* (IF- 1,54), *European Journal of Gynecologic Oncology* (IF-0,64).

Capitolul 3 prezintă rezultatele actuale ale muncii depuse și ale studiilor efectuate în domeniul chirurgiei minim-invazive în ginecologie, cu accent pe tehnicile de ablație endometrială. În ultimii douăzeci de ani chirurgia ginecologică a evoluat de la abordul abdominal la concentrarea, în prezent, pe tehnicile chirurgicale minimal invazive. Interesul continuu pe care l-am arătat în creșterea expertizei mele clinice s-a manifestat prin suita de cursuri și specializări urmate atât în țară cât și în străinătate

(Franța, Germania, Belgia). Scopul a fost de a dobândi competențe profesionale recunoscute (de ex. Diploma Europeană de Endoscopie Operatorie, chirurg ginecolog de nivel II ESGE etc.), precum și de a introduce tehnicile chirurgicale minim invazive în clinica în care lucrez (de ex. miomectomia și histerectomia laparoscopice). În ceea ce privește activitatea de cercetare am publicat un număr de lucrări în reviste de prestigiu internațional și împreună cu colegii mei din Grupul “Cochrane Gynecology and Infertility” am elaborat o analiză sistematică a tehnicilor de „primă generație” și de „a doua generație” a ablației endometriale, analiză publicată în *Cochrane Database Systematic Review*(IF 7,66).

Capitolul 4 prezintă ultimele noutăți și diferite studii asupra ultimelor tehnici și tehnologii imagistice, precum ultrasonografia tridimensională (3D) și HDlive. Cercetările pe care le-am efectuat în acest domeniu s-au împărțit pe trei direcții:

- Tehnologiile ultrasonografice 3D și HDlive în obstetrică
- Ultrasonografia 3D și tehnologiile noi în patologia uterine și ovariană
- Ultrasonografia 3D în infertilitate și endometrioză.

Câteva din cele mai importante articole pe care le-am scris în acest domeniu au fost publicate în reviste medicale de mare impact, cum ar fi *Ultrasound in Obstetrics and Gynecology* (IF 3,32), *Clinical Imaging* (IF 0,7), *Medical Ultrasonography* (IF 1,54), *Clinical Antomy* (IF 1,5).

Secțiunea a II-a include o serie de strategii specifice fiecăruia dintre cele trei domenii importante: activitatea didactică, activitatea clinică și activitatea de cercetare științifică.

În capitolul dedicat activității didactice am prezentat direcțiile de evoluție privind parteneriatul cu studenții, medicii rezidenți și medicii al căror lector sunt în cursurile de pregătire ale acestora.

În ceea ce privește activitatea clinică viitoare, acesta va avea ca fundament acumularea de noi cunoștințe, tehnici și dezvoltarea de noi competențe.

În cercetarea științifică mă voi concentra pe trei domenii: cancerul de col uterin, ultrasonografia 3D și chirurgia minim-invazivă. Am în vedere, particularizând domeniile menționate anterior, următoarele direcții de cercetare: microbiota vaginală și rolul acesteia în infecția cu HPV, metode de auto-recoltare HPV și posibilul rol al acestora în creșterea participării la programele de screening, istmocolul - rolul ultrasonografiei 3D în planificarea chirurgicală în scopul obținerii rezultatelor optime.

Secțiunea a III-a include referințele bibliografice aferente studiilor și lucrărilor prezentate cuprinsul tezei de abilitare.

SECTION I – SCIENTIFIC, PROFESSIONAL AND ACADEMIC ACHIEVEMENTS

I.1. INTRODUCTION

My academic career started in 1992 with being awarded the title of Junior Assistant Professor at the Obstetrics and Gynecology Department, Faculty of Medicine, "Grigore T. Popa" University of Medicine and Pharmacy Iasi, Romania, following an intense and scrupulous competition. From the beginning, I have sought to balance teaching with clinical practice, to the benefit of the community that I am a part of. I began my training in obstetrics and gynecology as I became a junior assistant at the University and was acknowledged as a specialist in the field in 1996 (MSF 2707/18.12.1996). My constant desire to further my expertise is also reflected in my participation in 4 exchanges and internships abroad as follow: visiting clinician (October 1994) at the Infertility and Reproductive Pathology Clinic, McGill University, Royal Victoria Hospital Montreal, Canada (at the invitation of Prof. Togas Tulandi, Chief of Infertility Clinic), training internship in hysteroscopy -26 April - 26 July 1995- through the TEMPUS program, at the "St. Antoine" Hospital in Paris (Prof. Jacques Milliez), research and training internship in colposcopy and gynecologic cytology -01.08.1996-14.02.1997- Freiburg, Germany (Prof. Manuel Hilgarth) and training internship within the "FIGO Fellowship Program", at Vanderbilt University in Nashville, Tennessee, in September 2000, under the supervision of Prof. Howard Jones III. I then became a consultant in 2001 (MSF 8504/21.08.2001).

My joining the ranks of medical faculty staff and pursuing an academic career were facilitated, by starting PhD research in 1995. I completed my doctoral degree in 2001 with the thesis "The Liver and Pregnancy" and was awarded the title Doctor in Medical Science (diploma 4911 from 02.11.2001). My PhD research focused on the relationship between pregnancy and various liver diseases such as viral hepatitis, pregnancy cholestasis, HELLP syndrome. Also, I conducted an experimental study in which I induced HELLP syndrome to mice by administering endothelin and contributed to shedding light on the pathogenesis of this condition. After finalizing the thesis I elaborated a monograph titled "Liver and pregnancy" (Junimea Publishing House, 99 Esculap Collection, 2004, ISBN 973-37-0919-0.).

My postdoctoral evolution has been geared towards scientific research, professional clinical medical practice, and academic education. My clinical and scientific activity has been significantly enhanced by my mentors from Romania (Prof. Gheorghe Costachescu and Prof. Cristina Anton) and abroad (Prof. Togas Tulandi, Prof. Howard Jones III, Prof. Manuel Hilgarth, Dr. Remy Salmon, Dr. Virginie Fouchotte). With their guidance I have developed my clinical skills in the fields of gynecologic oncology, cervical pathologies, minimally invasive surgery, breast surgery.

Academic education

I lectured in over 25 national and international courses and workshops, and I contributed to the drafting of "Integrated Colposcopy – Practical Guide" (Junimea Publishing House, 104 Esculap Collection, 2005, ISBN 973-37-0982-2).

My ongoing efforts to develop academic education resulted in organizing workshops on topics such as cervix pathology, gynecologic ultrasound and endoscopic surgery, and inviting distinguished experts from Romania and abroad to lecture:

1. The Workshop “Cervical Cancer – current trends in prevention, diagnosis and treatment”, under the authority of ESGO (European Society of Gynecologic Oncology) and “Grigore T. Popa” U.M.Ph., 21-22.09.2012, Iași, Romania;
2. The Workshop “Basic skills in minimally invasive gynecological surgery” on 21.04.2016, at CONGRESSIS, Iași, Romania;
3. The Workshop “Colposcopy, HPV Disease & Cervical Cancer”, under the authority of ESGO (European Society of Gynecologic Oncology) and “Grigore T. Popa” U.M.Ph., 24-25.06.2016, Iași, Romania;
4. The Workshop “Fetal Ultrasound – Theory and Practice”, 10.05.2018, for SSMI (Iași Medical Students Society);
5. Advanced Colposcopy European Course under the authority of EFC (European Federation of Colposcopy), 19-20.09.2018, Iași, Romania.

Scientific research

My educational and clinical activities have consistently been infused and complemented by research subsequently shared as published monographs, chapters in specialized textbooks, articles, as well as presented in numerous scientific events. Some of the articles were published in renowned journals with high impact factor: *Cochrane Database Systematic Review* (IF 7,66), *Journal of Medical Screening* (IF- 2,68), *European Journal of Public Health* (IF- 2,72) *Journal of Cancer Education* (IF- 1,54), *European Journal of Gynecologic Oncology* (IF- 0,64), *Ultrasound in Obstetrics and Gynecology* (IF 3,32), *Clinical Imaging* (IF 0,7), *Medical Clinical Anatomy* (IF 1,5).

The results of my research work can be summarized as follows:

- 22 articles printed in full in ISI-rated journals with impact factor, in which I am the lead author and co-author (cumulated Impact Factor- 34,7), 4 of them awarded from UEFISCDI (Executive Agency for Higher Education, Research, Development and Innovation Funding);
- 41 articles indexed in international databases (21 as lead author and 20 as coauthor);
- 40 abstracts in volumes of proceedings from national conferences, of which 12 featured in supplements to ISI-rated journals with impact factor;
- Coordination of 1 internal research grant at “Grigore T. Popa” U.M.Ph. Iași, entitled “First effects of HPV vaccination in Romania – a cross-sectional study in the Northeastern part of the country”;
- Membership in the Romanian teams of a COST project (COST Action CA16115 cu titlul: ”A European Network for Connective Tissue Calcifying Diseases”) and an Erasmus project (HOPE project);
- 1 international workshop grant;
- 2 international mobility grants.

Cooperation with prestigious international organizations has been an important trademark for my professional activity. My constant collaboration with European Society of Gynecologic Oncology (ESGO) and European Federation of Colposcopy (EFC) over the last few years is worth mentioning here. Together with ESGO, I organized two international workshops in which renowned national and international

speakers shared their expertise on cervical cancer, and, together with EFC, I organized the First European Advanced Course in Colposcopy in Romania.

Another international collaboration has been the Cochrane Gynecology Group, which relates to my scientific activity. With colleagues from this group, I worked on the elaboration of a systematic review and a meta-analysis regarding techniques of endometrial ablation, published in Cochrane Database Systematic Review.

Clinical medical practice

Being a surgeon is a lifelong journey and rapid evolution of technology and knowledge requires the surgeon to continuously improve his education.

Competences acquired in Romania: obstetric and gynecologic ultrasonography (Ministry of Health certificate C 0011225/1999), colposcopy and cytodiagnosis (Ministry of Health certificate A 001311/1999), hysteroscopy (Ministry of Health certificate C 012386/2006), gynecologic laparoscopic surgery (Ministry of Health certificate C 019154/2007), assisted reproduction (Ministry of Health certificate 038012/2015), sanitary management (Ministry of Health certificate C 042486/2017).

Competences acquired abroad:

- Gynecologic cytology competences formally acknowledged by the German Society of Cytology based on examination on 30.01.1997 in Freiburg, Germany;
- Gynecologic laparoscopy competences according to the Diplome Européenne d'Endoscopie Opératoire, 2007-2008, Université d'Auvergne, Clermont Ferrand;
- Minimally Invasive Gynecological Surgeon Certificate from the European Academy of Gynecological Surgery, 08.06.2017.

Training period abroad:

- Training internship in senologic surgery at Curie Institute in Paris, 01.03.2010-01.06.2010, under the supervision of Dr. Remy Salmon and Dr. Virginie Fourchette.

Concurrently instrumental to my scientific, clinical and academic endeavors, I have always been interested in actively joining professional organizations from Romania and abroad in the field of obstetrics and gynecology. I am a member of The Romanian Society of Obstetrics and Gynecology, European Society of Endoscopic Gynecology, European Society of Gynecologic Oncology, International Society of Ultrasound in Obstetrics and Gynecology. I am a founding member of the Romanian Society of Cytology, of the Romanian Society of Gynecologic Oncology, and of the Romanian Society of Colposcopy and Lower Genital Tract Pathology (of which I am currently the Secretary).

I.2. STUDIES IN CERVICAL CANCER

As one of the leading causes of cancer mortality, cervical cancer continues to be a major health problem. It is the fourth most common cancer among women worldwide, with an estimated 528 000 new cases and 266 000 deaths in 2012. Most cases (80%) occur in developing countries, and cervical cancer mortality is also high in less developed countries (*Globocan, 2012*).

Cervical cancer can be effectively controlled by means of primary prevention (prophylactic HPV vaccination) and secondary prevention (cervical cancer screening). Cervical cancer screening has had a substantial impact on the incidence of and mortality from cervical cancer in many developed countries. Routine Papanicolaou smear (Pap smear) screening has substantially reduced the rates of invasive cervical cancers in these countries (*Saraiya, 2003, Waxman, 2005*).

Cervical cancer and precancerous diseases have featured among my ongoing clinical, academic and research interests, with specific regard to the following key directions:

- Primary and secondary prevention of cervical cancer.
- The role of colposcopy in the diagnosis of precancerous cervical lesions.
- The management of preneoplastic cervical lesion and cervical cancer.

I.2.1. PRIMARY PREVENTION AND SECONDARY PREVENTION IN CERVICAL CANCER

I.2.1.1. BACKGROUND

Cervical cancer is a public health concern of formidable scale illustrated by an estimated incidence of 570,000 cases and 311,000 deaths in 2018 worldwide. It ranks as the fourth most frequently diagnosed type of cancer and the fourth leading cause of cancer death in women (*Bray et al., 2018*). In Europe, an estimated 61,100 women are diagnosed with cervical cancer annually, and 24,404 of them die from this illness (*Ferlay et al., 2018*).

Over the last few decades, cervical cancer incidence and mortality rates have been declining in many populations worldwide. The main explanation is the introduction of organized screening programs based on the Papanicolaou (Pap) smear test, which enables the identification of morphological changes in the cervical epithelium and the detection of precancerous cervical lesions. Screening programs for cervical cancer date back to 1960s and 1970s, and the Pap test is still a cornerstone in the majority of ongoing programs (*Ulrich, 2014*). It was estimated that the incidence of invasive cervical cancer can be reduced by at least 80% with the implementation of cervical cancer screening programs in which women aged 35-64 repeat the Pap test every three to five years (*IARC Handbook, 2005*). Aside from screening (where available), the decline in incidence and mortality has been linked to socioeconomic progress and a diminishing risk of persistent infection with high-risk HPV as a result of better genital hygiene, reduced parity, and curtailed prevalence of sexually transmitted diseases (*IARC Handbook, 2005*).

Cervical cancer screening was revolutionized in the early 1980s by the discovery of human papillomaviruses (HPV) as the single causal agents of the disease. HPVs are the most common sexually transmitted viruses. To date, more than 120 types of HPV have been identified. However, not all HPV types have been linked

to cervical cancer. The demonstrable statistical association with the risk of HPSs causing cancer was the criterion used to classify HPVs into high- and low-risk. At least 12 HPVs are considered oncogenic, high-risk (HR) types, causing more than 97% of cervical cancer cases (*De Villiers, 2013*).

Genital HPV is acquired through intimate skin-to-skin contact, not just penetrative sexual intercourse, and has a lifetime risk of infection of up to 80% in exposed individuals (*Fiander, 2009*). In the majority of cases, the infection is transient, asymptomatic and cleared by the immune system in six months to two years. However, persistent HPV infection occurs in 10–15% of women and is associated with various forms of cancer (*Kitchener et al., 2006*). Only after a persistent infection can HPV lead to low- and/or high-grade cervical intraepithelial neoplasia, which may eventually evolve into cervical cancer. HPV is the necessary but not sufficient cause of cervical cancer; other important cofactors include immunosuppression (particularly human immunodeficiency virus), smoking, parity (a higher number of full-term pregnancies increases risk), and oral contraceptive use. The relationship between HPV infection and cervical cancer is of great significance in both primary (vaccination) and secondary (screening) cervical cancer prevention.

Testing for HPV as the initial method of screening for cervical cancer (HPV primary screening) has been shown to be effective. HPV testing is characterized by high clinical sensitivity, high negative predictive value, objectivity, few training requirements, scalability and high-throughput capacity (*Basu et al., 2018*). Another advantage of HPV screening is that it allows for longer screening intervals than cytology-based screening, because progression to cancer occurs years after infection with HR-HPV. A recent review of four randomized trials found that HPV-based primary screening provides 60–70% greater protection against invasive cervical carcinomas compared with cytology (*Ronco et al., 2014*). Nowadays, the European Guidelines recommend a five-year screening interval for HPV testing, which may be extended to up to 10 years depending on the age and screening history of the patient. (*Von Karsa et al., 2015*). Longer screening intervals present the advantage of making screening programs less expensive. However, the high positive rates for HPV testing in young unimmunized women have generated concerns regarding the clinical effectiveness of primary HPV screening in the population under the age of 30. Many countries are already in various stages of adopting HPV primary screening, whereas others have not taken any major steps towards introducing this approach.

The identification of HPV as the main etiologic agent for cervical cancer presented novel opportunities not only for secondary prevention, but also for the development of primary prevention through vaccination. The first vaccine that was approved was the quadrivalent Gardasil/Silgard, which targets HPV 6, 11, 16, and 18. A year later, the bivalent Cervarix vaccine targeting HPV 16 and 18 was approved, and more recently, the nonavalent Gardasil 9 vaccine, which targets HPV6, 11, 16, 18, 31, 33, 45, 52, and 58 was also given the green light.

All three of these vaccines contain HPV L1 protein virus-like particles expressed in different cell types. These protein virus-like particles carry no viral material, thus being noninfectious, but they are capable of inducing an effective immune response with the induction of neutralizing antibodies that can block new HPV infection. The quadrivalent and nonavalent vaccines contain virus-like particles of two low-risk HPV types, 6 and 11, which are responsible for more than 90% of anogenital warts and laryngeal papillomas. Moreover, the nonavalent vaccine is targeted against the five types (HPV31, 33, 45, 52, 58) most frequently identified in cervical cancer after HPV16 and 18 (*Brotherton, Bloem, 2017*). The virus-like

particles are morphologically and antigenically similar to native HPV virions, and because of the genomic similarity between different types of the virus, a certain degree of protection against HPV types not targeted by the vaccine, so called cross-protection, is also achieved. But even with this cross-protection, it is important to understand that HPV vaccines do not protect against all HPV types that cause cervical cancer. This is why secondary prevention through screening is still mandatory for adequate cervical cancer protection. The effective integration of HPV vaccine programs with HPV-based testing via screening programs has the potential to virtually eliminate the burden of cervical cancer in every country of the world before the end of this century (*Bray et al., 2018*). In a study evaluating the effectiveness and cost-effectiveness of cervical cancer prevention scenarios, the most cost-effective strategy was the combination of preadolescent vaccination followed by screening using primary HPV testing every five years, with cytology triage (*Georgalis et al., 2016*).

Within this direction of study concerning primary and secondary prevention for cervical cancer, I implemented a research internal grant awarded by the “Grigore T. Popa” University of Medicine and Pharmacy Iasi, and I published several original research articles.

Research grant:

“First effects of HPV vaccination in Romania- a cross-sectional study in the Northeastern part of the country“ Nr. 30883/30.12.2014 (internal grant UMF Grigore T Popa Iasi).

Published papers:

1. **Grigore M**, Teleman SI, Pristavu A, Matei M. Awareness and knowledge about HPV and HPV vaccine among romanian women. *J Cancer Educ* 2018; 33:154-159. **IF-1,547**
➤ awarded in the **UEFISCDI** competition “Premierea Rezultatelor 2018” PN-III-P1-1.1-PRECISI-2018-26012
2. **Grigore M**, Matei M, Pristavu A, Teleman I. HPV and HPV vaccine knowledge among HPV-vaccinated women in North-eastern Romania, *Eur J Gynaecol Oncol* 2018; 3:395-398. **IF- 0,64**
3. **Grigore M**, Matei M, Pristavu A, Jitaru D, Teleman I. Prevalence of HPV and genotype distribution in “catch-up” HPV vaccinated women. *Eur J Gynecol Oncol* 2018; 5:760-763, **IF-0,64**
4. Păvăleanu I, Gafițanu D, Ioanid N, **Grigore M**. Preliminary results of the first cervical cancer screening programme in the North Eastern region of Romania. *J Med Screen* 2018; 25:162-165. **IF- 2,689**
➤ awarded in the **UEFISCDI** competition “Premierea Rezultatelor 2018” PN-III-P1-1.1- PRECISI-2018- 28900
5. **Grigore M**, Popovici R, Pristavu A, Grigore AM, Matei M, Gafitanu D. Perception and use of Pap smear screening among rural and urban women in Romania. *Eur J Public Health* 2017; 27:1084-1088. **IF 2,72**
➤ awarded in the **UEFISCDI** competition “Premierea Rezultatelor 2018” PN-III-P1-1.1-PRECISI-2018-22326

I.2.1.2. PRIMARY PREVENTION IN ROMANIA- THE IMPACT OF HPV VACCINATION

I.2.1.2.1. Introduction

Cervical cancer is a major epidemiological problem in Romania. For the last 30 years, Romania has had the highest cervical cancer mortality in Europe, with rates 6 times higher than the average cervical cancer mortality in other European Union countries. Cervical cancer is the third most common cause of cancer mortality among Romanian women, after breast cancer and colorectal cancer (*Ferlay et al., 2018*). Furthermore, the mortality rate has been increasing steadily during the last decades, and cervical cancer incidence rates have also risen from 15.7 cases per 100,000 in 1982 to 25.8 per 100,000 in 2018 (*Ferlay et al., 2018*). The number of new cases of cervical cancer reported in Romania in 2018 was 3.308 per 100,000 women (8.6% of all new cases of cancer).

HPV vaccination has the greatest potential to reduce the global burden of cervical cancer. Since 2006, two highly effective prophylactic HPV vaccines have been used to prevent infections with oncogenic HPV genotypes 16 and 18. Primary prevention by HPV vaccination for teens was introduced in 2008. However, the statistics from 2008 revealed that only 2.5% of the 110,000 eligible girls in the target group were vaccinated (*Craciun, Baban, 2012*). In 2009, a re-launching of the vaccination campaign was planned, targeting girls aged 12-14, and also a “catch-up” population of young women aged 16-26. The main barriers to vaccination were the fear of side effects, the perception of it being risky, and financial concerns. Some parents considered that the vaccine was an experiment serving the commercial interests of pharmaceutical companies. In the opinion of the parents, the pharmaceutical industry would “do and say anything in order to sell their products”. Their views illustrate the level of public mistrust regarding pharmaceutical products and especially vaccines. Moreover, the HPV vaccine made the subject of a conspiracy theory pointing to a strategy to reduce the world population by inducing infertility. This and the fact that the vaccine was made accessible free of charge strengthened the opinion of the parents that there were “hidden medical interests.” Ultimately, Romanian parents rejected the vaccine so widely that the national program for primary prevention was abandoned (*Craciun, Baban, 2012*). Such conspiracy theories are shared on discussion forums on the Internet, where most of the negative comments focus mostly on pseudo-scientific information and affect-based testimonials (*Penta, Baban, 2014*).

Considering that the time between an HPV infection and the clinical manifestation of cervical cancer is approximately 10 to 15 years, the effects of the HPV vaccine on cervical cancer incidence will not be observed for several decades. To evaluate the short-term impact of the vaccine, monitoring of HPV prevalence and genotype distribution in a population before and after vaccine introduction is essential (*Tota et al., 2011, Delere et al., 2014*). However, considering that most government-funded HPV immunization programs target only pre-teen girls, the short-term evaluation on the vaccination is difficult to achieve (*Tota et al., 2011*). The “catch-up” programs implemented successfully in some countries are notable exceptions to that, as they provide early evidence of positive impact. For example, Australia was the first country to introduce a fully funded national immunization program for

women up to the age of 26. As a result of high vaccine uptake in the “catch-up” age range, Australia was also the first country to report a significant decline in the rate of high-grade precancerous lesions (*Brotherton et al., 2011; Tabrizi et al., 2012*). Similarly, in Romania, a “catch-up” population of women 16-26 years old was also included in the vaccination campaign in 2009-2010. Because of the “catch-up” vaccination program, Romania was one of the few countries where it was possible to evaluate the short-term effects of the vaccination in terms of observing how the vaccine changed the prevalence or type of HPV infection in the population.

Because “catch-up” vaccination presented such great scientific interest and potential, in 2014 I applied for and won an internal grant in the content organized by the “Grigore T. Popa” U.M.Ph. Iasi. The grant was entitled **“First effects of HPV vaccination in Romania - a cross-sectional study in the Northeastern part of the country”** (Nr. 30883/30.12.2014). The main objective of the grant was to compare the prevalence of HPV infection between a non-vaccinated and a vaccinated population. We wanted to examine whether the vaccine contributed to a decrease in HPV prevalence and also if the vaccine changed the types of HPV infection. Another important objective was to appraise if HPV vaccination affected the sexual behavior of young women by conveying a false sense of security and promoting risky sexual behavior. This sort of “risk compensation” could result in an increase in other HPV genotypes not targeted by vaccination, as well as in other sexually transmitted infections. We pursued the subject by means of a questionnaire-based survey, which focused on several factors relevant to sexual behavior and HPV infections.

The implementation of the grant was facilitated by the collaboration between with three departments from our university: Obstetrics and Gynecology, Pathology and Biochemistry. This interdisciplinary effort results in the publication of three articles in journals with impact factor, and one oral presentation at an international congress. The first of these articles is also one of the first to assess awareness and knowledge about HPV and HPV vaccine among the Romanian population. This research provided a detailed picture of both rural and urban perspectives, which in our country are underpinned by significant educational and economic differences. In another article, we evaluated the knowledge of HPV vaccinated women regarding HPV. Because HPV vaccination in Romania had encountered such great resistance that the program initiated by the Ministry of Health had to be stopped, we wanted to investigate if (non-)acceptance was influenced by the educational background. The purpose of this study was to evaluate the knowledge and attitudes regarding the HPV, HPV vaccination, and cervical cancer among young women who took part in the HPV catch-up vaccination program. As far as we know, this was one of the first studies of its kind in Romania.

The ultimate goal of our study was to show the effectiveness of the vaccine by evaluating the prevalence of HPV infection in a group of HPV vaccinated women. Taking into account that the distribution of HPV can vary from one geographic region to another, we compared the distribution of HPV types among vaccinated and non-vaccinated women from the same area. The results of this study were published in another ISI journal.

Published papers:

1. **Grigore M**, Teleman SI, Pristavu A, Matei M. Awareness and knowledge about HPV and HPV vaccine among romanian women. *J Cancer Educ* 2018; 33:154-159. **IF-1,547**
 - a. awarded in the **UEFISCDI** competition “Premierea Rezultatelor 2018” PN-III-P1-1.1-PRECISI-2018-26012
2. **Grigore M**, Matei M, Pristavu A, Teleman I. HPV and HPV vaccine knowledge among HPV-vaccinated women in North-eastern Romania, *Eur J Gynaecol Oncol* 2018; 3:395-398. **IF- 0,64**
3. **Grigore M**, Matei M, Pristavu A, Jitaru D, Teleman I. Prevalence of HPV and genotype distribution in “catch-up” HPV vaccinated women. *Eur J Gynecol Oncol* 2018; 5:760-763. **IF-0,64**

I.2.1.2.2. Material and methods

- ***Awareness and knowledge about HPV and HPV vaccine among Romanian women***

This was a cross-sectional study conducted among 454 women from rural and urban area during a period from April to July 2015. In rural areas the women completed the questionnaire at a general practitioner’s office, and in urban areas in a gynaecologist’s office. Written consent was obtained from all the participants, after they were informed about the study. The questionnaire consisted of questions grouped in four parts: 1. Socio-demographic and socioeconomic factors like age, marital status, level of education, number of children, income - 6 questions; 2. Awareness and knowledge about HPV infection -16 questions; 3. Awareness and attitude about HPV vaccine - 11 questions; 4. Sources for information - 2 questions. The questionnaire was pretested on 20 women before being used in the main study in order to assess the clarity of the questions.

- ***HPV and HPV vaccine knowledge among HPV-vaccinated women in North-eastern Romania***

This cross-sectional study was conducted among 120 HPV-vaccinated women from rural and urban areas during a period from October 2015 to January 2016. Participants were interviewed using a standard questionnaire. Through this survey, the participants offered their knowledge and opinions regarding HPV, the connection between HPV and cervical cancer, and the HPV vaccination. The questionnaire consisted of 4 questions: (1) Socio-demographic and socio-economic factors like age, marital status, level of education, number of children, income; (2) Awareness and knowledge about HPV infection; (3) Awareness and knowledge attitude about the HPV vaccine; and (4) Sources for information. The questionnaire was pretested on 20 women before the study was conducted in order to assess the clarity of the questions.

- ***Prevalence of HPV and genotype distribution in “catch-up” HPV vaccinated women***

We performed a cross-sectional study in the North Eastern region of Romania. We recruited 147 women, which were vaccinated through “catch-up vaccination” in 2010-2011. Each woman completed a questionnaire concerning possible cofactors for cervical cancer (e.g. smoking, genital co-infections, oral contraceptive use, number of sexual partners). The participants were examined and evaluated for the presence of genital warts, and HPV sample was collected. The gynecologist collected cervical cells in PCR Cell Collection (HPV-SCK code 03-33, ABANALITICA) from all the women, and then kept at 4°C till processing (1-7 days). DNA extraction has been made with QuickGene DNA tissue kit S in the first 15 days after the samples were collected. Specimens were analyzed using a general primer based polymerase chain reaction (PCR) and genotyped for 16 high-risk and low-risk HPV- strains by Sacace Biotechnologies -based multiplexed genotyping. The technique was validated through the use of positive and negative controls (primers against β -globine gene) at each shift. The controls are necessary in order to find out if the swab is prepared correctly, as an amplification control for each individually processed specimen and to identify possible reaction inhibition. All women with HPV/ADN positive test had a Papanicolau smear and a colposcopy.

I.2.1.2.3. Results

- ***Awareness and knowledge Aabout HPV and HPV vaccine among Romanian women***

Socio-demographic characteristics

454 women were included in the study. The mean age of the study population was 33.4 years (33.4 +/- 7.8). 212 (46.7%) participants were from rural area and 242 (53.3%) from urban area. The main socio-demographic characteristics are presented in table 1.

Table 1 Socio-Demographic Characteristic of the Participants

Variable	Number	%
Marital status		
Single	75	16.5
Married	349	76.9
Concubinage	15	3.3
Divorced	9	2.0
Widow	6	1.3
Education Level		
Primary	189	41.6
Secondary	153	33.7
University degree	112	24.7
Number of children		
No children	162	35.7
1	118	26.0
2-3	146	32.2
>3	28	6.2
Occupation		
Employee	228	50.2

Student	21	4.6
Retired	4	0.9
Social aid	22	4.8
Without occupation	179	39.4

HPV awareness and knowledge

Participants were asked if they had heard about HPV. 314 (69.2%) of them declared that they heard about HPV. 249 women (54.8%) reported that HPV is transmitted through sexual intercourse and 243 women (53.5%) reported that HPV is one of the causes of cervical cancer among women. Regarding genital warts, 120 participants (26.4%) reported that HPV could be the cause of them. 209 (46%) participants declared that multiple sexual partners represent a risk for HPV infection. Risk factors for HPV transmission were known in different proportion: multiple sexual partners – 209 (46%), non-use of condoms - 130 women (28.6%), early onset of sexual life - 43 (9.5%), multiple male partners - 5 (1.1%).

HPV vaccination

74.2% of women were positive about the vaccination practice in general (no matter the type of vaccine) and 62.3% of the participants had heard about the HPV vaccine. Only 50.7% of the responders agreed with HPV vaccination. The reasons for rejecting HPV vaccine are given in table 2. The main barriers against HPV were: fear of side effects (55.8%) and the impression that there is “no need because no active sexual life” (13.2%). Other reason included financial concerns (4.6%), fear of needles (3%), lack of time (2%), not knowing where the vaccine is available (8.1%), or different unspecified reasons.

Source of information

Participants’ sources of information about HPV were healthcare providers (29.7%), internet (23%) and television (17%). More than 20% of subjects have used multiple sources for information.

- ***HPV and HPV vaccine knowledge among HPV-vaccinated women in North-eastern Romania***

Socio-demographic characteristics

The study included 120 women. The mean age of the study population was 24 years (32.35 ± 12.78); 97 was < 35 years of age and 23 were ≥ 35 years of age. 98 participants were from urban areas and 22 from rural areas. The principal socio-demographic characteristics are presented in table 2.

Table 2. Socio-Demographic Characteristic of the Participants

Variable	Number	%
Age		
17-25	32	26.6
25-35	65	54.2
over 35	23	19.2

Marital status		
Single	40	33.3
Married	63	52.5
Concubinage	10	8.3
Divorced	7	5.8
Education Level		
Primary	10	8.3
Secondary	21	17.5
University degree	89	74.2
Number of children		
No children	60	50
1	39	32.5
2-3	20	16.6
>3	1	0.8
Occupation		
Employee	81	67.5
Student	11	9.2
Social aid	4	3.3
Without occupation	24	20

HPV awareness and knowledge

Participants were asked if they have knowledge regarding HPV; 115 (95.8%) declared that they had heard about HPV. 98 women (81.6%) reported that HPV is transmitted through sexual intercourse, and 100 women (83.3%) reported that HPV is one of the causes of cervical cancer among women. Regarding genital warts, 25 participants (20.8%) reported that HPV could be the cause of the warts. 82 (68.3%) women knew about the asymptomatic nature of HPV infection.

Risk factors for HPV transmission were known in different proportions: multiple sexual partners 76 women (63.3%), not using condoms 56 (46.6%), early onset of sexual activity 21 (17.5%), and multiple partners of the male partner 48 (40%).

HPV vaccination

102 of the women (85%) were in general positive about receiving the vaccination. The main reasons for accepting or demanding the HPV vaccination were:

- 18 Protection against cervical cancer - 97 women
- 19 Having a relative or close friend diagnosed with cervical cancer - 23 women
- 20 Advice from healthcare professionals - 45 women

More than half (67.5%) of the women did not know the target population or the precise recommended ages for vaccination (although most responses such as “young women” and “adolescents” were broadly correct). In the opinion of 65 (54.1%) of the participants, no other screening methods are necessary after vaccination.

Source of information

Participants source of information about HPV were healthcare providers (31.3%), Internet (33%), and television (11%). The number of sources listed was multiple in more than 20% of cases.

- ***Prevalence of HPV and genotype distribution in “catch-up” HPV vaccinated women***

The mean age of the study population was 34.08 years (21-49 years old); 16

women (10.88%) were aged under 25 years, 68 (46.25%) between 25 and 35 and 63 (42.85%) over 35 years old. 113 participants (76.87%) were from urban area and 34(23.12%) from rural area. The great majority of women (81.60%) received the quadrivalent vaccine, while the rest received the bivalent vaccine. Because HPV test was not covered by medical insurance it was not performed before vaccination. The time between vaccination and our study was between 5 and 6 years.

The following prevalence of HPV/DNA was identified in our study: out of the total 147 tested samples, 19 samples (12.92%) were positive for HPV/DNA. 11 samples (7.48 %) were single HPV type infections and 8 samples (5.44%) tested positive for multiple HPV types. Multiple infections were produced by two genotypes per sample in 6 cases (4.08 %) or three genotypes per sample in two cases. Multiple infections were only with HR types in 7 cases (4.76 %) or a combination of LR types and HR types in one case (0.68%). The distribution of HPV types is presented in table 2. All positive cases had at least one HR genotype. The most frequent was 16, followed by 35, 56, 31, 59, 33, 45 and 52. (Table 3).

Table 3- The distribution of HPV genotypes

HPV type	Genotype risk	Frequency	Percent (%)
Negative		128	87.07
16	HR	7	4.76
35	HR	5	3.40
56	HR	4	2.72
31	HR	3	2.04
59	HR	3	2.04
33	HR	2	1.36
45	HR	2	1.36
52	HR	1	0.68
11	LR	1	0.68
6	LR	1	0.68

HR= high-risk, LR=low-risk types

The distribution of HPV infections according to the age groups was: under 24 years age 3 cases, 25-34 year old age 8 cases, over 35 years 8 of cases (Table 4).

Table 4. Positivity rates of HR-HPV, and LR-HPV stratified for age groups among women with human papillomavirus.

Age group (years)	HPV positive test	HR-HPV	LR-HPV
< 24	3 cases	3 cases	0

25-35	8 cases	3 cases	1
> 35	8 cases	8 cases	0
Total	19 cases	19 cases	1

HR- high-risk, LR- low-risk

We have correlated the presence of HPV with risk factors for HPV infections and cervical cancer: use of oral contraception, smoking, early onset of sexual activity, multiple sexual partners. Of all 19 HR HPV positive women, 4 (21.05%) declared the use of oral contraceptive, 8 (42.10%) reported cigarette smoking and 6 (31.57%) reported more than 3 sexual partners. Of all 128 the DNA/HPV negative women, 25 (19.53 %) declared the use of oral contraceptives, 28 (21.87%) reported cigarette smoking and 30 (23.43%) reported more than 3 sexual partners.

During clinical examination only in one case genital warts were present and in this case both types 6 and 11 were present, the patient being vaccinated with bivalent vaccine. We identified the following Pap smears results among women with HPV infection: inflammatory 6 cases (31.57%), ASCUS- 5 cases (26.31%), LSIL- 2 cases (10.52%), HSIL- 1 case (5.26%). In 5/19 (26.31%) cases positive for HR HPV, the result of conventional smear was reported as “normal”(Table 5). In 2 cases colposcopy and biopsy confirmed a CIN I lesion and in one case a CIN II lesion.

Table 5. Pap smear results among women with HPV positive tests

Pap smear results	Single infection	Multiple infection	HR-HPV	LR-HPV
Inflammatory	4	2	6	0
ASCUS	2	3	5	1
LSIL	0	2	2	0
HSIL	0	1	1	0
Normal	5	0	5	0
Total	11 cases	8 cases	19 cases	1

I.2.1.2.4. Discussion

- *Awareness and knowledge about HPV and HPV vaccine among Romanian women*

The study found a good awareness of HPV and HPV vaccine among the participants. 69.2%, respectively 62.3% of the women declared that they heard about HPV and HPV vaccine. The awareness regarding HPV was slightly greater in urban women than in rural women. The level of HPV awareness is very heterogeneous in the literature: various reports showed very different degrees of awareness and knowledge among the general population or specific target groups. In some studies there are good levels of awareness, while other studies revealed a low level of awareness (Jain *et al.*, 2009; Christian, Christian & Hopenhayn, 2009). In Romania a possible reason for this good level of awareness could be due to the vaccination campaign organized by the Ministry of Health. Even if this campaign proved to be a failure, there has been a lot of public debate, both in the press and on TV, which could be a possible reason for the high level of awareness we found regarding HPV and HPV vaccine.

Deficiencies in knowledge were noted for vaccine, genital warts or risks

factors for HPV infection (like early onset of sexual contact). More than a half (68%) of the women did not know the target population or the precise recommended ages for vaccination (although most responses such as “young women” and “adolescents” were broadly correct). Regarding genital warts only 26.4% of the participants know that they are HPV related disease. These data are in accordance with the metaanalysis of Coles who showed that knowledge surrounding HPV and genital warts was generally poor (Coles *et al.*, 2015). In our study, the knowledge gaps about HPV related diseases occur among participants with higher educational level as well as lower ones. Also we had no significant difference between rural and urban area. These knowledge gaps will require educational programs in both rural and urban areas. There are many possible ways to educate population regarding HPV and HPV related diseases.

Another important aspect, which we tried to cover, was the information and attitude toward the HPV vaccine. Unfortunately, the first attempt of campaign vaccination in Romania has failed. Our study revealed that 62.3% of the participants heard about HPV vaccine and only 50.7% would agree to HPV vaccination. The main reasons for not vaccinating their daughters were the perception that the vaccine is risky, the belief that the vaccine represents an experiment that uses their daughters as guinea pigs, the belief that the vaccine embodies a conspiracy theory that aims to reduce the world’s population and general mistrust in the ineffective health system. People felt they have unclear information about: the mechanism through which the vaccine works; the efficacy of the vaccine, safety and side effects; and the schedule through which it is applied. Mothers stated they would need clear, factual information about the HPV vaccine and its link to cervical cancer in order to motivate them to accept it for their daughters (Craciun, Baban, 2012). Our study revealed that the same belief that the “vaccine is risky” still persist among women even after a few good years after the HPV campaign was introduced in Romania. Lack of knowledge about HPV may make it difficult for women to make appropriate decisions. Therefore clear and sustained educational programs may be needed in both rural and urban areas before starting a new vaccination campaign. Regarding the source of information and trust, the participants stated that healthcare professionals along with television and Internet provided most of the information. The problem is that the Internet does not always provide the most accurate information.

Some possible explanations for the lack of information about HPV and HPV vaccine, which were identified after the discussion group during the “Latest updates on Colposcopy, HPV diseases and Cervical cancer” Workshop, were the following: the education campaign for healthcare professionals was insufficient; professionals did not transmit the information and knowledge further to population, parents, and educators (in school); there is still an important need for knowledge for all involved in the process of cervical cancer prevention, whatever their role; there are still questions that demand an answer, like: “*Do you think that there was enough research about safety of this vaccine?*”; “*After the vaccination, my daughter will never develop cervical cancer?*”; or “*My 12 year old vaccinated daughter will be protected after 5-6 years when she will start her sex life?*”.

Another issue targeted by the discussion group at the Workshop was related to “Suggestions for improving HPV vaccine knowledge and acceptance”. The proposed measures to improve HPV vaccination rates through a high level of HPV vaccine knowledge and acceptance were the following: Continuing Medical Education courses for healthcare professionals (doctors, nurses etc.) and involvement of mass media in HPV education campaign for the general population. A very important point

is to give the appropriate and correct information in order to raise the awareness and the responsibility among all those involved (healthcare professionals, educators, population, parents, girls, boys, mass media, and decision making factors). Medical doctors thought that an important role in education has to be for rural area, which is disadvantaged in a number of ways that may affect health education. However, our study suggests that there is little difference between rural and urban women with regard to HPV infections and vaccine. There is evidence that raising public awareness and knowledge are important tasks in Romania. Without proper communication vaccines can have little impact in reducing incidence of HPV infections and cervical cancer. Education on HPV should include information regarding safety and efficacy. Thus, an education campaign, which includes patient education, is necessary to improve attitudes towards and acceptability of the vaccine.

Limitations of the study include the fact that the sample was not representative of the general Romanian population because recruitment was limited to one region of the country. Our results are relevant for the North Eastern part of Romania and are helpful for the Public Health Authorities from this region, but could be a support for other regions to start the research of the level of knowledge among their specific population. The study included only non-vaccinated women (probably related to the failure of the national campaign), which was unintended because this was not an exclusion criterion in our current research. The level of knowledge among vaccinated women is being studied and will be published separately. It is possible that among vaccinated population the level of knowledge to be superior to the values found in the current study. Another limitation is represented by the fact that uninsured population (with no access to GP or gynaecologist) was not included in the study. We will develop a future extended research taken into account all the limitations we found in this current study.

Our study reports a good level of awareness but a low level of knowledge and limited positive attitude toward vaccination with HPV. More educational programs and clearer communications are needed to raise awareness and knowledge regarding HPV and HPV vaccine. There is a need for a multidirectional education campaign and those who are directly involved in the development of cervical cancer prevention strategies should promote and support such a cost-efficient measure of primary prevention, which is also a helper for the success of the other primary preventive measure - HPV vaccination.

In the same year when we published our paper, a study on the HPV vaccine and attitudes among parents of children aged 10-14 years was carried out in the central part of our country and was subsequently published (*Voidazan et al., 2016*). This study showed the average level of knowledge about HPV infection and HPV vaccination in central Romania. The authors pointed to parents, healthcare providers, and teachers as the key decision-makers who can influence the acceptance of HPV vaccination and behavior of young people towards the prevention of HPV infection. The ratio of parents who would have their daughters vaccinated was low (about one third) and the main reasons for refusing vaccination were fear of side effects and unclear information provided by people involved. The authors affirmed the important role of the healthcare practitioner in raising vaccine acceptance rates, as we did based on our research. These studies highlight the need for proper involvement of general practitioners in matters of health education, and the evidence should be taken into account before implementing any new programs for HPV vaccination in Romania. Such programs could incorporate educational strategies aiming to provide clear and transparent information on the advantages and disadvantages of HPV vaccination.

Healthcare professionals should be trained to use appropriate communication strategies that can help reduce the fear of side effects and increase confidence in vaccination among parents.

The results of our study regarding the importance of healthcare professionals in achieving vaccination goals is confirmed by numerous international studies, many of them published recently in New Zealand and UK (*Sherman et al., 2018, Sherman et al., 2019*). Although the level of education among healthcare professionals regarding HPV and vaccination overall is adequate in these countries there are still knowledge gaps. More training is required to ensure that misinformation and stigma do not inadvertently result from interactions between health professionals and the public. Furthermore, all healthcare practitioners should be adequately informed since further changes to the screening program are due to be implemented worldwide (shifting from Pap smear to HPV testing). Although HPV infection is the most common, it is not the only causative agent of cervical cancer. There are other demographic and behavioral co-factors that increase the relative risk, such as: low education level, early start of sexual life, multiple sexual partners, long-term use of oral contraceptives, personal history of sexual transmitted diseases, presence of genital warts. To encourage higher HPV vaccine uptake, the general population requires accurate information about the usefulness of the vaccine in preventing HPV infection and healthcare professionals should raise women's awareness regarding all these factors concurrently with educating them about HPV.

Therefore, physicians play an important role in health promotion via the provision of correct, complete and comprehensible information. In addition, other healthcare workers such as midwives and nurses must be adequately trained in order to offer, depending on their role, appropriate information consistent with maximizing adherence to vaccination. As such, they are an important population whose level of knowledge, attitudes and behavior regarding HPV infection and related vaccination should be studied, especially in light of pending updates to current screening practices.

- ***HPV and HPV vaccine knowledge among HPV-vaccinated women in North-eastern Romania***

The study found a good awareness of HPV among the participants. From 120 vaccinated women, 115 had heard about the virus. The studies from the literature show very different grades of awareness and knowledge among the general population or specific target groups. In a Danish study, 10% of the participants reported to have heard of HPV and Maier stated that 20.22% of adolescents in Romania had heard about HPV (*Nielsen et al., 2009; Maier et al., 2015*). In our study, the high level of awareness regarding HPV among vaccinated women could be explained by the information received before vaccination from the health practitioner and from the vaccination campaign organized by the Minister of Health. Another possible explanation could be the high educational level of the vaccinated women, (74.1 % them had received higher education or students at the time of vaccination were enrolled in higher education). Also an important percentage of the vaccinated women from our study were healthcare employees with a good level of information in the domain of health. Most women were aware that HPV is a sexually transmitted disease, and 98 of the participants (81.6%) declared that they knew that HPV could be sexually acquired.

Our study found a good awareness regarding the relationship between HPV

and cervical cancer (83.3%). This good level of knowledge of the connection between HPV and cervical cancer can be explained by the fact that the vaccine was promoted as a cervical cancer vaccine.

Deficiencies in knowledge were noted for risk factors for HPV infection such as early onset of sexual activity. A relatively low number of our participants (20.8%) were aware of the relationship between HPV and genital warts. This could be explained by the fact that basically the vaccine was promoted primarily for use against cervical cancer.

The information regarding HPV vaccine focused on two main problems: knowledge regarding the benefits of HPV vaccination and factors that convinced the women to be vaccinated. More than half (67.5%) of the women did not know the target population or the precise recommended ages for vaccination (although most responses such as “young women” and “adolescents” were broadly correct). More than half of the vaccinated women believed that after vaccination no other screening methods are necessary. From this perspective, it is important to correctly educate the women before and after vaccination. It is important to explain that screening for cervical cancer should not be interrupted, although it is possible that the vaccination will change the mode of the screening in the future.

The main reason for requiring or accepting the vaccination was knowledge of the relationship between HPV and cervical cancer. 87% of the vaccinated women knew the relation between HPV and cervical cancer, and this was one of the principal reasons for accepting the vaccination. Another important factor for requiring vaccination (even though not reimbursed by the government) was the presence in the family or a close relation diagnosed (or even dead) with cervical cancer.

Regarding the source of information and trust, the participants declared that healthcare professionals along with television and the Internet provided most of the information. Healthcare professionals played an important role in women making the decision to receive the vaccination.

Before launching a new HPV vaccination program, it will be crucial to establish good and proper communication between health professionals and the media. Our study shows that general practitioners and gynaecologists play an important role in women making the decision to receive the vaccination. At the same time, they should provide correct information regarding the benefits but also limitations of the vaccination. As we saw, there is a false belief among vaccinated women that the vaccine provides full protection against cervical cancer and that no cervical screening is necessary after one is vaccinated.

Limitations of the study include the fact that the sample was not representative of the general Romanian population, because recruitment was limited to one region of the country. It will be beneficial to explore other parts of the country to identify factors that played an important role in the decision regarding HPV vaccination.

In conclusion our study discovered a good level of awareness about HPV and a positive attitude toward vaccination among HPV-vaccinated women. An important role in accepting the vaccination was played by healthcare professionals. Improving communication between health officials and the mass media might represent a useful strategy if a re-launching of the HPV vaccination campaign will take place in the future.

The results of our research are confirmed by several recent studies. The direct correlation between education level and vaccine acceptance has already been reported in the literature (*Kisaakye et al., 2018, Liu et al., 2019, Kops et al., 2019*). *Kisaakye et al* surveyed 460 female adolescents in Uganda and assessed the level of their HPV

vaccine uptake as low as 17.61%. Uganda has one of the highest rates of cervical cancer incidence globally, with an age-standardized incidence rate of 47.5 per 100,000. Therefore, the success of the vaccination program is highly important. In this study, the main factors associated with vaccine acceptance: secondary education level, positive attitude towards the vaccine, receiving vaccine doses from more than one site, and encouragement from Health workers and Village Health Teams. Other factors associated with the uptake of HPV vaccine included: participating in community outreaches, availability of vaccines and receiving full information about the vaccine. In order to improve the uptake of vaccination, the authors proposed several methods: a consistent supply of vaccines at the vaccination sites, health education aimed at creating a positive attitude towards the vaccine, sensitization of the adolescents about the vaccine, and conducting community outreaches (*Kisaakye et al., 2018*).

In another part of the world, Liu et al. investigated the baseline knowledge on cervical cancer and HPV among junior high middle school students from Chengdu, China, and their willingness towards HPV vaccines. The study showed that little is known about the knowledge and attitudes towards HPV (and its vaccines) among adolescents in mainland China, which could be a potential barrier to the promotion of HPV vaccination throughout this vast country. Among the 1 675 students surveyed, only 34.3% had heard of cervical cancer/genital warts, while only 15.1% of them had ever heard of HPV. However, 55.2% of students showed willingness to be vaccinated even before any intervention. School-based health education is effective and appropriate in increasing the awareness of HPV and willingness towards its vaccines. Regular health education on HPV and cervical cancer prevention at a shorter interval should be guaranteed to ensure continuous effectiveness (*Liu et al., 2019*).

Kops et al. performed a cross-sectional, multicenter study in Brasil, among 8,581 sexually active young adults recruited from 119 primary care units between 2016 and 2017. All participants answered a face-to-face standardized questionnaire. The mean percentage of correct answers about HPV and vaccination was 51.79% (95% CI 50.90-52.67), but 75.91% (95% CI 74.13-77.69) demonstrated awareness of the HPV vaccination. Women answered a higher proportion of questions correctly than men did ($p=0.0003$). A lower education level was the variable that most interfered with accurate knowledge (*Kops et al., 2019*). The best information sources were both health professionals and the media (1.33%, 95% CI 1.03-1.70).

All these recent results point to the same conclusion that we reached through our research in Romania: there is a direct correlation between level of education and acceptability of HPV vaccination. This underlines the importance of educational interventions in the population, especially among the socially disadvantaged groups, in order to provide adequate information about the virus and available vaccination.

- ***Prevalence of HPV and genotype distribution in “catch-up” HPV vaccinated women***

Vaccination is among the most successful and less costly of all public health interventions. The geographic area where we performed our study has a population of 4.5 million people. In this geographic region, two studies regarding incidence and distribution of HPV types were performed, both on non-vaccinated population. Both studies report high prevalence of HPV in a non-vaccinated population, HPV 16 being the most prevalent. In both studies genotype 18 had a low prevalence and this could represent a particularity of genotype distribution in this geographic area (*Socolov et*

al., 2008; Ursu *et al.*, 2011). In our study, performed in the same geographic region among vaccinated women, the overall prevalence of HPV-HR was 12.92% and the most frequent types encountered were: genotype 16, followed by 35, 56, 31, 59, 33, 45 and 52. Among the participants from our study, HPV genotype 16 and 18 prevalence was significantly lower in vaccinated than in non-vaccinated women of the same geographic area. These findings are in line with recently published studies from Australia and the US (Brotherton *et al.*, 2011). The presence of genotypes 16 among vaccinated women in our study is likely due to the fact that most vaccinated women received the vaccine after sexual onset and in many cases an HPV test before vaccination was not performed. Thus, it is possible that in some cases the infection with HPV types included in the vaccine to be present at the moment of immunization and explain the prevalence of types 16 after immunization. These findings support the recommendation to vaccinate early in adolescence and before sexual onset. It is thus important to promote vaccination at an age when the vaccine is most effective immunologically and when uptake is likely to be high.

No patient in our study had clinical vulvo-vaginal neoplasia or condyloma. 87% of the women in our study were vaccinated with quadrivalent vaccine, which offer immunization for low-risk types responsible for genital warts. We found that prophylactic HPV vaccination had a good efficacy against vulvovaginal neoplasia and condyloma attributed to HPV types 6, 11 at least 4 years after immunization. This confirms the results of previous studies with shorter follow-up times and provides evidence of longer duration of protection with no signs of waning protection.

Consistent with other data, a higher number of lifetime sexual partners are an independent risk factor for HPV infection. In our study 31.57% from HPV positive women declared more than 3 sexual partners in comparison with 23.43% of the negative HPV women. Several studies demonstrated that smoking interferes in the increase of HPV infection prevalence and in an increased risk of CIN and cervical carcinoma (Mzarico *et al.*, 2015). In our study the percentage of active smokers was greater in HPV positive women in comparison with HPV negative women. In addition, a lower educational status is associated with a higher HPV prevalence.

Our study confirms that vaccination will ultimately change the natural history of HPV disease by reducing the influence of the highly oncogenic types HPV 16 and 18 not only in girls vaccinated before sexual onset but also in “catch-up” vaccinated group. However, even if a level of cross protection against other genotypes is proved, the immunization alone cannot completely prevent cervical cancer. Although the vaccination decreases the prevalence of HPV, HPV infection is still present in vaccinated population and screening is still necessary.

Some limitations of our study need to be mentioned. Before “catch-up” vaccination in our country not all women had an HPV test and it is possible that some of the participants already had the infection at that time. Because low educated women were underrepresented in our study it would be interesting in the future to study a more heterogeneous group.

The study provides a useful baseline HPV prevalence estimate shortly after the introduction of prophylactic HPV vaccination in Romania. The results showed a decrease in HPV prevalence 16/18 among vaccinated women through “catch-up” vaccination, suggesting good effects of previous immunization campaign. These finding enhance the usefulness of catch-up vaccination but reinforce the recommendation to vaccinate girls in early adolescence and before sexual debut when vaccine is immunologically most effective and when uptake is likely to be high.

Several studies published in recent years reported results consistent with ours (Carozzi *et al.*, 2018, Ährlund-Richter *et al.*, 2019, Wei *et al.*, 2019). Carozzi F *et al.* evaluated HPV prevalence in vaccinated and unvaccinated women 5-7 years post-vaccination, since the program implementation in Basilicata (Italy) in 2007. Overall, 2,793 women (18-50 years old) were included, 1 314 of them having been in birth cohorts eligible for the HPV vaccination program (18- to 30-year-old women upon enrolment). Among the latter, quadrivalent HPV vaccine uptake was 59% (at least one dose), with 94% completing the vaccination schedule; standardized quadrivalent HPV type prevalence was 0.6% in vaccinated versus 5.5% in unvaccinated women ($P < 0.001$). This study provided a preliminary evaluation of the potential effect of the qHPV vaccination program in Basilicata, showing that it significantly reduced the prevalence of those HPV types included in the qHPV vaccine in vaccinated populations in a real-life setting, compared with the prevalence in unvaccinated women. These results, conducted in a post-vaccine era, suggest high vaccine effectiveness and justify the authors' conclusion that a well-implemented catch-up vaccination program may be efficient in reducing vaccine-type infections in a real-world setting. No cross-protective effect or evidence of type-replacement was observed a few years after HPV vaccine introduction (Carozzi *et al.*, 2018).

In 2019, Ährlund-Richter *et al.* published a paper regarding the impact of HPV catch-up and vaccination on the very high cervical HPV-prevalence in women at a youth clinic in central Stockholm during the period 2008-2018. A total of 178 cervical swabs from women aged 15-23 were tested for 27 HPV types by a bead-based multiplex method. HPV-prevalence data were then related to vaccination status and age and compared to HPV-prevalence in 615 samples from 2008 to 2010 and another 338 samples from 2013 to 2015 from the same clinic, as well as to HPV types in 143 cervical cancer cases recorded during 2003-2008 in Stockholm. The prevalence of all 27 HPVs – all high-risk HPVs (HR-HPVs) – and the combined presence of the quadrivalent-vaccine types of HPV (16, 18, 6, and 11) was lower in vaccinated compared to unvaccinated women (67.4 vs. 93.3%, $p = 0.0031$, 60.1 vs. 86.7%, $p = 0.0057$, and 5.8 vs. 26.7%, $p = 0.002$, respectively). In both vaccinated and non-vaccinated women, the most common non-quadrivalent vaccine HR-HPV types were HPV 39, 51, 52, 56, and 59. Together, they accounted for around 9.8% of cervical cancer cases in Stockholm during 2003-2008, and their prevalence tended to increase during 2017-2018 compared to 2008-2010. The result of this study showed that Quadrivalent-Gardasil® vaccination significantly decreased HPV-vaccine type prevalence. However, non-vaccine HR-HPV types remain common in potentially high-risk women according to the records of the youth clinic in Stockholm (Ährlund-Richter *et al.*, 2019).

Wei *et al.* conducted a randomized, double blind, placebo-controlled, multicenter, Phase 3 study evaluating the efficacy of the quadrivalent HPV vaccine for up to 6.5 years after the first administration to Chinese women 20-45 years of age. Of the 3 006 randomized participants, 2 759 (91.8%) and 2 374 (79%) completed the Month 30 and Month 78 visits, respectively. The efficacy in the PPE population against 6-month and 12-month persistent cervical infection was 91.6% (95% CI: 66.0, 99.0) and 97.5% (95% CI: 85.1, 99.9) at Month 30 and Month 78, respectively. The vaccine also reduced the rate of cervical cytology abnormalities associated with HPV6/11/16/18, with an efficacy of 94.0% (95% CI: 81.5, 98.8). One conclusion of the study was that the vaccine was generally well tolerated (reported separately). Also, the qHPV vaccine was proven effective against endpoints of persistent infection

and genital precancerous lesions in Chinese women aged 20-45 years (*Wei et al., 2019*).

All these recent data reported in the literature, together with the results from our study, emphasize the importance of HPV-vaccination and show that high vaccine coverage prevents HPV infection, especially of the four quadrivalent-Gardasil HPV types, and has the potential to prevent a considerable share of HPV-related diseases. e.g. cervical cancer. The recent introduction of the nonavalent vaccine is likely to decrease the prevalence of HPV infection further and, consequently, that of cervical cancer or others HPV-related diseases as well. Vaccination is expected to reduce the prevalence of HPV vaccine types, but there is a theoretical concern that vaccine introduction may affect the distribution of other oncogenic types and induce type-replacement. Ongoing monitoring of the incidence of cervical pre-cancerous lesions and cancers, as well as of other HPV-related lesions such as anal and oropharyngeal cancers will be essential in appraising the overall benefits and cost-effectiveness of HPV vaccines in terms of cancer prevention.

I.2.1.3. SECONDARY PREVENTION IN ROMANIA- THE ROLE OF CERVICAL SCREENING

I.2.1.3.1. Introduction

As mentioned previously, cervical cancer is a major epidemiological problem in Romania. Statistics from 2018 showed that cervical cancer incidence rates have risen from 15.7 cases per 100,000 in 1982 to 25.8 per 100,000 in 2018 (*Ferlay et al., 2018*). Cervical cancer is the third most common cause of cancer mortality among Romanian women, after breast cancer and colorectal cancer (*Ferlay et al., 2018*). The number of new cases of cervical cancer reported in Romania in 2018 was 3,308 (8.6% from all new cases of cancer). Most cases are diagnosed in the advanced stages of the disease because of the lack of organized screening opportunities. In order to decrease cervical cancer incidence and mortality, several measures should be taken: increasing women's level of awareness and knowledge about cervical cancer, providing high-sensitivity screening (since some women may not have opportunities for repeated screening), screening all women aged 35–50 at least once before expanding services and providing repeated screening (e.g. once in every 10 years), treating women with high-grade dysplasia and cancer, as well as auditing the program and evaluating the outcomes (*Sankaranarayanan, Budukh & Rajkumar, 2001*).

Based on available data, cervical cancer and its prevention are important public health issues in Romania, and several prevention initiatives have been undertaken at both national and regional levels to change this unfavorable situation. After the failure of the initial HPV vaccination campaign, the Ministry of Health has taken new measures to reduce the incidence and mortality from cervical cancer, such as launching an organized screening program for cervical cancer for all women at the ages of 25 - 64, regardless of their insurance status. The implementation and rollout of the program started in 2012. Until 2012, screening in Romania was opportunistic. In contrast to organized, population-wide screening, opportunistic screening depends on the individual initiative of the woman and/or her doctor. This type of screening often results in over-screening in certain parts of the population and a heterogeneous coverage overall, with socio-economically disadvantaged groups typically under-screened. Opportunistic screening, on the other hand, has helped reduce cost-

effectiveness and monitoring difficulties (*Arbyn et al., 2010*). Both the WHO and the European Guidelines recommend organized programs in order to improve the accessibility and equity of screening access, while simultaneously increasing effectiveness and cost-effectiveness (*Arbyn et al., 2010*). In well-organized population-based screening, all women are followed up from the initial invitation and test to the eventual treatment, and all data collected during these phases are recorded. Such data are essential for monitoring and evaluating of the quality and effectiveness of screening.

Among the key features of an organized screening program are the target age, the screening intervals, the screening algorithm represented by the primary screening test and the subsequent management of results. Such a program was started in Romania in 2012. The target population was defined as women aged 25 to 64, either state-insured or un-insured (approximately 5.6 million women). Advice from general practitioners and gynecologists along with media advertising made the information about this program widely available to the population; after visiting the general practitioner for information and instructions, the patient would fill out a form handed out by the gynecologist and the pathologist. There were no personalized invitations (letters, telephones etc.) sent to the patients. The algorithm comprised a single conventional Pap smear done free-of-charge at five-year intervals, with the general practitioners or gynecologists collecting the Pap smear samples and consultant pathologists or cytologists analyzing them. All the results are reported according to the Bethesda System for Reporting Cervical Cytology. The success of the screening depends on the quality and implementation of protocols and of national guidelines for primary screening and follow-up.

With regard to the secondary prevention of cervical cancer, I have published two original articles in ISI-indexed journals with impact factor, and three articles in journals indexed in other international databases and in national journals.

Coverage is a major factor contributing to the effectiveness of cervical cancer screening, so four years after the cervical cancer screening program was introduced in Romania in 2012, I conducted a study analyzing the participation rate and the prevalence of abnormal epithelial changes and their types in a previously unscreened, asymptomatic population. Adequate coverage is dependent on public knowledge of the benefits of the Pap smear test and its actual availability at health facilities, as well as on the proper overall functioning of the health system (testing, receiving the results, referring abnormal results to appropriate level of care, all in a timely manner), and the perception and attitude of health care workers. The study was performed in Northeastern Romania. According to the demographic data, this region had 639,492 eligible women for cervical cancer screening out of the total 5.6 million eligible women in Romania. This study was the first report of an analysis of the cervical Pap smear results from Northeastern Romania.

In order to evaluate the knowledge of the benefits of the Pap smear test, we conducted a second study. Because public awareness is an important factor in the success of a screening program, our intention was to assess the knowledge of Romanian women regarding the perception and the level of awareness on Papanicolaou test in the prevention of cervical cancer. Even in countries with organized screening services, the coverage is lower in underserved, uninsured and under-represented populations due to costs, access problems, anxiety, discomfort with the screening procedure, fear of cancer and/or poor health literacy, all of which contribute to poor outcomes for cervical cancer (*Musa et al., 2017*). Musa et al. consider that the implementation of theory-based cervical cancer educational interventions are

beneficial and can increase women's participation in cervical cancer screening programs. Education is, therefore, a key contributor to the success of a screening program.

Within the direction of researches on secondary prevention, I have published 2 articles, 2 articles ISI indexed journal, several abstract in ISI journal supplements, and oral presentations at international congress.

Published papers:

1. Păvăleanu I, Gafițanu D, Ioanid N, **Grigore M**. Preliminary results of the first cervical cancer screening programme in the North Eastern region of Romania. *J Med Screen* 2018; 25:162-165. **IF- 2,689**
 - Awarded in the **UEFISCDI** competition "Premierea Rezultatelor 2018" PN-III-P1-1.1- PRECISI-2018- 28900
2. **Grigore M**, Popovici R, Pristavu A, Grigore AM, Matei M, Gafitanu D. Perception and use of Pap smear screening among rural and urban women in Romania. *Eur J Public Health* 2017; 27:1084-1088. **IF 2,72**
 - Awarded in the **UEFISCDI** competition "Premierea Rezultatelor 2018" PN-III-P1-1.1-PRECISI-2018-22326

I.2.1.3.2. Material and methods

- ***Preliminary results of the first cervical cancer screening programme in the North Eastern region of Romania***

We analyzed the results of the first four years of cervical cancer screening in the northeastern part of Romania. A retrospective cross-sectional observational study was performed, reviewing women's participation rate in the screening program and the results of the Pap smears. All data was extracted from the archives of the Regional Management Department. The participation rate per year was analyzed to observe the trends in the screening coverage. The results of Pap smears were also analyzed, and all of the cases were reported according to the Bethesda System for Reporting Cervical Cytology. The following categories were excluded from the study: normal cases (negative for intraepithelial lesion or malignancy), cases presenting benign lesions (infections, reactive cellular changes associated with inflammation, radiation, intrauterine contraceptive device, and atrophy), cases in which the examination revealed unsatisfactory material. We analyzed cases with intraepithelial lesions represented by atypical squamous cell of undetermined significance (ASCUS), atypical squamous cell cannot exclude high lesion (ASC-H), low-grade squamous intraepithelial lesion (LSIL), high-grade squamous intraepithelial lesion (HSIL), and atypical glandular cells (AGC). The malignant categories were squamous cervical cancer (SCC), adenocarcinoma (ADK), and other malignancy not otherwise specified. Cytopathological results of the Pap smears were reviewed according to age distribution. The following clinical parameters were recorded for each Pap smear that was included in the study: patient age, personal and family history, the results of previous cytological and histopathologic examinations, and the date of last menstrual period. Informed consent was obtained from each woman.

- ***Perception and use of Pap smear screening among rural and urban women in Romania***

This cross-sectional study was conducted among 454 women from rural and urban area from April to July 2015. In rural areas the women fulfilled the questionnaire at a general practitioner's office, and in urban areas at a gynaecologist's office and general practitioner's office. Written consent was obtained from all the participants, after they were informed about the study. The questionnaire regarding cervical cancer and Pap smear included questions grouped in three parts: 1. Socio-demographic and socioeconomic factors like age, marital status, level of education, number of children, income - 6 questions; 2. Awareness and knowledge about Pap smear - 8 questions. 3. Source of information - 3 questions. The questionnaire was pretested on 20 women before being used in the main study in order to assess the clarity of the questions. Knowledge of Pap smear testing was related to the socio-demographic characteristics of the participants

I.2.1.3.3. Results

- ***Preliminary results of the first cervical cancer screening programme in the North Eastern region of Romania***

A total of 107,968 cases of cervical Pap smears were conducted during the four-year period in the northeastern part of the country, representing about 16.88% of the target women in this geographical region.

We compared the results per year by grouping the data into twelve months intervals, starting with September 2012, which was when the national program started. We analyzed 54,235 cases for the period of 2012-2013, and 20,877, 20,277 and 12,579 cases for the following years, respectively; and observed a continuous decrease in the number of patients screened). The distribution of the normal, abnormal, and unsatisfactory smears per year is shown in Table 6.

Table 6. Distribution of the smear test results for each year of the study

Result	2012 - 2013	2013 - 2014	2014 - 2015	2015 - 2016	Total
No. of slides	54,235	20,877	20,277	12,579	107,968
NILM	50,166	19,563	19,020	11,935	100,684
ASCUS	1,981	723	675	349	3,728
ASCH	356	107	149	79	691
LSIL	688	229	189	91	1,197
HSIL	221	60	68	48	397
SCC	36	8	12	4	60
AGC	462	191	163	71	887
ADK	6	2	3	1	12
UNSF	276	9	24	3	312

The Pap smears were unsatisfactory in 312 cases and were deemed inadequate for interpretation. In the first twelve months, there were a higher number of unsatisfactory smears as compared to the next three years, and this could be explained by the lack of experience and sufficient proficiency at the beginning of the program.

Of the 107,656 slides that were adequate for interpretation, 100,684 (93.52%) were negative for intraepithelial lesions and 6,972 (6.48%) presented epithelial cell abnormalities. Squamous epithelial cell abnormalities (6,073 cases) represented 5.64% of the total number of adequate cases analyzed and glandular cell abnormalities (899 cases) represented 0.84% of all the cases.

The distribution of the anomalies from the analyzed smears was as follows: ASCUS 3.45%, ASC-H 0.64%, LSIL 1.10%, HSIL 0.37%, SCC 0.05%, ACG 0.82%, and ADK 0.01%. Sixty cases of SCC and 12 cases of ADK were diagnosed during the period of 2012-2016 (Figure 1). The number of pathological findings per year is shown in Figure 2.

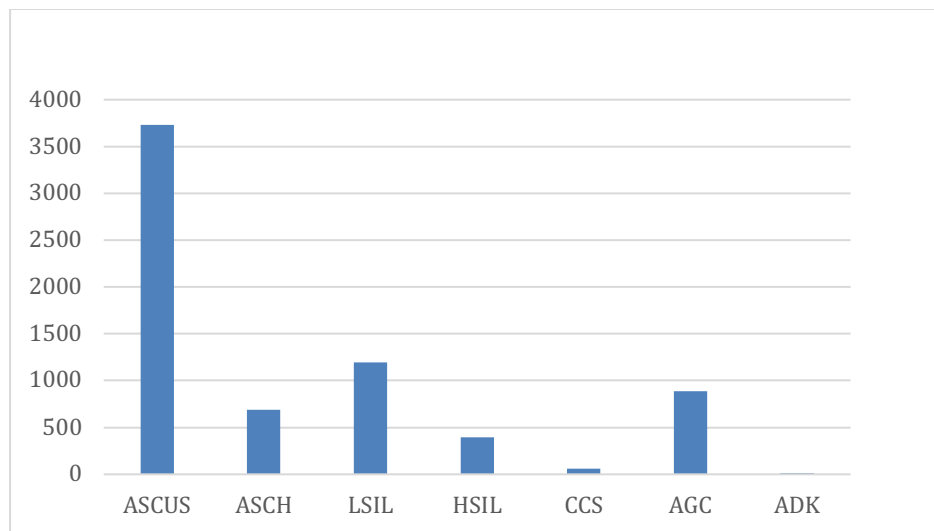


Figure 1. The abnormal squamous and glandular results.

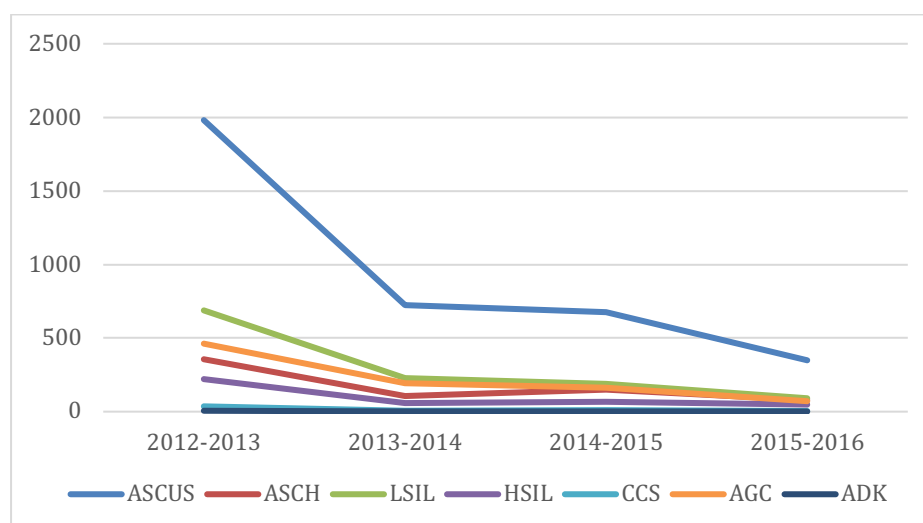


Figure 2. Pathological findings per year.

The incidence of different cell abnormalities was calculated for each age group, and the results are presented in Figure 3. No age data was recorded during 2012, so the calculations took into account only the data from 2013-2016.

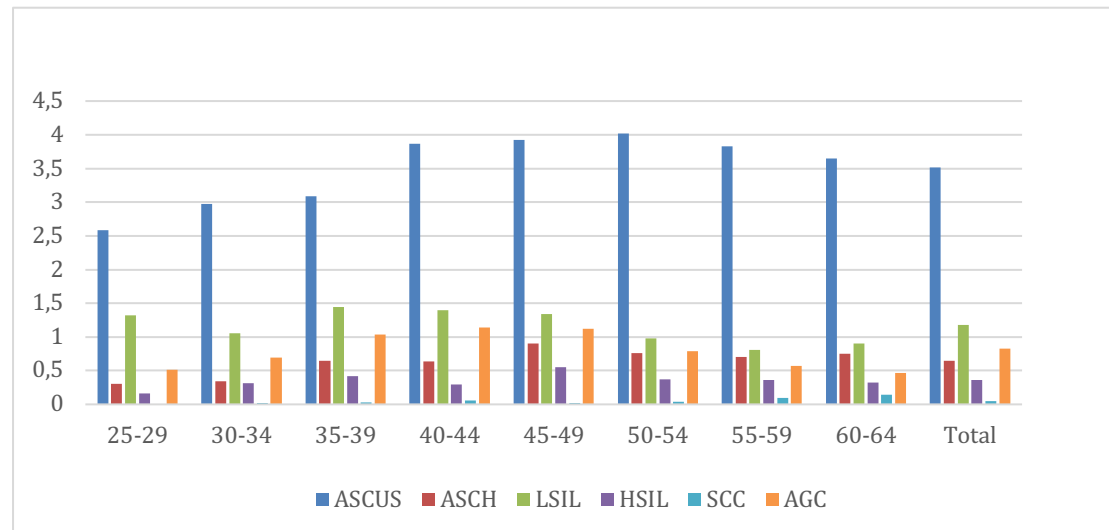


Figure 3. Prevalence of the different cell abnormalities based on age groups.

- ***Perception and use of Pap smear screening among rural and urban women in Romania***

We performed a quantitative study on 454 women from rural (212 cases - 46.7%) and urban area (242 cases - 53.3%). The mean age of the study population was 33.4 years (33.4 +/- 7.8). 35.9% of the women were under 30 year old, while 3.1% were over 50 years old, without a significant difference between rural and urban area ($\chi^2 = 7.58$; df = 5; p = 0.181). The main socio-demographic characteristics (marital status, education level, occupation, number of children) are presented in table 7.

Table 7. Socio-demographic characteristics of the participants

Variable	Number	%
Marital status		
Single	75	16.5
Married	349	76.9
Concubinage	15	3.3
Divorced	9	2
Widow	6	1.3
Education Level		
Primary	189	41.6
Secondary	153	33.7
University degree	112	24.7

Number of children		
No children	162	35.7
1	118	26.0
2-3	146	32.2
>3	28	6.2
Occupation		
Employee	228	50.2
Student	21	4.6
Retired	4	0.9
Social aid	22	4.8
Without occupation	179	39.4

Regarding the **level of education**, the patient distribution showed a significantly higher percentage of women with a low educational level in rural areas (77.4% of patients with 10 or fewer grades) while in urban areas was noted the predominance of women with an increased educational level (43.4% - bachelor degree and 46.3% - high school) ($\chi^2 = 225.2$; $df = 3$; $p = 0.001$) (table 8).

The distribution of subjects according to the **occupation** reveals a significantly higher percentage of women with no occupation in rural areas (72.2 %) while in urban areas was identified an increased addressability of employed women ($\chi^2 = 219.2$; $df = 4$; $p = 0.001$) (table 8).

According to the **monthly income**, the distribution of patients showed a significantly higher percentage of women with no income or less than minimum wage - 58.5% of subjects that addressed the family doctor in rural areas, while in urban areas there was a higher addressability of women with monthly average income (46.7%) or above average income (25.2%) ($\chi^2 = 134.1$; $df = 4$; $p = 0.001$) (table 8).

Patient access to healthcare services was more difficult among those from rural areas (26.9% versus 12.8%) ($\chi^2 = 13.4$; $df = 1$; $p = 0.001$).

Table 8. The distribution of study groups by level of education, occupation and monthly income.

Characteristic	The general practitioner's office (rural area) (n = 212)		The gynaecologist's office (urban area) (n = 242)		Total (n = 454)	
	n	%	n	%	n	%
Level of education						
8 grades	86	40.6	4	1.7	90	19.8
10 grades	78	36.8	21	8.7	99	21.8
High school	41	19.3	112	46.3	153	33.7
Bachelor degree	7	3.3	105	43.4	112	24.7
Occupation						
Unemployed	153	72.2	26	10.7	179	39.4
Social aid	18	8.5	4	1.7	22	4.8
Retired	3	1.4	1	0.4	4	0.9
Employed	35	16.5	193	79.8	228	50.2
Student	3	1.4	18	7.4	21	4.6

Monthly income						
Less than the minimum-wage	124	58.5	36	14.9	160	35.2
The minimum wage	45	21.2	32	13.2	77	17.0
Average income	38	17.9	113	46.7	151	33.3
Above average income	5	2.4	54	22.3	59	13.0
Well above average income	-	-	7	2.9	7	1.5

Awareness, knowledge and attitude toward Pap smear testing

Among the studied cases was noted that approximately 95% of the respondent women have heard about the Pap test. From these, 92% were in rural areas, and 97.5% in urban areas ($\chi^2 = 6.1$; $df = 1$; $p = 0.013$). There were significant difference regarding education, occupation, monthly income and access to free healthcare services between women who were aware and those who weren't aware regarding Pap smear ($p < 0.01$) (table 9). These findings reflect a poor level of knowledge regarding Pap smear and cervical cancer screening among women with low socio economic factors.

Table 9. The correlations between the demographic characteristics and the knowledge regarding the Pap test.

Age (years)					Education				
($\chi^2 = 0.07$; $df = 1$; $p = 0.788$)					($\chi^2 = 8.75$; $df = 1$; $p = 0.003$)				
	yes		no			yes		no	
	n	%	n	%		n	%	n	%
< 20	5	1.2	3	13.0	8 grades	82	19.0	8	34.8
20-29	148	34.3	7	30.4	10 grades	90	20.9	9	39.1
30-39	198	45.9	6	26.1	High school	149	34.6	4	17.4
40-49	67	15.5	6	26.1	Bachelor degree	110	25.5	2	8.7
50-59	12	2.8	1	4.3					
60-69	1	0.2							
Occupation					Marital status				
($\chi^2 = 8.03$; $df = 1$; $p = 0.005$)					($\chi^2 = 0.15$; $df = 1$; $p = 0.700$)				
	yes		no			yes		no	
	n	%	n	%		n	%	n	%
Unemployed	163	37.8	16	69.6	Single	69	16.0	6	26.1
Social aid	20	4.6	2	8.7	Married	335	77.7	14	60.9
Retired	4	0.9			Divorced	9	2.1		
Employed	225	52.2	3	13.0	Widow	5	1.2	1	4.3
Student	19	4.4	2	8.7	Concubinage	13	3.0	2	8.7
Monthly income					Number of births				
($\chi^2 = 6.79$; $df = 1$; $p = 0.009$)					($\chi^2 = 0.29$; $df = 1$; $p = 0.589$)				
	yes		no			yes		no	
	n	%	n	%		n	%	n	%
Less than the minimum-wage	146	33.9	14	60.9	0	153	35.5	9	39.1
The minimum wage	74	17.2	3	13.0	1	115	26.7	3	13.0
Average income	146	33.9	5	21.7	2-3	138	32.0	8	34.8
Above average income	58	13.5	1	4.3	>3	25	5.8	3	13.0

Well above average income	7	1.6							
Health services access									
$(\chi^2 = 8.98; df = 1; p = 0.003)$	yes		no						
	n	%	n	%					
Easy	353	81.9	13	56.5					
Difficult	78	18.1	10	43.5					

Although 95% had heard of Pap test only 71.8% of the study participants (326 women) correctly knew the role of the Pap test in detecting cervical cancer. A percentage of 13.8% (63 women) believed that the role of the Pap test is to detect genital diseases denoting vague information in this regard, while 14.3% (65 subjects) did not know the role of the test. The epidemiological profile of women who do not know what the aim of Pap test is, included the following features: the age between 30 and 39 years (45.2%), less than 10 grades (88.1%), no occupation (61.9%), married (81%), with a monthly income below the minimum wage (57.1%), with difficult access to healthcare services (42.9%) and 2-3 previous births (45.2%). In addition, knowing someone with cervical cancer and ever visit a healthcare institution were significant predictors for knowledge.

The knowledge about how often this test should be performed showed significant differences according to the education level, the occupation, the monthly income, the access to healthcare services, and the number of births ($p < 0.05$). In our study the majority of patients evaluated in the gynaecologist's office pointed out that the Pap test should be performed annually (83.4%) compared with those that were assessed in the general practitioner's office (63.1%) ($\chi^2 = 24.6; df = 3; p = 0.001$).

59.9% of women in the study (270 subjects) said they performed at least once a Pap test. The epidemiological profile of women who said they have performed the Pap test ($n = 270$) included the following characteristics: the age between 30 and 39 (50.4%), as the level of education - high school and bachelor degree (74.9%), employed (66.7%), married (80.4%), with a monthly average income (37.4%), with an easy access to healthcare services (85.9%), and at least one birth (73.9%).

40.5% of women who responded to the questionnaire did not perform the Pap test, the various reasons given being: lack of time or financial resources (39.4% and 23.8%, respectively), embarrassment of gynecological examination (13.8%) or various other reasons (the feeling that they don't need the Pap test, fatalistic attitude towards the disease, or misconceptions about cervical cancer) (table 10)

Table 10. The distribution of subjects according to the reasons for non-participating on Pap test

The reason for non-participating on Pap test	The general practitioner's office (rural area) (n = 212)		The gynaecologist's office (urban area) (n = 242)		Total (n = 454)	
	n	%	n	%	n	%
Lack of time	22	18.6	16	38.1	38	23.8
Lack of financial resources	58	49.2	5	11.9	63	39.4
Embarrassment against	16	13.6	6	14.3	22	13.8

gynaecological council						
Others	22	18.6	15	35.7	37	23.1

The correlations between reasons for not doing the Pap smear and demographic characteristics are presented in table 11.

Table 11. Correlations between not doing Pap smear and demographic characteristics

Demographic characteristics	Lack of time (n=38)		Lack of financial resources (n=63)		Embarrassment against gynaecological council (n=22)		Others (n=37)	
	n	%	n	%	n	%	n	%
Age (years) ($\chi^2 = 3.1$; df = 3; p = 0.378)								
< 20	1	2.6	1	1.6	1	4.5	1	2.7
20-29	16	42.1	23	36.5	10	45.5	19	51.4
30-39	15	39.5	26	41.3	9	40.9	12	32.4
40-49	6	15.8	11	17.5	1	4.5	4	10.8
50-59			2	3.2	1	4.5	1	2.7
Education ($\chi^2 = 20.6$; df = 3; p = 0.001)								
8 grades	9	23.7	30	47.6	5	22.7	10	27.0
10 grades	10	26.3	24	38.1	7	31.8	7	18.9
High school	15	39.5	9	14.3	8	36.4	13	35.1
Bachelor degree	4	10.5			2	9.1	7	18.9
Occupation ($\chi^2 = 25.8$; df = 3; p = 0.001)								
Unemployed	15	39.5	52	82.5	10	45.5	18	48.6
Social aid	3	7.9	4	6.3	2	9.1		
Employed	15	39.5	6	9.5	7	31.8	16	43.2
Student	5	13.2	1	1.6	3	13.6	3	8.1
Marital status ($\chi^2 = 5.44$; df = 3; p = 0.142)								
Single	11	28.9	9	14.3	6	27.3	7	18.9
Married	27	71.1	51	81.0	14	63.6	24	64.9
Divorced					1	4.5	3	8.1
Widow							1	2.7
Concubinage			3	4.8	1	4.5	2	5.4
Monthly income ($\chi^2 = 10.3$; df = 3; p = 0.016)								
Less than the minimum-wage	13	34.2	43	68.3	10	45.5	17	45.9
The minimum wage	10	26.3	6	9.5	3	13.6	8	21.6
Average income	13	34.2	13	20.6	8	36.4	9	24.3
Above average income	2	5.3	1	1.6			2	5.4
Well above average income					1	4.5	1	2.7
Health services access ($\chi^2 = 0.50$; df = 3; p = 0.919)								
Easy	29	76.3	47	74.6	17	77.3	26	70.3
Difficult	9	23.7	16	25.4	5	22.7	11	29.7
Number of births ($\chi^2 = 15.73$; df = 3; p = 0.001)								
0	12	31.6	8	12.7	6	27.3	17	45.9
1	8	21.1	14	22.2	5	22.7	11	29.7

2-3	14	36.8	33	52.4	10	45.5	6	16.2
>3	4	10.5	8	12.7	1	4.5	3	8.1

The healthcare professionals remain the main source of information about the Pap test and the HPV vaccine in both rural and urban areas (25.5% and 33.5%, respectively) ($p = 0.079$)

I.2.1.3.4. Discussion

- ***Preliminary results of the first cervical cancer screening program in the North Eastern region of Romania***

According to IARC guidelines, one of the most important factors for screening effectiveness is coverage defined as the number of women tested within a recommended interval (*IARC Handbook*, 2005). In the first four years of the cervical screening, the participation rate in the northeastern part of the country was low (16.88%) with an alarmingly continuous decrease. However, the data concerning coverage of Pap smear is incomplete because, during that time period, there was opportunistic screening in addition to organized population-based screening. The opportunistic screening is practiced in Romania either at the private gynecological clinics or at some of the units that cooperate with the National Health Fund and Pap smear tests are done in these setting as part of a comprehensive gynecological examination. This opportunistic screening, usually initiated by the woman herself or gynecologist, occurs even in countries with organized programs; hence many women have Pap smear test done outside the organized program. A study from Denmark, a country with a well-established screening program, showed that one fourth of the Pap smear tests in this country are conducted opportunistically (*Tranberg et al.*, 2015). The authors of this study consider that opportunistic testing might serve as an important supplement to the systematic screening program by including non-participating women who may otherwise be tested with a delay or not tested at all. In Romania, all of the results from the opportunistic screening are not reported and registered in the national database. For a better assessment of the situation, it is recommended that the results from both the organized and opportunistic screenings should be analyzed in the future.

According to the demographic data, this region (North Eastern part of Romania) had 639,492 eligible women for cervical cancer screening out of the total 5.6 million eligible women in Romania. The total numbers of Pap smears from national screening program reported in northeastern part of the country was 107,968. The smear samples were inadequate in 312 cases. Of the 107,656 satisfactory smears, the prevalence of abnormal epithelial changes was 6.48%, with a high prevalence of ASCUS (3.46%), followed by LSIL (1.11%), ASC-H (0.64%), HSIL (0.37%). AGC were present in 0.82% of the cases, and SCC was detected in 60 cases, in addition to 12 cases of ADK. The cases with SCC were more frequent in the age group of 35-39 years and 60-64 years, which may be explained by the patterns of the HPV infection peaks described in the literature. The first peak in HPV infection is among the youngest age group (15–19 years), while the second peak is among the 50–60-year-old group (*Franceschi et al.*, 2006).

To compare the prevalence of abnormal Pap smears in Romania to that of in other countries, a search on PubMed was conducted. Based on the analysis of the studies in different countries the prevalence of cell abnormalities varies between 1.8-

5.8%. The prevalence of precursor and invasive cervical cytological anomalies differ according to the study population (e.g., level of awareness, socio-economic status, and the religious factors), the prevalence of HPV, and the experience of the cytologists and cytology technicians evaluating the smears. The high prevalence of cervical abnormalities (6.65%) in Romania underscores the need for a continuous national screening program.

In addition to the high prevalence of precursor cervical lesions, our study revealed that the utilization of the screening program is low. Because of these two facts, several urgent measures should be taken to increase the participation in the screening program. To have an impact on cervical cancer incidence and mortality, efforts must be focused on increasing the awareness of women about cervical cancer and the prevention methods through an intensive promotional campaign to encourage participation in the screening. At the same time, general practitioners should be more actively involved in the program as they play a key role in counseling the women.

The limitation of this study is that we analyzed data from one region of the country, and analyzing similar data for the entire country and making comparisons among regions would be interesting. Additionally, it is necessary to conduct studies in the future to investigate the reasons for low utilization of the screening and how this can be improved.

The screening program represents an important tool in detecting pre-neoplastic lesions and cervical cancer. Evaluation of the first four-years of the screening program reveals a low participation of the eligible population and a high prevalence of (6.65%) cervical precursor lesions. These findings underscore the importance of the continued implementation of the national screening program that was started in 2012. The policy-makers should take new measures to increase women's participation in this screening program.

Participation in the screening program represents a key element for the success of the program. In Netherlands, after more than 20 years of screening, incomplete participation is the main cause of cervical cancer incidence. According to *Bos et al.*, increasing screening participation has more potential to reduce cervical cancer incidence further than shortening the screening interval, increasing the age range or having a screening test with higher sensitivity (*Bos et al., 2006*).

In Romania, in the first 4 years after the introduction of organized screening, coverage was very low. Note should be made that the figures from our study include data only from organized screening. Data from opportunistic screening are not available and it is possible that a certain part of the population is screened in the private system. In Romania, the more economically affluent population (and with a higher level of education) has access to the private health care sector and may be over screened. Practices of health care professionals resulting in excessive opportunistic testing should be revised. Health care professionals need to understand and to promote the transition from excessive opportunistic testing to better compliance to organized screening. Opportunistic screening is characterized by lack of quality assurance and monitoring, lack of service organization and centralized reporting. Health care providers may not know about tests taken by other providers and no provider takes full responsibility for organizing adequate follow-up (*Makkonen et al., 2017*).

Several strategies that can be applied in order to achieve better participation. For one, the modality of inviting women to the screening program should be considered. The invitation could come as a suggestion or request to contact the smear-taker and make an appointment (open invitations) or as a letter with pre-assigned date

and place for the appointment that can be modified by contacting the organizing center. A call/recall system based on personal invitations is considered to be a key element of an organized program in Europe (*IARC Handbook, 2005, Arbyn et al 2008*).

According to several authors, the invitation seems to be an efficient method to increase participation, and letters with fixed appointments are more effective than open appointments (*Everett et al., 2004*). Tavasoli et al. explored the impact of invitation and reminder letters on the cervical cancer screening participation of women from Ontario aged 30-69. They compared women who received the intervention (n=99,278) with a historical non-intervention group (n=130,181). On cohort analysis, 14.1% of women in the intervention group and 8.5% of women in the non-intervention group were screened within 9 months. Being mailed an invitation letter was associated with greater likelihood of screening (OR=1.8, CI 1.7-1.8). The conclusion was that the invitation and reminder letter strategy increased cervical cancer screening participation (*Tavasoli et al., 2016*). Furthermore, if the invitation letter is signed by a general practitioner rather than by program staff or a nurse practitioner, that seems to increase the participation in the screening as well (*Segnan et al., 1998*).

Invitations by telephone have also been studied in non-attendees population. *Broberg et al.*, for instance, researched telephone contact with non-attendees, in which these were offered an appointment to take a smear, and compared the results with a control group in a population-based randomized trial in western Sweden. Of 8,800 randomly selected women aged 30-62, without a registered Pap smear in the two latest screening rounds, 4,000 were randomized to receive the telephone call, another 800 were offered a high-risk human papillomavirus (HPV) self-test by mail (not reported in this article) and 4,000 constituted a control group. Participation during the following 12 months was significantly higher in the group being telephoned than in the control group, 718 (18.0%) versus 422 (10.6%). Twice as many high-grade intraepithelial neoplasia (CIN2+) were detected and treated in the group invited via telephone: 14 and 7, respectively. In conclusion, telephone contact leads to a significant increase in detection of atypical smears. Cost calculations indicate that this intervention is unlikely to be cost generating, and this strategy is therefore feasible in the context of a screening program (*Broberg et al., 2013*).

A new method that can improve participation in cervical cancer screening is HPV self-sampling. This method was proven efficient among lower socioeconomic groups (*Waller et al, 2006*). Several studies suggest that HPV self-testing has the same effectiveness as conventional screening and is potentially more cost-effective (*Dannecker et al., 2004; Lazcano-Ponce et al., 2011*). The systematic review by Racey et al. found that women were twice as likely to comply with screening if offered this method (*Racey et al., 2013*). The authors appraised studies of interventions aiming to improve breast and cervical cancer screening uptake, available up to 2006. They found two large, randomized controlled trials of HPV self-testing that increased cervical screening uptake. These two studies have found that HPV self-testing can improve uptake of cervical cancer screening among lower socioeconomic groups (*Rees et al., 2018*). *Duke et al.* performed a study to evaluate whether offering self-collected HPV testing screening increased cervical cancer screening rates in rural communities. During the 2-year study, three community-based cohorts were assigned to receive either a cervical cancer education campaign with the option of HPV testing, or an educational campaign alone, or there was no intervention. The results showed that women who self-collected HPV samples had

generally positive feelings about the experience. The main conclusion of the study was that offering HPV self-collection may increase screening compliance, particularly among women who do not present for routine Pap smear tests (*Duke et al., 2015*).

Self-sampling is an additional option that deserves be explored in our country, especially for women with low socio-economic status. Each country can respond different to this additional screening tool and a pilot study is needed before implementing it in the national organized program. However, there may be barriers to the self-collection procedure, such as if women are uncomfortable performing the procedure or uncertain regarding the validity of its results. To increase participation, it is important that women understand the long-term advantages of cervical screening. The benefits of early detection from screening are not fully realized and not shared equally among different segments of the population. The resulting, avoidable mortality disproportionally affects poor populations. Lack of uptake could be influenced by emotions: fear of cancer can result in avoidance of risks or of the screening procedure. Sometimes women underestimate their own personal risks even if they are advised about the probability of getting cervical cancer, and this could also be an explanation for low attendance. Therefore, it matters how the providers deliver information regarding screening. The providers (physicians and, particularly, nurses), who have close, personal contact with the invited women play an important role. Health care providers often do not correctly evaluate how much information women have and wrongly assume that patients ask for information when they need it. They must advocate for attendance in screening and this should be one of the main tasks of health education, which should employ a wide range of arguments to promote participation in cervical screening (*Döbrössy et al., 2015*).

- ***Perception and use of Pap smear screening among rural and urban women in Romania***

The current study is the first to explore the level of knowledge and awareness of Pap smear testing among Romanian women. This research provides a detailed picture of both rural and urban areas, two regions characterized by both educational and economic difference.

The research found a good awareness of Pap smear among the participants. 92%, respectively 97.5% of the women from rural and urban area declared that they heard about Pap smear. Despite the overall good awareness regarding Pap smear only 71.8% (326 women) knew the exact role of it. Several socio-demographic variables such as higher income, education, older age and being married were found to be predictors of a good knowledge level of Pap smear, its role, and how often it should be done. Our results are in accordance with similar paper from the literature. The importance of educational status on knowledge of cervical cancer has been mentioned in several studies in the literature and all reflect a good correlation between high level of education and good level of awareness regarding Pap smear and cervical cancer (*Tebeu et al., 2008; Getahun et al., 2013*).

The current study showed that socio-demographic characteristics of individuals such as age, marital status, occupation, level of education and religion have significant effects on knowledge regarding Pap smear. The gap of knowledge regarding Pap smear and its benefit observed among women with low socio-economic status in our study was in agreement with studies from the literature (*Baskaran et al., 2013; Abiodun et al., 2014*;). In the light of these studies, the overall status of

knowledge in low and middle-income countries was estimated to be low.

Although 71.8% of the participants in our study knew the benefits of Pap smear only 59.9% declared that they already done it. Analysing the socio-demographic parameters revealed that women with low status refused to have Pap smear test. The main reasons for not participating on the screening test included: lack of money, fear of gynaecologic consult and pain, the feeling that they don't need it, misconceptions about cervical cancer, fatalistic attitude, perceived low susceptibility to cervical cancer, and embarrassment. Our results were similar to other studies from the scientific literature that described as the most common reasons the following: lack of time, financial difficulties, fear of test result and lack of awareness as the main barriers against the Pap smear test lack of any symptoms, lack of counselling, physician does not request and fear of vaginal examination (*Thippeveeranna et al., Bahmani et al., 2015*).

Regarding the source of information and trust, the participants in our research stated that healthcare professionals along with television and Internet provided most of the information. The problems that arrive with Internet information is that although it is a powerful source of information, does not always provide the most accurate information.

The ignorance about cervical cancer and vaccine can be a serious barrier to a successful screening program and there are several studies that support this. Even if the screening is offered to all women no matter if they are or not insured, several factors are needed to make the program successful: developed healthcare services, easy access to healthcare for all categories of the population, good technical and laboratory expertise and, last but not least, a good public awareness. Romania already had a failure attempt of HPV vaccination. In 2012 the screening programme for cervical cancer was introduced in Romania to all women aged between 24 to 65 years old. In order to be successful with this issue is important to continuously improve the population knowledge regarding the importance and benefit of the screening programme and the Pap smear.

Our study showed that in Romania there are significant differences between women characterized by low and high socioeconomic factors regarding knowledge and acceptance of Pap smear. This highlights the need of improving cervical health behaviour through education and social empowerment especially in women with low socio-economic factors. While for HPV vaccination program the failure occurred because the lack of information but also negative publicity of the vaccine among all categories of parents (with low or high economic status), for cervical cancer screening program the focus should be especially on women with low socioeconomic factors. A good strategy is to involve both healthcare professionals and media. In the same time it is important to educate women to promote correct information to their family, friends or community.

Limitations of the study include the fact that the sample of our study was limited to one region of the country. Our results are relevant for the North Eastern part of Romania and are helpful for the Public Health Authorities from this region, which represents a quarter of the whole Romanian population. Another key limitation of this study is that all measures were based on the participants' self-reports, which may cause reporting bias. Despite these limitations, the uniqueness of this study is that it includes a large sample of women with different socio-economic status, allowing for a reliable assessment of Pap smear knowledge among the studied population.

The study shows a low level of awareness and acceptance of screening among low-educated women. Because the key to reducing cervical cancer morbidity and

mortality is still the early detection, customized multi-level educational interventions are needed to improve uptake of cervical screening among women with low socio-economic status.

To significantly reduce cervical cancer incidence and mortality, there should be more intensive promotional campaigns aiming to raise women's awareness of cervical cancer and prevention methods, as well as encourage their participation in screening.

In 2017, a systematic review conducted by *Musa et al.* appraised currently available evidence regarding the positive effects of cervical cancer education on to screening rates among eligible women (*Musa et al., 2017*). The authors found that knowledge of health risks and benefits appeared to act as a precondition for changing lifestyle habits. In other words, if women are not aware of the risks they are exposed to, they will perceive no need to change potentially detrimental habits. All interventions that increase women awareness, knowledge of cervical cancer, or importance of screening, in conjunction with counseling and assistance with scheduling screening appointments, will increase the overall likelihood of eligible women to have the Pap smear screening test (*Musa et al., 2017*). Musa et al. acknowledged the benefits of implementing theory-based cervical cancer educational interventions to increase women's participation in cervical cancer screening programs, particularly when targeting communities with low literacy levels. Additionally, cervical cancer screening programs should provide self-sampling opportunities, particularly for women who may have not responded positively to previous screening invitations or reminders.

There are several educational methods that could be used in practice. The advantages and benefits of screening can be explained with printed or video educational materials and discussions (face-to-face or over the telephone). Interventions targeting a larger population can include different types of media campaigns and community teaching, for example. Screening guidelines recommend the use of leaflets containing additional information whenever sending an invitation letter (*Arbyn et al., 2008*). However, leaflets seem to achieve limited impact, and relevant published evidence is scarce.

Sossauer et al. showed that a culturally sensitive campaign based on short videos influenced and improved knowledge about HPV and cervical cancer (*Sossauer et al., 2015*). These results were consistent with previous reports demonstrating that appropriate educational interventions about cervical cancer can improve women's health-related knowledge and lower perceived barriers to early detection and screening (*Love, Tanjasiri, 2012*). This points to women's knowledge of cervical cancer as a necessary step for changing their behavior towards actively seeking cervical health. However, although a desirable outcome in the context of public education, improved awareness about HPV and cervical cancer screening does not necessarily translate into a more positive participation and uptake of cervical cancer screening, as shown by *Sossauer et al.*

Our study shows that there is a clear need for knowledge improvement, especially in rural areas. Because participation in the screening program in Romania during the first four years was low (16.88%), several strategies and measures are required (*Pavaleanu et al., 2018*). First, it is important to identify possible high-risk groups, particularly women who have never been screened or are under-screened. A systematic review by *Spadea* and colleagues regarding interventions to improve cervical and breast cancer screening among lower socioeconomic groups found that population-screening programs are unlikely to have a major impact on reducing

socioeconomic inequalities in uptake, although better than spontaneous testing or no intervention. The reviewers considered that targeted interventions could increase uptake among lower socioeconomic groups, but in order to be effective, they should adapt the presentation of theoretical models based on in-depth knowledge of the targeted population. (*Spadea et al., 2010*). Moreover, healthcare professionals in general (general practitioners, gynaecologists, dermatologists, epidemiologists, infectious diseases specialists, school physicians and oncologists) need to have better knowledge about cervical HPV infection (risk factors, diagnosis, prevention, screening, vaccination, consequences), as well as the duty to inform individuals from the population they serve about cervical cancer screening. Appropriate information and training may be provided by means of Continuing Medical Education and human resources projects. Building health care systems that can address multiple factors simultaneously would improve cervical screening rates and overall outcomes for cervical cancer in populations at risk of this preventable cancer (*Musa et al., 2017*).

1.2.2. THE ROLE OF COLPOSCOPY IN THE DIAGNOSIS OF THE CERVICAL PRENEOPLASIC LESIONS

1.2.2.1. Background

Colposcopy is an invaluable method for the early detection and treatment of cervical lesions, as well as a potential step in the process of cervical cancer screening. In Romania, a National Screening Program was launched in 2012. High-quality colposcopy services are mandatory for the diagnosis and management of women with abnormal Pap smear test results. Quality assurance of colposcopy practices need to be conducted via systematic monitoring both internally (involving the colposcopist and institution) and externally, at national or regional level, to ensure quality of service consistently across the country (*Moss et al., 2013*). Internal audits should be well documented and should include identifying potential sources of error in the colposcopy process, detecting and minimizing errors, increasing the quality of the service. Recurrences after treatments, cases with positive cytology and negative histology results, significant incident reports can be reviewed and acted upon during such internal audits. In 2013, The European Federation of Colposcopy identified a list of quality indicators for colposcopy, which are relevant, practical and multiplicable across all the member countries: identification/documentation of the transformation zone in all cases, using colposcopy before treatment in all cases with cytological anomalies, making sure at least 80% of excisional procedures contain CIN2 plus and that at least 80% of cases have clear margins. Also, every colposcopist should assess clinically at least 50 cases with low-grade lesions and 50 cases with high-grade lesions annually (*Moss et al., 2013*). In the newly issued recommendations, the standard "percentage of cases having a colposcopic examination prior to treatment for abnormal cytology" was changed to "percentage of cases having a colposcopic examination prior to treatment for abnormal cervical screening test". The standard "percentage of all excisional treatments/conizations containing CIN2+ (cervical intra-epithelial neoplasia grade two or worse)" was rephrased as "percentage of excisional treatments/conizations having a definitive histology of CIN2+" (with definitive histology as the "highest grade from any diagnostic or therapeutic biopsies"). The standard "percentage of excised lesions/conizations with clear margins" was unchanged (*Petry et al., 2017*).

Nowadays, cervical cancer screening should be redesigned in the context of two concurrent developments: HPV testing and HPV vaccination. Cruickshank et al. conducted an observational study across colposcopy clinics in Scotland and found a reduction in the prevalence of high-risk HPV-16 and significant cervical intraepithelial neoplasia (CIN2+) in immunized women. Also, the positive predictive value of colposcopy in the vaccinated group was lower, highlighting a possible need to reassess the screening guidelines to account for HPV vaccination, which would be a consideration for similar guidelines worldwide. Colposcopy still remains a key element in the diagnosis of cervical preneoplastic lesions, and there is hope that future technological advances will reduce the subjectivity of visual pattern recognition of cervical pathology (Cruickshank et al., 2017). It is, in fact, the subjectivity of colposcopy that requires further advances in technology and qualitative measurement. In the last years, efforts have been being made to improve the diagnostic performance of colposcopy. Digital colposcopy is an example of progress in this area, elevating the use of traditional colposcopy equipment by introducing various forms of digital enhancement.

Colposcopy is usually performed after the diagnosis of a cervical smear abnormality or a positive high risk HPV test result. The major role of colposcopy is to guide the diagnostic biopsy. It is vital that colposcopists promptly recognize invasive cancers but, more often, they have to identify precancerous lesions. During a colposcopic examination, macroscopic changes such as color and morphology can be detected on the surface of the cervix or vagina. Assessment of the vessels must be performed concurrent to that of the epithelium before and after administration of acetic acid. The vascular changes induced by the development of the cervical intraepithelial lesion should be interpreted in the context of cytological and histologic changes.

Colposcopic changes enable the clinician to classify the lesions and to identify the best area to be biopsied (Louwers et al., 2009). CIN3 is considered to be the best disease endpoint to study as precancer, because CIN2 is poorly reproducible and often regresses (Jeronimo, Schiffman, 2006). As a visual diagnostic tool, colposcopy has its limitations, especially inter-observer variability. The colposcopic diagnostic is based mainly on the acetowhitening reaction, but this reaction is not unique to precancerous lesions; it can also be present in other situations, such as immature squamous metaplasia, congenital transformation zones, healing and regenerating epithelium, leukoplakia, and condyloma. Therefore, the expertise of the colposcopist is very important for the correct diagnosis. Moreover, several special conditions can make colposcopy difficult: pregnancy, menopause, colposcopy of the vaginal vault after total hysterectomy, cervical stenosis (after surgical treatments). Colposcopic accuracy varies according to the skill of the colposcopist and also the complexity of the case. Extensive experience in a colposcopy practice is essential to ensure high accuracy of colposcopy. At the same time, it is important to underline that, when performing a guided biopsy, even the expert colposcopist may not identify the worst area of a CIN lesion, so neither colposcopic impression nor histology alone are enough to inform proper management, and the result of an HPV test could prove useful. The reported sensitivity and specificity of traditional colposcopy vary from 83–98% to 48–66% depending on author (Zamudio-Andrade et al., 2001, Vlastos et al., 2002). Colposcopy has low specificity, which leads to a significant false positive rate. As such, acetowhite lesions associated with chronic cervicitis or squamous metaplasia can be mistaken for VPH infection or a precancerous lesion.

Despite studies that suggest that accuracy is low, colposcopy continues to be the standard for cervical diagnosis. With regard to on the role of colposcopy in the diagnosis of cervical lesions, I published one original article in International Journal of Reproduction, Contraception, Obstetrics and Gynecology.

Published paper:

Grigore M, Cojocaru C, Teleman S. The role of inner border sign and ridge sign in detecting high-grade cervical intraepithelial neoplasia. *International Journal of Reproduction, Contraception, Obstetrics and Gynecology* 2016; 5:3717- 3721.

I.2.2.2. The role of inner border sign and ridge sign in detecting high-grade cervical intraepithelial neoplasia**I.2.2.2.1.Introduction**

The cervix is evaluated through the colposcope and the main objectives are to detect abnormal epithelium, to identify the area of epithelium with the highest degree of disease, and to direct biopsies to that area or areas as needed. It is important not only to identify abnormal epithelium, but also to distinguish between low- and high-grade lesions. The colposcopic morphology of the atypical epithelium harboring CIN is dependent on a number of factors: thickness of the epithelium, variations in blood vessel patterns and alterations in surface contour and any associated changes in the covering epithelium. In order to assess the severity of the lesion, colposcopists have to evaluate the color and density of the acetowhite reaction. The acetowhite changes are the most important of all the colposcopic features because they are associated with all grades of CIN. It is also important to carefully document the colposcopic exam (on paper or electronically).

According to the European Federation of Colposcopy, differentiating between low- and high-grade lesions is one of the quality indicators for colposcopy practice. Suboptimal sensitivity of colposcopy for finding CIN3 was evident during the ASCUS/LSIL Triage Study (ALTS), a multicenter randomized trial involving more than 40 colposcopists (ALTS, 2003). ALTS was a large, multicentric study with 3 management approaches. In the immediate colposcopy group, in which all the women had colposcopy upon enrollment, only 54.8% of women with a final histologic diagnosis of CIN3 (established either upon enrollment or during the 2-year follow-up) had a positive colposcopic biopsy at enrollment. This study points to colposcopists needing to determine more precisely which colposcopic features and abnormalities can and which cannot be reliably distinguished, in conjunction with HPV status and disease outcome (ALTS, 2003). The colposcopic impression of any abnormality, as we know, is prone to observer variation and inter-observer variability is a noteworthy limitation of colposcopy. Increasing accuracy is, therefore, one of the main objectives in the effort to optimize the cervical cancer screening process.

Colposcopic abnormalities need to be confirmed by biopsies from all suspicious sites of precancerous lesions within the cervix, even though biopsy sampling is often a stressful and painful procedure for women. However, taking more

than one biopsy is a strategy to compensate for the current limitations of colposcopic assessment, until sensitivity and specificity can be substantially improved. In clinical practice, colposcopy and guided biopsies miss a fair percentage of mostly small CIN2 and CIN3 lesions. As a consequence of screening program developments, more colposcopies and fewer CIN2+ will mean that the positive predictive value and sensitivity for colposcopy to predict high-grade disease is likely to drop over the next 20 years (*Leeson, 2014*).

Standardization of the colposcopic examination also makes the practice more accessible and allows practitioners with differing educational and clinical expertise to perform it with improved accuracy. Over the years, a number of grading indices, which are based on a variety of morphologic phenomena, have been investigated and used to differentiate between normal, minor, and major changes of the cervical epithelium. Using a scoring system may reduce inter-observer variability. The Reid's Colposcopic Index was introduced into practice in the late 1980s as objective score for the severity of cervical lesions, and it is currently the most widely accepted scoring system. The Swede score, developed only a decade ago, introduces lesion size as a further parameter and, in comparison to the former, may be more useful in low-resource settings (*Ranga et al., 2017*). According to *Bowring*, the Swede score supersedes Reid's index, which excludes lesion size and scores acetowhiteness differently (*Bowring et al., 2010*). A recent study examining the efficacy of both Swede score and Reid's score found that the sensitivity and specificity of the two assessment tools was very high (sensitivity: 100% vs. 96.9%, specificity: 88.4% vs. 95.3%, respectively) (*Ranga et al., 2017*).

The application of grading criteria such as color, surface pattern, iodine uptake, presence or absence of abnormal vessels, and demarcation on an atypical transformation zone remains challenging because these atypical transformation zones do not always contain CIN. Thus, colposcopic signs that are highly correlated with CIN can be useful in clinical practice especially for trainees in colposcopy.

In light of this, we found it interesting to investigate the role of two pathognomonic colposcopic signs (inner border sign and ridge sign) in detecting high-grade cervical lesions. Pathognomonic signs differ from the other existing criteria in that they are simply present or absent. Their presence has been significantly associated with high-grade CIN and should prompt a biopsy. The colposcopic phenomenon of inner border has been described as an internal demarcation or an internal border and is defined as a sharp acetowhite demarcation within a less opaque acetowhite area. Ledges or ridges are areas of thick epithelium growth in the squamocolumnar junction. These ledges and ridges are suspicious for high-grade CIN because of their opaque color and lack of iodine uptake. Whenever this phenomenon is detected, a biopsy should be performed to prove or exclude high-grade CIN.

Because the association between the colposcopic sign inner border and moderate/severe cervical intraepithelial lesions has not been investigated systematically yet, it is our objective to evaluate the specificity and sensitivity of this phenomenon.

1.2.2.2.2. Material and methods

A total of 122 patients with abnormal Pap smears who had colposcopy and biopsy or loop electrosurgical excision procedure were included. The correlations between the two signs pathognomonic signs (inner border- figure 4, ridge sign- figure 5) and pathological results were established. We also compared the two signs with

Reid colposcopic index (RCI) in detecting high-grade cervical lesions.

I.2.2.2.3. Results

We calculated the correlation between Pap test and final histologic diagnosis (Table 12). Both pathognomonic signs proved to have a good accuracy in detecting high-grade lesions of the cervix. The sensitivity, specificity, PPV and NPV for the inner border sign and ridge sign were: 15%, 98%, 92%, 44%, respectively, and 30%, 94%, 88%, 47%, respectively. RCI has a sensitivity, specificity, positive predictive value (PPV) and negative predictive value (NPV) for predicting high-grade cervical intraepithelial lesions as follows: 86.3%, 83.6%, 88.7%, and 80.3%, respectively. The simultaneous presence of both signs increased the specificity and PPV to 100%, while sensitivity and NPV were 4% and 55%.

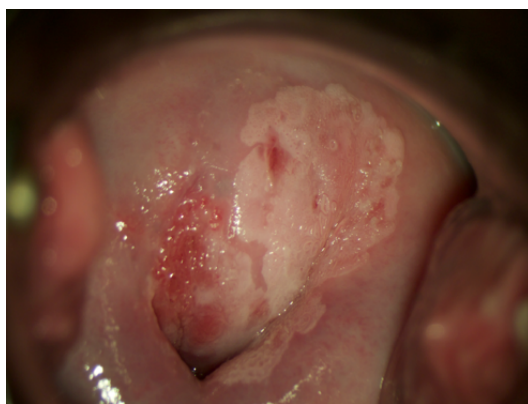


Fig.4. Border sign.

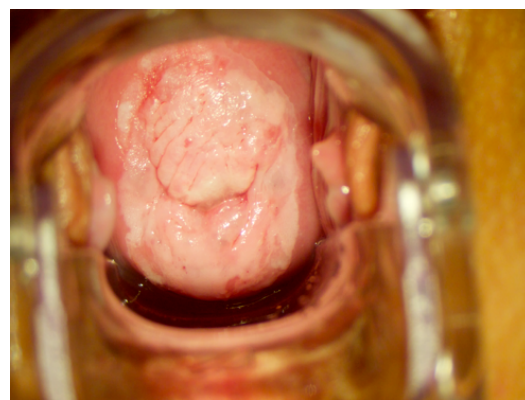


Fig. 5 Ridge sign

Table 12. Correlation between the Pap smear and the pathological result

Cell abnormality	Normal/benign findings	CIN I	CIN II- III	CIS	Total
ASCUS	4	14	10	0	28
ASC-H	0	7	17	5	29
LSIL	2	20	8	0	30
HSIL	1	1	24	9	35
	7	42	60	13	122

Table 13. Correlation between RCI and pathological report

	Score 0-2	Score 3-5	Score 6-8	Total
Normal findings	5	2	0	7
CIN I	5	29	8	42
CIN II-III, CIS	0	10	63	73
Total	10	41	71	122

The RCI was established for each case, and the correlation between Reid score and final pathological report is presented in Table 13.

I.2.2.2.4. Discussion

In our study, both RCI and the pathognomonic signs (inner border and ridge sign) proved to have high sensitivity and specificity in detecting high-grade lesions of the uterine cervix. The inner border and ridge sign are objective and effective colposcopic signs and are significantly associated with high-grade CIN. The problem is that they are simply present or absent: their presence is highly suggestive for high-grade lesions, but their absence does not necessarily mean absence of a high-grade CIN. In cases where the pathognomonic signs are absent, RCI is still a valuable tool that should be used for grading CIN.

Our study has some limitations. First, the study focused on only two pathognomonic signs, and in recent years, additional signs have been described (e.g., rag sign, cuffed gland openings). Also, the results of cytology were known before colposcopy examination. It would be interesting to establish if there are any correlations between HPV and the parameters studied, but because the HPV test is not free in our country, only a small number of patients were tested.

More studies are needed in the future to validate pathognomonic signs as parameters for high-grade cervical lesions. In addition, it is important to make correlations between HPV and each sign or to study if the presence of these signs in low-grade lesions could indicate the progression of the lesion to a more severe lesion.

Colposcopy should be considered as a routine technique in daily practice, but the contradictory results from the literature regarding its accuracy suggests that its technique has yet to be improved. Pathognomonic signs -inner sign and ridge sign- have a good specificity in predicting high-grade cervical intraepithelial lesions, but unfortunately they are present in only 9,8%, respectively 20,5% of cases with high-grade cervical intraepithelial lesions.

The diagnostic accuracy of colposcopy needs improvement. The key element of colposcopic practice is the identification of the most abnormal area for biopsy. The subjectivity of colposcopy calls for advances in technology and qualitative measurement. New methods to increase the accuracy of the colposcopic diagnosis are required and several colposcopic improvements based mainly on modeling the acetowhitening reaction have been proposed, including digital colposcopy. These new methods use optical or electrical biosensors which, measure the altered appearance or electrical signature of dysplastic tissue compared to normal cervical epithelium while non-contact devices allow simultaneous visual assessment. Several devices are available for clinical practice but published data of performance are limited.

DySIS is a digital video colposcope that uses dynamic spectral imaging technology to evaluate acetowhitening images of the cervix in order to guide the colposcopist to the site of a possible biopsy. A colored grading of the acetowhite change is superimposed on a live color image of the cervix to help the colposcopist determine the presence and severity of an abnormality and assist in the selection of the site for biopsy (*Leeson, 2014*). DySIS therefore replaces the conventional colposcope and no further colposcopy is required. Several studies show promising results with DySIS assisted colposcopy (*Soutter et al., 2009, Louwers et al., 2015*). *Louwers et al.* showed increased sensitivity in the detection of high-grade cervical lesions either as a standalone investigation or in combination with conventional colposcopy. Unlike conventional colposcopy, the sensitivity of colposcopy with DySIS in low-grade cytology referrals was found similar to the sensitivity in high-grade cytology referrals. This study used the dynamic spectral imaging colposcopy

machine for standard colposcopy examination, relying on the observations of a trained colposcopist (*Louwers et al., 2015*). In this study, DySIS colposcopy had a higher sensitivity (82%) than conventional colposcopy with regard to distinguishing between normal and abnormal tissues, even when referral criteria were changed. However, the device can inconvenience the examination sometimes, hindering a complete view of the transformation zone (especially in women with a retroverted uterus) or when there is an excess of blood or mucus in the cervix. Nonetheless, one of the largest studies on DySIS reported increased detection of CIN2+ and showed improved efficiency of the DSI-assisted biopsies (*DeNardis et al., 2017*).

ZedscanTM (Zilico Ltd, Manchester) is a contact method using an electrical impedance spectroscope. It provides an objective assessment of the impedance profile of cervical epithelium in order to guide the colposcopist to the site of any colposcopic biopsy. Electrical impedance spectrometry can be used to distinguish between differing tissue types. The Zedscan examination is performed after application of acetic acid but prior to colposcopy. A realtime electrical impedance spectrometry can guide the colposcopist to perform a directed punch biopsy. Tidy et al. studied the role of Zedscan in improving the diagnostic accuracy of colposcopy predicting high grade CIN, when Zedscan is used as an adjunct (*Tidy et al., 2013*). They examined 474 women with Zedscan and thereafter with colposcopy. Zedscan showed increased positive predictive value with sensitivity equivalent to colposcopy from 54% (95% CI 45–62) to 67% for predicting high grade CIN ($p = 0.0006$). The conclusion was that Zedscan improved clinical performance of colposcopy and could lead to less intervention.

LuViva Advanced Cervical Scan (Guided Therapeutics, Norcross) uses multimodal hyperspectroscopy for the diagnosis of cervical abnormalities. Fluorescence spectroscopy may help identify metabolic alterations in dysplastic tissue. Epithelia with different characteristics of nuclear density, thickness and neovascularization provide a different reflectance signature compared to normal epithelium, and this can be measured. The procedure is easy to perform, provides objective results in real time and does not require a tissue biopsy, which is a major advantage. A large-diameter probe is mounted on a vaginal speculum. The probe is connected to a light source and a camera for the detection of emitted and reflected light. All measurements are taken in about one minute and images are available in case of planned colposcopy and biopsy (*Leeson 2014*).

All these methods can be used in low resource contexts and for screening, especially where the quality of cytology may be poor. Although they provide encouraging results, improvements in a number of areas are still necessary, such as the time it takes to process the full digital image of the cervix, the performance of the computing systems used to identify different kinds of tissues, and biopsy sampling. At the same time, it is important to acknowledge that these technologies have only been used on a small scale and relevant research is currently limited, so their role in current practice is not yet well defined. Computer-assisted imaging systems might someday replace colposcopy. Nonetheless, such techniques are unsuitable for lesions extending onto the vagina or beyond the view of the colposcopist into the endocervical canal, which is why colposcopic skill and basic training remain important.

1.2.3. THE MANAGEMENT OF PRENEOPLASIC CERVICAL LESION AND CERVICAL CANCER

1.2.3.1. BACKGROUND

The appropriate management of women with preneoplastic cervical lesions is a critical component of cervical cancer prevention programs. CIN is a relatively common problem, especially in women of reproductive age. Proper management should follow the diagnosis of a cervical lesion in order to prevent the development of a cervical cancer. The protocols for each type of CIN have been developed and updated over the years due to the implementation in clinical practice of HPV tests or molecular markers.

Traditionally, prior to colposcopy, all lesions used to be treated by knife excisional cone biopsy or by ablative radical point diathermy. Cold knife excision of a wide and deep cone of the cervix is however associated with significant short and long-term morbidity (peri-operative, primary and secondary haemorrhage, local and pelvic infection, cervical stenosis and mid-trimester pregnancy loss). Nowadays, various more conservative local ablative and excisional therapies can be performed in an outpatient setting. Current treatment options for CIN, whether by ablative or excisional methods, depend on the nature and extent of disease.

The management of low-grade CIN has been modified significantly in the last years. According to the 2012 Consensus Guidelines by the American Society for Colposcopy and Cervical Pathology (ASCCP), CIN1 should be managed conservatively because most CIN1 cases regress within a few years (*Moscicki et al., 2004*). In contrast, CIN3 is considered to be an immediate precursor to invasive cancer, and generally warrants appropriate treatment such as excision or ablation. Inappropriate management of CIN3 results in significant progression to invasive cervical cancer. In case of CIN2 disease the dilemma management appear from the observation that regression rates are higher and progression to cancer less common for women with CIN2 than for those with CIN3 (*Holowaty et al., 1999*). The reported risk of progression from CIN2 to CIN3 is 25% over 5 years (*Holowaty et al., 1999*).

According to the new ASSSCP guidelines from 2006, cytological follow-up is recommended, regardless of the outcomes of the colposcopic examination. Excision or ablation of the transformation zone is equally effective in addressing an initial diagnosis of CIN 2 or 3 in women with satisfactory colposcopy and no signs of micro-invasive or invasive disease. Available treatments include: cryotherapy, large loop excision of the transformation zone (LEEP/LLETZ), and cold knife conization. The main determinant for cure of CIN 3 is complete excision or destruction of the lesion. For women with CIN2/CIN3 and adequate colposcopy, both cervical excision and ablation are acceptable treatment modalities, except in pregnant women and young women. For women with unsatisfactory colposcopy or suspicion of micro-invasion, a diagnostic excisional procedure is recommended. Observation or deferred treatment may be acceptable for CIN2 in adolescents with satisfactory colposcopy and negative endocervical sampling.

Ablative procedures do not remove the tissue, but instead destroy it in situ; therefore, no histological specimen is available neither for definitive diagnosis nor to reveal a cancer that needs additional follow-up and care. Excisional treatments remove all or part of the cervix; pathologists can evaluate the excised tissue and render final histological diagnosis.

Although cervical vaporization (ablation) could be a less invasive substitute

for LEEP or conization, its potentially unfavorable oncologic outcome is of significant concern in CIN3. Ablation therapy is appropriate for lesions that involve less than 75% of the cervix, do not extend into the endocervical canal or onto the vagina, and are not suggestive of invasive cancer. In low- resource settings women are treated most often by ablation therapy instead of excisional procedures.

Cryotherapy is another ablative technique, is easy to use, cheap and associated with low morbidity. It should be considered a viable alternative for the treatment of low-grade disease, particularly where resources are limited. The evidence from the 29 RCTs identified suggests that there is no overwhelmingly superior surgical technique for eradicating CIN. Cryotherapy appears to be an effective treatment of low-grade disease but not of high-grade disease (*Martin-Hirsch et al., 2013*).

Ablation techniques are acceptable for women with CIN3 and adequate colposcopy, but unacceptable for women with CIN3 and inadequate colposcopy or endocervical sampling showing CIN2, CIN3 and ungraded CIN; thus excision is recommended for such women.

Low morbidity excisional techniques (laser conisation or large loop excision of the transformation zone) are now preferred to destructive ablative ones. The main advantage of excisional methods is that they can facilitate the grading of neoplasia (low-grade/ high-grade) and, at the same time, provide complete excision of the transformation zone. These are important considerations because incomplete excision of the transformation zone is a significant indicator of patients at risk of treatment failure or recurrence of disease. Excisional treatment is mandatory for a patient with unsatisfactory colposcopy results and a suspicion of invasion or glandular abnormality. Previously, management depended on whether or not colposcopy results were satisfactory, and treatment via ablative or excisional methods was acceptable for all women with CIN1.

Large loop excision of the transformation zone (LLETZ) or LEEP (loop electrosurgical excisional procedure) is performed with a wire loop electrode on the end of an insulated handle is powered by an electrosurgical unit. The current is designed to achieve a cutting and coagulation effect simultaneously. The procedure can be performed under local analgesia. Laser conisation takes longer to perform, requires greater operative training and more expensive investment in equipment. A disadvantage of laser conisation is that the cone biopsy specimen might suffer from thermal damage, making histological evaluation of margins impossible. Because of these disadvantages the use of LLETZ in clinical practice may be preferred to laser excision. In this situation, a narrow and deep cone biopsy can be performed, reducing tissue trauma and providing a clear resection margin (*Martin-Hirsch et al., 2013*).

Knife cone biopsy still has a place if invasion or glandular disease is suspected. In both diseases adequate resection margins that are free of disease are important for prognosis and management. In such cases, LLETZ or laser conisation can induce thermal artefact so that accurate interpretation of margins is not possible (*Martin-Hirsch et al., 2013*).

A method for the management of abnormal Pap smear, alternative to the traditional protocol (cytology, colposcopy, biopsy, and histological confirmation of CIN), is to use a 'screen-and-treat' approach in which the treatment decision is based on a screening test, and treatment is provided soon or, ideally, immediately after a positive screening test. This approach is supposed to reduce the medical visits and is recommended in countries with low income.

Within the direction of researches on management of cervical lesions I have published one original article evaluating the “see-and-treat” approach in women with cervical high-grade squamous intraepithelial lesions. This study was undertaken to evaluate if “see and treat” management in women with HSIL Pap smear represent a good medical practice in our medical facility. Also I published two clinical cases with rare pathologies encountered during my practice in the field of cervical pathology. The first one is a carcinosarcoma, a rare, extremely aggressive tumor of the uterus with a poor prognosis and the other article presents a case series of giant cervical polyps.

Published papers:

1. **Grigore M**, Teleman S, Terinte C. Evaluation of “see-and-treat” approach in women with cervical high-grade squamous intraepithelial lesions, *Giornale Italiano di Ostetrica e Ginecologia*, 2012; 34:192-194.
2. **Grigore M**, Ilea C, Terinte C, Sava A, Popovici R. Heterologous Type of Malignant mixed mullerian tumor of the uterus presenting as a vulvar mass. *Eur J of Gynaecol Oncol* 2014; 35: 458-460. **IF 0,89**
3. **Grigore M**. Giant cervical polyps: three cases with different pathologies, *J Obstet and Gynaecol* 2014; 3:1-2. **IF 0,28**

I.2.3.2. Material and methods

- ***Evaluation of “see-and-treat” approach in women with cervical high-grade squamous intraepithelial lesions***

We perform a study on 75 cases with a cytological diagnosis of HSIL on the Pap smear. Exclusion criteria were any proven genital malignancy, being a candidate for hysterectomy for any indication, severe vaginal infection, and pregnancy, a delivery in the 3 previous months, a bleeding disorder, or a recent cervical electrocauterization. All the patients had a colposcopic examination and severity on colposcopy was graded using the ASCCP guidelines. We divided these patients in two groups and we applied two different management approaches. In the first group (39 patients) we used the one step “see and treat” management of the lesion and a second group (36 patients) on which we performed biopsy followed by LEEP or conization when necessary (depending on the result of the biopsy). We compare thereafter the results of the pathology reports and in order to discover if the “see and treat” management is not an overtreatment in some cases. In group two we performed 34 LEEP based on the results from the pathology department. The patients presented for follow-up visits at the outpatient clinic 2 weeks, 6 months, and 1 year after the procedure to undergo Pap smear, colposcopy, and colposcopically- directed biopsy when the colposcopic examination was not satisfactory. The first visit allowed an early evaluation of the procedure, the detection of any complications, and an evaluation of the patient's satisfaction. The later visits allowed the detection of residual or recurrent lesions.

- ***Rare cervical pathological conditions***
 - *Heterologous type of malignant mixed mullerian tumor of the uterus presenting as a vulvar mass*

Carcinosarcoma is a rare tumor of the uterus, extremely aggressive, with a poor prognosis. We present a homologous type of malignant mixed Mullerian tumor of the uterus that presented as a giant mass protruding through the cervical, vagina and vulva.

- *Giant cervical polyps: three cases with different pathologies*

Giant polypoid masses greater than 4 cm are rare, and until now, only several cases have been described in the literature. We present three cases of large polyps observed at the cervical os of the uterus with different pathologies: cervical polyp, endometrial polyp, and adenomyomatous polyp.

1.2.3.3. Results

- ***Evaluation of “see-and-treat” approach in women with cervical high-grade squamous intraepithelial lesions***

The pathological results are presented in table 14. The complications appeared during or after the procedures are presented in table 15. The histopathological report shows CIN II, III or CIS in 67 cases (89,3%). In 8 cases (10,6%) the diagnosis was CIN I or chronic cervicitis. Among these 8 patients, 4 belonged to group 1 and 4 to group 2, so there was no significant difference of overtreatment between the two groups. In group 2 in 34 cases the pathology report from the colposcopic guided biopsy indicates a high-grade lesion and this result certifies the need for further LEEP or conisation. From the 34 cases with conisation in 2 cases the final diagnosis was CIN I. The median time length between the initial Pap smear and LEEP was significantly longer than between the initial Pap smear and biopsy. The histopathologic evaluation revealed that 4 patients (10,2%) in the subgroup 1 had been over treated, as they only had chronic cervicitis or CIN I.

The LEEP treatment was unsuccessful in 4 patients (5,1%), 2 (2,6%) in the LEEP subgroup of group 1 and 2 (5,8%) in the LEEP subgroup of group 2. Of those 4 patients, 2 had CIN 2 and the other 2 had CIN3, as evidenced on colposcopy and confirmed on histopathology.

Table 14. Pathological results

Pathology	CIN III, CIS	CIN II,	CIN I	Chronic cervicitis
Group1(39 patients)	10	25	3	1
Group 2 (36 patients)	8	26	2	0
Subgroup 2*(34 patients)	9	22	3	0

*Subgroup 2- patients with LEEP after guided colposcopic biopsy

Table 15. Complications during and after the procedure

Complication	Group 1(39 patients)	Group 2 (biopsy guided procedure 36 patients)	Subgroup 2 (LEEP after biopsy, 34 patients)
Bleeding during the procedure	2 cases	0	3 cases
Bleeding after procedure	1 case	0	2 cases
Injury to vaginal mucosa	0	0	1 case

- ***Rare cervical pathological conditions***

- *Heterologous type of malignant mixed mullerian tumor of the uterus presenting as a vulvar mass*

We present the case of a 78-year-old woman diagnosed with carcinosarcoma of the uterus. She came to the hospital because of a large tumoral mass protruding through her vagina. She was not able to specify the time she first observed this mass. The patient (weight, 64 kg; body mass index, 25) had no pathological antecedents. She came to the hospital because of a large tumoral mass protruding through her vagina. She was not able to specify the time she first observed this mass. The patient (weight, 64 kg; body mass index, 25) had no pathological antecedents. Clinical examination revealed a large tumoral mass with areas of necrosis and hemorrhage (Fig. 6,7); the origin of this mass was the uterus. An initial biopsy revealed only necrosis. We performed a total abdominal hysterectomy with bilateral salpingo-oophorectomy. Because of the patient's critical condition and the high anesthesiologic risk, a bilateral pelvic lymphadenectomy and aortic lymphadenectomy were not performed. The histopathological analysis showed a heterologous malignant mixed mullerian tumor. The epithelial differentiation was endometrioid and poorly differentiated papillary serous carcinoma, and the mesenchymal component was rhabdomyosarcoma (Fig.8,9). After surgery, the patient was sent to the oncology unit.

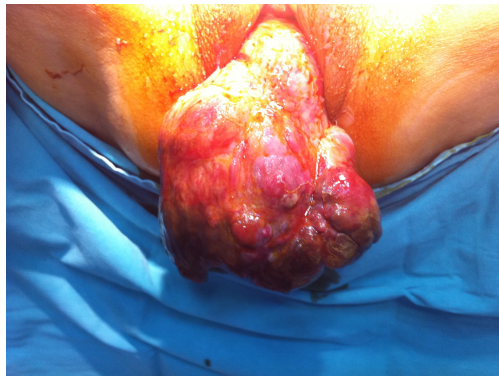

Fig.6 A large (15x15 cm) mass protruding from the cervix and the vagina.

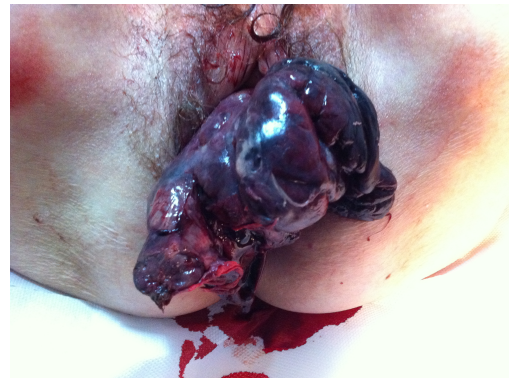

Fig.7 A large (15x15 cm) mass protruding from the cervix and the vagina.

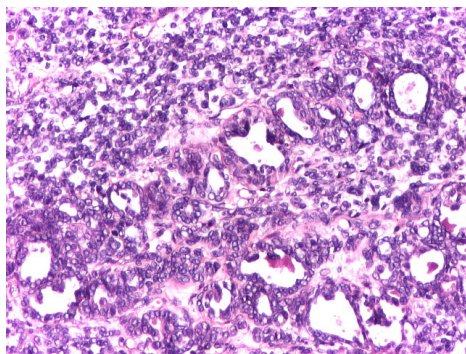


Fig. 8. Malignant mixed mullerian tumor – The transition between epithelial and mesenchymal components is subtle.

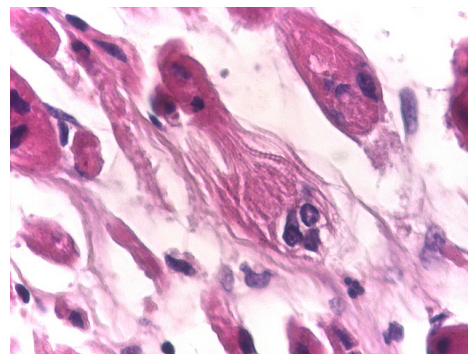


Fig 9. The heterologous component of the malignant mixed mullerian tumor: rhabdomyosarcoma.

➤ *Giant cervical polyps: three cases with different pathologies*

• **Case 1- Giant cervical polyp**

A 55-year-old, gravida 2 para 2, postmenopausal woman presented to gynecologic consult for abnormal vaginal bleeding. The patient described having intermittent vaginal bleeding for several weeks. A speculum examination revealed the presence of a large, pedunculated, polypoid mass, originating from the uterine cervix (Fig.10). Papanicolaou (Pap) smear was normal. Colposcopy showed a polyp covered by squamous epithelium with the base in the cervical canal. After the physical examination, the pre-operative diagnosis was cervical polyp. We performed an electrocoagulation polypectomy, and the lesion was resected. The pathological report confirmed a giant cervical polyp 6.5x3 cm (Fig.11). No recurrence appeared 6 months after the surgery.

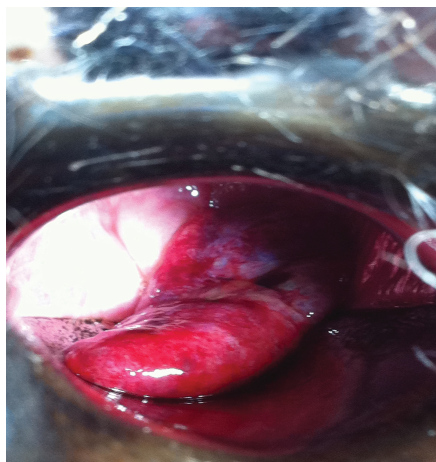

Fig. 10. Giant cervical polyp- large cervical polyp presenting at the cervical os.

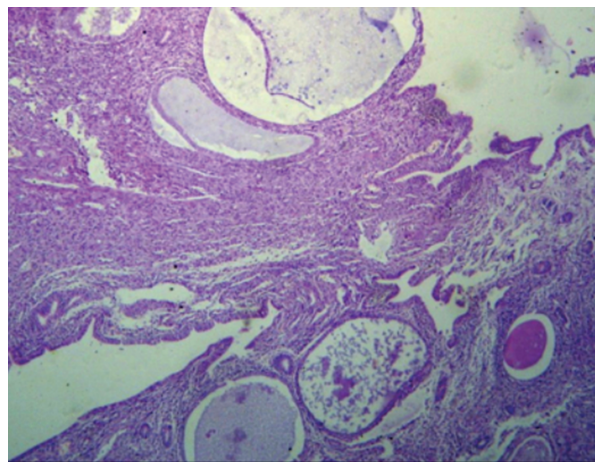


Fig. 11. Giant cervical polyp- microscopic view of the cervical polyp.

- **Case 2- Giant endometrial polyp protruding through the cervical os**

A 62-year-old, gravida 1 para 1, postmenopausal woman presented to gynecologic consult for intermittent vaginal bleeding. We performed a speculum examination and found a firm reddish mass protruding through the external os of the cervix about 40/30 mm. The Pap smear was normal, and colposcopy showed a large polyp covered by glandular epithelium. The base of the polyp was inside the cervical canal. The aspect of the cervix was normal, but the squamo-columnar junction was not visible. Endovaginal ultrasound revealed an endometrial thickness of 25 mm. The clinical findings and imagistic report suggested endocervical or endometrial polyp. We performed a hysteroscopy, which showed that the polyp was inserted at the uterine fundus, extended to the external cervical os, and protruded into the vagina. A hysteroscopic polypectomy was performed, and the base of the polyp was resected with scissors. The surgical specimen measured 80x30x30 mm (Fig. 12). Microscopically, the tumor was composed of multiple endometrial glands embedded in the stroma (Fig. 13). No nuclear or cytological atypia were noted, and no signs of dysplasia or neoplasia were observed in the glandular epithelium. No recurrence was seen 1 year after the surgery.

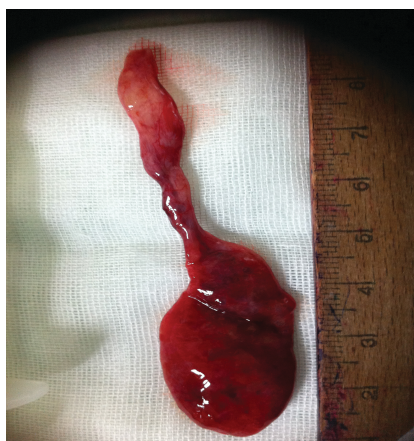


Fig.12. Giant endometrial polyp after hysteroscopic resection

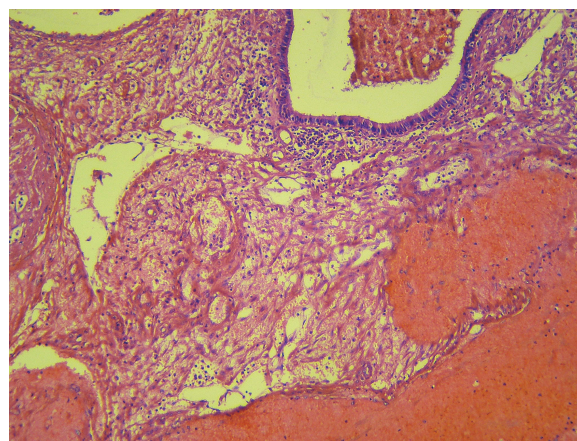


Fig.13. Giant endometrial polyp- microscopic view.

- **Case 3-Giant adenomyomatous polyp**

A 58-year-old woman, gravida 3 para 2 presented to the gynecologist because of vaginal bleeding. A speculum examination revealed a 50x40x35 mm cervical polyp and superficial bleeding on touch. Endovaginal ultrasound showed that the mass was 65x56x42 mm and was located in the cervical canal with two hypoechoic areas within it that suggested cervical fibroid degeneration. Endometrial thickness was 15 mm. Pap smear showed inflammatory changes. The presumptive diagnosis was cervical polyp, and elective surgical excision was recommended. Polypectomy was performed followed by fractional curettage. The core of the polyp revealed endometrioma-like blood content (Fig.14). Histologic examination of the polyp demonstrated endometrial glands with intervening smooth muscle fibers admixed with thick walled blood vessels. Most of the endometrial glands were small, although some showed dilatation. There was no mitotic activity in any of the examined slides. The pathologic diagnosis was adenomyomatous polyp of the endometrium (Fig.15).

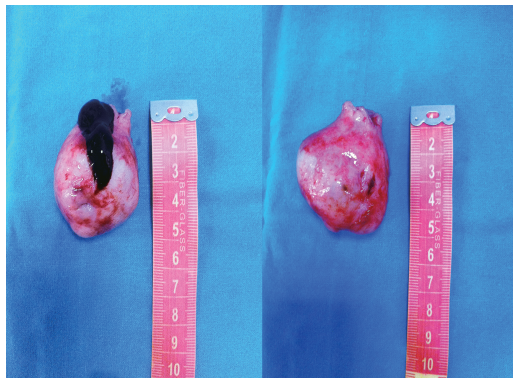


Fig. 14. Giant polyp adenomyomatous-macroscopic view.

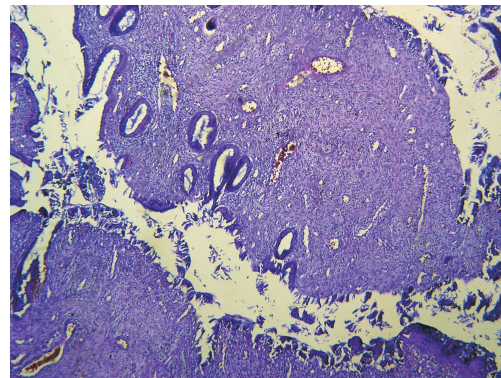


Fig. 15. Giant polyp adenomyomatous-microscopic view.

I.2.3.4. Discussion

- *Evaluation of “see-and-treat” approach in women with cervical high-grade squamous intraepithelial lesions*

Traditionally, the management algorithm of cervical precancerous lesions has involved multiple steps including initial colposcopy, followed by colposcopically-directed biopsy, and LEEP or conisation thereafter depending on the biopsy result. This protocol requires multiple visits and sometimes have decrease treatment efficacy due to poor compliance. In order to improve patient compliance, an alternative strategy using LEEP for cervical conization method without prior histologic diagnosis at the time of initial colposcopy, the so-called “see and treat” is proposed because it could reduce the number of visits compared with that of the traditional management. In our study we evaluated this approach for patients diagnosed with high-grade lesions on Pap smear. In the group where we apply "see and treat" approach, we had a 10,2% of overtreatment. However, we found no statistical difference between this finding and the 11.7% rate of non-high-grade results from the LEEP specimens in group 2, after high-grade results were obtaining from punch biopsies. Based on this

results we consider that “see and treat” represent a good attitude especially when is performed in patients who cannot afford regular medical controls. Our results agree with those of Numnum et al., who reported an overtreatment rate of 16%, with overtreatment defined as the excision of CIN 1 or lesser lesions (Numnum et al., 2005). Sadan et al. found no differences in final histologic findings between a 3-step protocol, in which LEEP was performed only if the results of colposcopically-directed biopsies were positive for CIN 2 and CIN 3, and a see-and-treat protocol, in which LEEP was immediately performed if CIN 2 or CIN 3 lesions were suspected on colposcopy (Sadan et al., 2007).

In conclusion, the “see and treat” policy using LEEP is an appropriate management in women with HSIL on Pap smear with an overtreatment rate of 5.8%. The incidence of overtreatment could be further reduced to 4.0% when such policy was strictly carried out in only premenopausal women.

The “see and treat” or one-step management is an immediate treatment of cervical precancerous lesions by loop electrosurgical excision procedure (LEEP) without intervening colposcopically-directed biopsy. This strategy provides several advantages including a permission of simultaneous histological diagnosis and treatment of cervical precancerous lesions resulting in reduction of either patient visit or time interval from diagnosis to treatment, a more accurate histological diagnosis due to a larger specimens than those obtained by cervical biopsy a decrease in cost and greater patient's convenience, thereby improving the compliance (Irvin et al, 2002, Dunn, Burke, Shwayder, 2003).

Many studies of this see-and-treat strategy have been performed and published in the literature in the last years. These studies show a broad range of overtreatment rates for suspected highgrade intraepithelial lesions. These differences in results appear because they included different patient groups, with wide ranges in age and referral cervical smear criteria, with different thresholds to perform a see-and-treat LEEP, and with a variety of excision techniques.

The overtreatment rate of this procedure varies between 11 and 35%. Also difference appears in the literature in defining the overtreatment. The most accepted definition (also used in our study) is the percentage of women undergoing treatment without the presence of a high-grade lesion (Ebisch et al., 2016).

Guducu et al compared the results of see-and-treat procedure with the classical three-step procedure in terms of initial cytology and LEEP reports. They include 116 patients in the study. Of the patients with ASCUS/LSIL cytology and a positive cervical biopsy 48.4% had CIN 2-3 at LEEP, in contrast only 19% of the patients without a prior cervical biopsy had CIN 2-3 at LEEP ($p=0.031$); there was no statistically significant difference between the 2 procedures in patients with a HSIL and ASC-H smear result ($p=0.726$ and $p=1.0$ respectively). The authors concluded that for cases with ASC-H and HSIL cytology see-and-treat approach seems more advantageous, avoids delay in treatment, noncompliance and risk of skipping lesions at biopsy (Guducu et al, 2013).

A recent systematic review and metaanalysis in order to determine overtreatment rates in see-and-treat management of women referred for colposcopy because of suspected CIN was performed by Ebisch RM et al in 2016 (Ebisch et al., 2016). They analyzed 13 studies of see-and-treat management of CIN. This review showed an overtreatment rate of 11.6% in the see-and-treat management of women with a high-grade smear and high-grade colposcopic impression. These figures are comparable with the two-step overtreatment rates reported in the literature, varying from 11 to 35%. In our study we find also an overtreatment rate of 10.2% and is

possible that this low rate of overtreatment to be correlated with the experience of the colposcopist.

The presence of 90% of CIN 2-3 in excised cones represent according to European Federation of Colposcopy a quality indicator. The EFC advise not to perform a see-and-treat strategy in borderline or mild dyskaryosis smears, and only use see-and-treat management in exceptional cases with low-grade cytological anomalies. In clinical practice it is important to take into consideration several factors like economic environment, or traceability of the patient.

Ebisch RM et al showed that in women with a discrepancy between the cervical smear and colposcopic impression, the overtreatment rate that is higher than the two-step overtreatment rate. This underline again how important is the expertise of the colposcopist. Making the difference between high- and low-grade CIN depends on the training and experience of the colposcopist (*Ebisch et al., 2016*). All this results favor the see-and-treat strategy in women with high-grade cytology, who also benefit from the additional advantages of undergoing a single procedure.

In clinical practice it is mandatory to avoid overtreatment because of the subsequent risk of morbidity (haemorrhage, infection, and cervical stenosis) associated with LLETZ or conisation. Also these procedures can increase the risk for premature labour as a result of cervical insufficiency.

In 2006 a meta-analysis performed by Kyrgiou et al suggested that pregnant women previously treated by LLETZ are at approximately twice the risk of a preterm birth than pregnant women in general. The author's conclusion was that all the excisional procedures to treat CIN present similar pregnancy-related morbidity without apparent neonatal morbidity. They recommend caution in the treatment of young women with mild cervical abnormalities should be recommended. Clinicians now have the evidence base to counsel women appropriately (*Kyrgiou et al., 2006*).

In a 2008 meta-analysis, women who became pregnant after undergoing cold knife conization and radical diathermy had increased risk of perinatal mortality, severe preterm delivery, and extreme low-birth-weight neonates, whereas LEEP was not associated with severe obstetric morbidity (*Arbyn M, 2008*). There are several mechanisms by which surgical excision could increase the risk of preterm birth: a mechanical weakening of the cervix, subtle histological changes in the healed cervix, affecting the tensile strength and impaired cervical antimicrobial mechanisms, such as mucus plug formation, allowing microbial access to the uterine cavity (*Arbyn et al., 2008*).

A recent meta-analysis found a much lower relative risk and no association after adjusting for confounding factors (*Conner et al., 2014*). *Castanon et al* suggests that the increased risk may be associated with large excisions alone (10–14 mm, and particularly >15 mm). Excisions of less than 10 mm in length appear to have, at most, minimal affect on the risk of preterm births (*Castanon et al., 2014*). In case of a large excision women should be informed about their future risk of adverse pregnancy outcomes, particularly preterm birth.

Decision to recommend see-and-treat LEEP should be individualized based on the risk for CIN2+, patient adherence to follow-up visits, and balancing overtreatment with the likelihood of spontaneous regression. Nowadays it is important to integrate in the management of cytological abnormalities the results of HPV infection. Future directions for research should focus on optimizing risk-assessment strategies of CIN3+ to better identify candidates for see-and-treat LEEP and minimize overtreatment rates. Both HPV test and molecular markers are powerful tools that will be helpful in assessing the patient with high-risk for CIN3. Because of the vaccination

programs in the future we will assist to a decrease in HPV16/18 infections and other less oncogenic high-risk HPV types will become more dominant among women with HSIL cytology, increasing the risk of overtreatment. In this context it is mandatory to increase the accuracy of colposcopy using new colposcopic devices like digital colposcopy, spectroscopy. Future directions for research will be to study to overtreatment rate using these new technologic acquiring in the field of colposcopy.

Also it will be interesting to perform research on how the introduction of new colposcopic devices (digital colposcopy, spectroscopy) will impact the see and treat management of cervical lesions.

- ***Rare cervical pathological conditions***

- *Heterologous type of malignant mixed müllerian tumor of the uterus presenting as a vulvar mass*

Carcinosarcoma is a rare, extremely aggressive tumor of the uterus with a poor prognosis. It is predominantly identified in postmenopausal woman (median age 65), but it can also be found in young women or children (*Bansal et al., 2008*). Carcinosarcomas and carcinomas of the uterus have similar risk factor profiles. Their incidence increases in association with marked obesity, which generates increased exposure to estrogen hormones; nulliparity; use of exogenous estrogen; treatment with tamoxifen (for breast cancer) and pelvic radiation. None of the risk or protective factors was found in our patient. Uterine carcinosarcomas typically present with abnormal vaginal bleeding and also may present with bloody discharge, watery discharge, abdominal pain, or an abdominal mass. Carcinosarcoma usually develops as a large, soft, polypoid mass, filling and distending the uterine cavity. In our case, the tumor was very large (15 cm) and protruded outside the vagina through the cervical os. Histologic examination of standard hematoxylin and eosin-stained sections showed the two components of carcinosarcoma: malignant-appearing epithelial and stromal (mesenchymal). These two morphologies can be intimately admixed or may appear as distinct components. The epithelial malignant tissue can have the appearance of any of the malignant epithelial neoplasms encountered in the female genital tract: serous, endometrioid, clear cell, mucinous and squamous patterns. Of these patterns, the most frequent one encountered is serous (*Kernochan, Garcia, 2009*).

Genetic and molecular data provides evidence of a monoclonal origin of most carcinosarcomas. The arguments for this monoclonal origin are the presence of similar chromosomal aberrations, concordant loss of heterozygosity, identical *p53* and *K-ras* mutations, and matching X inactivation patterns in both histologic components of most carcinosarcoma cases studied (*Jin et al, 2003*).

Additionally, the specific patterns of genetic aberrations are more consistent with a high-grade carcinoma than a sarcoma, providing strong support for divergent differentiation within a primarily epithelial neoplasm (carcinoma) as the histogenesis. Although the theory of being monoclonal or biclonal is under investigation, the clinical implication of this fact is unknown. The carcinomatous component has been shown to have more aggressive behavior and be a better predictor of clinical outcome in carcinosarcomas. The carcinosarcoma evolution is unfavorable, even if it is identified and treated in the initial phases. The recurrence or survival do not correlate with the patient age and the histological type of the tumor (homologous or

heterologous) (Temkin et al., 2007).

In a few cases described in the literature the carcinosarcoma was associated with uterine inversion and in these cases prolapsed tumor can appear as isolated vaginal or cervical mass, mimicking cervical malignancy. The uterine inversion makes the diagnosis more challenging. Moreover the exposed tumor outside the vagina can be necrotic and this can complicate the histologic diagnosis. Also the surgical approach can be difficult because of changes in normal anatomy (Kean, Altman, 2019).

Recent data have advanced understanding of the biology of this lesion, and clinical trials are underway to determine the most efficacious chemotherapeutic regimens. Adjuvant chemotherapy decreases the rate of both pelvic and extrapelvic recurrence at the same time, although there is no recommendation for the optimal chemotherapeutic agent. Multimodal therapy should lead to better outcomes. Recently there are many ongoing studies with biologic and target therapies to improve efficiency, however, the relevant results will be disclosed in many years only, due to the small number of patients (Kalincsak et al., 2019).

In one of the largest series published in the literature the recurrences rate was 27.3% and the most common sites were the lymph nodes and the pelvis). In this study of 44 cases with uterine carcinosarcoma the surgical management consisted in total abdominal hysterectomy and bilateral salpingo-oophorectomy. Twenty-five percent had omental resection and Pelvic lymphadenectomy was performed in 18.2% of the cases. Twenty-six of the patients presented with stage I/II disease, 17 with advanced stages. In 20.5% of the cases there were metastases at diagnosis. Forty women received adjuvant chemotherapy, with complete remission in 67.9% of the cases (Grasso et al., 2017).

However, due to the rarity of the tumour, most treatment recommendations are actually upon retrospective studies with a small patient population. Clearly, the establishment of a definitive role of treatment will depend on the analysis of randomized clinical trials.

➤ *Giant cervical polyps: three cases with different pathologies*

The presence of a cervical polypoid mass at the cervical os is a common gynecologic finding. Usually, these polyps are small, less than 2 cm. Giant polypoid masses greater than 4 cm are rare, and until now, only several cases have been described in the literature (Bucella, Frédéric, Noël, 2008). We describe three different histologic types of polyps that presented at giant sizes: cervical polyp, endometrial polyp protruding through the cervical os, and adenomyomatous polyp.

Cervical polyps are relatively common and have focal hyperplasia of the endocervical columnar epithelium. They occur more frequently in multiparous women in the fifth decade of life. Usually the polyps' size does not exceed 1-2 cm, and very large cervical polyps more than 4 cm are rarely reported. A literature search reveals no more than 15 cases of giant cervical polyps reported in the last 20 years. Giant cervical polyps are usually symptomatic, with symptoms of increased vaginal discharge and intermittent bleeding. In this case, the patient presented to consultation because of intermittent vaginal bleeding. Cervical polyps are exceptionally associated with a malignant pathology (Namazov et al., 2019). Recently, some authors analyzing the potential of malignant transformation recommended that not all but only the symptomatic polyps or cases with abnormal cervical cytology be removed (MacKenzie et al., 2009). In the reported cases of giant cervical polyps, no

malignancy has been described. The malignant potential of giant cervical polyps may well remain elusive because of their rarity. In the literature, one case of a giant cervical polyp was reported with cartilaginous and osseous metaplasia (*MacKenzie et al., 2009*). In most cases the polypectomy is simple. However, cases of sessile polyps could pose some challenges.

Endometrial polyps are a common gynecologic problem with focal hyperplasia of the endometrial basal layer that develop into benign, localized overgrowth covered by epithelium and contain glands, stroma, and blood vessels. Endometrial polyps occur in all age groups, but are most commonly found in women between 40 and 49 years of age (*Droegemueller, 2001*).

The etiology of functional endometrial polyps is considered to be related to estrogen stimulation. Endometrial polyps may be divided into those that appear to be responsive to ovarian hormones and those that are not responsive (functional and non-functional polyps, respectively). There is an association between tamoxifen use, endometrial polyp formation, and endometrial carcinoma. The low expression of the antiapoptotic marker survivin in tamoxifen polyps but high expression in other polypoid endometrium explains different pathogenetic mechanisms (*Gokmen Karasu et al., 2018*). Endometrial polyps are a common cause of vaginal bleeding in pre- and postmenopausal women. The clinical appearance of an endometrial polyp ranges from a slightly rounded protuberance of the endometrium to a large, broad-based or pedunculated, oval structure filling the uterine cavity. Occasionally, they may expand into the cervical canal and present at the cervical os. Usually, they are less than 2 cm. Endometrial polyps greater than 4 cm, or giant polyps, are rare and usually contained into the uterine cavity. Giant endometrial polyps usually occur secondary to high estrogen levels or tamoxifen therapy after breast cancer. In our case 2, the polyp originated in the uterine cavity, extended into the cervix, and protruded into the external cervical os. The polyp had developed during menopause, spontaneously, as the patient had not received hormonal replacement therapy or tamoxifen therapy. Some authors recommend follow-up alone for women with asymptomatic uterine polyps, particularly those who are pre-menopausal. At the same time gynaecologists should consider risk factors such as age, obesity, polycystic ovarian syndrome, and diabetes in the management of endometrial polyps (*Jiang et al., 2019*).

Polypoid adenomyoma, also known as adenomyomatous polyp, is a rare subtype of endometrial polyp consisting of smooth muscle, endometrial glands, and often-scant endometrial stroma. It is still not clear whether adenomyomatous polyp is a variant of adenomyosis, endometriosis, or whether it is truly neoplastic (*Gilks et al., 2000*). Grossly, they appear no different than ordinary endometrial polyps. Transvaginal ultrasonogram can be used to diagnose adenomyomatous polyp. The characteristic sonographic features of polypoid adenomyomas include heterogeneous or homogeneous isoechogenicity relative to the myometrium, a smooth surface, a poorly defined margin with the underlying myometrium, hemorrhagic foci, posterior shadowing, a single vascular pedicle entering the mass, and associated adenomyosis in the myometrium (*Lee et al., 2004*). Three distinct sonographic patterns have been identified with respect to the presence of cystic areas: a solid mass, a solid mass with cystic areas, and a predominantly cystic mass (*Lee et al., 2004*). The adenomatous polyp should be differentiated from atypical polypoid adenomyoma, in which the glandular component demonstrates significant atypia and the smooth muscle component is large, and adenosarcoma, which consists of benign glands with a malignant stroma and can be grossly polypoid. The particular feature in our case was the polyp size and its protrusion through the external cervical os.

All three cases of giant polyps presented with intermittent vaginal bleeding, and all three patients were post-menopausal. For each, the clinical examinations revealed large polypoid masses presenting at the cervical canal. The base of the polyp was detected by clinical examination and by colposcopy in one of the three cases. In all cases, the final diagnosis was established by pathological examination, and the excision of the mass was mandatory. Uterine myoma is a common differential diagnosis for cervical polyps protruding at the cervical os. Other rare benign causes of cervical mass reported in the literature are angiomyoma of the cervix. The main differential diagnoses that should be considered with malignant pathologies include cervical cancer, cervical embryonal rhabdomyosarcoma, adenosarcoma, endocervical or endometrial adenosarcoma, and cervical lymphoma.

In summary, large polypoid masses observed at the cervical os may come from the uterine cervix or uterine cavity. The symptoms of these different types of polyps are quite similar. The clinical aspect is not relevant to establish the origin. In cases of adenomyomatoid polyps, the ultrasound anechogenic image inside the polyp could provide a clue to the diagnosis. Even if all cases of large cervical polyps reported are benign, their size and clinical aspect could mimic a malignant lesion. In all cases, the giant polyp has to be excised to determine the definitive histological diagnosis.

I.3. STUDIES IN MINIMALLY INVASIVE SURGERY IN GYNECOLOGY

I.3.1 INTRODUCTION

In the past, major surgical options for gynecologic were limited to abdominal and vaginal surgery. Over the last twenty years, gynecologic surgery has evolved from the abdominal approach to the current focus on minimally invasive surgical techniques. The main advantages of laparoscopy compared to open procedures are faster recovery and fewer wound complications, while the main disadvantage is a longer learning curve for the surgeon (*Walker et al., 2009*). Practical advances with improved endoscopic instruments and suturing skills allow us multiple choices and possibilities.

Single-port laparoscopy and natural orifice transluminal endoscopic surgery are other variations of laparoscopic technology. Laparoscopic technology and equipment have evolved to include multiple vessel-sealing instruments with “wristed” capabilities and robotic-assisted technology. One of the more significant recent advances came with the development of robotic surgery in 2005, when the DaVinci robotic system was introduced in clinical practice. Robotic-assisted surgery is a laparoscopic surgical approach with several advantages: three-dimensional camera, improved physician ergonomics, and a certain freedom of hand movement providing accurate instrument control. Robotics’ main drawbacks in surgery are the loss of haptics and increased costs (*Vislo, Advincula, 2008*). Robotics, however, removes many of the negative effects of laparoscopic surgery, such as lack of ergonomics, amplified tremor by surgeon, two-dimensional camera and the range of motion limited to four-degrees. While proper training with robotics is necessary, the above-mentioned benefits facilitate faster learning compared to straight-stick laparoscopy.

Minimally invasive surgery in gynecology includes vaginal and laparoscopic approaches. Hysteroscopy has evolved rapidly in the last years. The development of hysteroscopic instruments and techniques has been influenced by many factors, such as considerations of safety, convenience of use, possible treatment, procedure invasiveness, anesthesia requirements and hospitalization time. For hysteroscopic procedures, updates in smaller high-definition cameras and monitors, digital wireless transmission and telemedical communication will likely make hysteroscopic procedures easier to perform and with less discomfort for the patient. Ambulatory hysteroscopy has major benefits both for the patient and the diagnostic procedures. Combining ultrasound and hysteroscopy at the same time, allows to reduce the time of ambulatory surgery while upholding accessibility for all diagnostics and also up to 90 % of all hysteroscopic operative interventions, thus increasing patient satisfaction and safety (*Campo et al., 2014*). The so-called “see & treat hysteroscopy” is a new concept of a single procedure in which the operative part is perfectly integrated within the diagnostic work-up (*Campo et al., 2018*).

Moreover, resectoscopic procedures have become increasingly common, as bipolar diathermy has advanced. The risk of water intoxication has disappeared owing to the use of NaCl instead of mannitol, sorbitol or glycine. At present, operative hysteroscopy includes: endometrial biopsy, resection of the endometrial polyp, resection of the submucous myoma, resection of the placenta remnants, lysis of intrauterine adhesions, extraction/management of the foreign body/intrauterine

device, resection of the uterine septum (hysteroscopic metroplasty), hysteroscopic sterilization and endometrial ablation.

Over the last 30 years, despite significant technological advances in surgical equipment and energy sources, the laparoscopy is still underused for both benign and malignant gynecologic diseases. For example in USA, in 2003 only 12% of hysterectomies were performed laparoscopically and by 2005, this rate increased marginally to 14% (Jacoby *et al.*, 2009). Open surgery is still widely used because of the challenges associated with minimally invasive approach. Laparoscopy has a steep learning curve and not all gynecologic surgeons had access or training (Starr, Wagstaff, 2006). Technological advancements typically come at increased cost and this especially in case of robotic-assisted surgery.

Robotic-assisted surgery has several advantages: 3-dimensional visualization, wristed instruments with increased range of motion, improved ergonomics, enhanced surgeon comfort, and the ability to perform more difficult procedures. It was quickly adopted for use in hysterectomy, myomectomy, sacropey, and cancer staging procedures and become popular particularly among surgeons not adept at standard laparoscopy (Visco, Advincula 2008).

Despite the availability of robotic assisted surgery for gynecologic procedures for more than a decade, only 7 randomized trials comparing robotic assisted surgery with standard laparoscopy have been conducted to date. Four trials have evaluated outcomes for benign hysterectomy. Four trials have evaluated outcomes for benign hysterectomy (Martinez-Maestre *et al.*, 2014). Overall, these trials demonstrate that surgical expertise continues to play a much greater role than technology itself and that with equal experience with both modalities, robot surgery is not less efficient.

Minimally invasive surgery plays an important role in the field of gynecologic oncology and has now become the standard of care for many early-stage malignancies. Radical hysterectomy represent the standard of care for the treatment of early-stage cervical carcinoma (FIGO stage IA2-IB1) and for decades, this procedure has been performed via laparotomy. The first total laparoscopic radical hysterectomy with pelvic and para-aortic lymph node dissection for early-stage cervical carcinoma was reported in the literature in 1992 (Nezhat *et al.*, 1992). Thereafter, several retrospective reported laparoscopic radical hysterectomy to be safe, feasible, and have a favorable morbidity profile over the traditional abdominal radical hysterectomy (Abu-Rustum *et al.*, 2003, Toptas, Simsek, 2014, Ditto *et al.*, 2015).

However surgical management and potential refinement of surgical techniques in cervical cancer is important. The question of the utility of minimally invasive surgery for patients with a cervical cancer is nowadays under a debate after the study published in 2018 by Ramirez *et al.* (Ramirez *et al.*, 2018). In a multicentric randomized control trial, performed on 319 patients, mostly with stage IB1 disease, minimally invasive radical hysterectomy was associated with lower rates of disease-free survival and overall survival than open abdominal radical hysterectomy among women with early-stage cervical cancer (Ramirez *et al.*, 2018).

In contrast to cervical cancer, where is still a debate regarding the place of laparoscopy, in endometrial cancer there are randomized data that proved the safety and feasibility of the laparoscopic approach in the management of early-stage disease. A landmark study was represented by a randomized controlled trial comparing laparoscopy to laparotomy for management of clinical stage I to IIA endometrial cancer was published in 2009. In this trial laparoscopy was associated with improved short-term surgical outcomes, fewer complications, and shorter hospital stay. Of note, intraoperative complications were equivalent; however, 26% of laparoscopy patients

required conversion to laparotomy with poor visualization being the most commonly cited reason (57%), followed by disease requiring laparotomy for resection (16%) and bleeding (11%). (*Walker et al., 2009*). A Cochrane systematic review, performed in 2012 which included 8 studies concluded that laparoscopy is associated with lower blood loss, less operative morbidities, and postoperative complications as well as faster recovery than laparotomy in early-stage endometrial cancer. Disease-free and overall survival were similar in the 2 groups indicating that laparoscopy should be the preferred surgical modality for the treatment of early-stage endometrial cancer (*Galaal et al., 2012*).

Laparoscopic endoscopic single-site surgery (LESS) was developed principally with the goal to improve cosmesis and reduce postoperative pain. The procedure is performed through a single skin incision, most commonly at the umbilicus, through which a multichannel port is introduced. It is a technology that is possibly better suited to procedures in a smaller surgical field such as the oropharynx. The major technical challenge with LESS is the close proximity of the surgical instruments and the loss of triangulation that is afforded by standard laparoscopy.

Endometrial ablation, a surgical procedure aiming to decrease or control heavy menstrual bleeding, is generally intended for premenopausal women who are not candidates for medical therapy or for whom other treatments have failed. Along with the classic resectoscopic endometrial ablation (considered a first generation technique), ‘second-generation’ methods are available nowadays, such as cryoablation, microwave ablation, laser, thermal balloon and photodynamic therapy. They all have both advantages and disadvantages and, at the moment, the best method for endometrial destruction is still a matter for debate. This has stimulated my interest in the field of endometrial ablation and prompted me to conduct a Cochrane systematic review on the subject.

Within the direction of researches on 3D ultrasound in obstetrics, I have published 3 articles (original research articles, review articles and case reports) in journals indexed in ISI Web of Science, a number of 5 articles in journal indexed in other international databases and 2 abstracts in ISI Journals with FI.

Published papers:

1. Bofill Rodriguez M, Lethaby A, **Grigore M**, Brown J, Hickey M, Farquhar C. Endometrial resection and ablation techniques for heavy menstrual bleeding. *Cochrane Database Syst Rev* 2019; 22;1: CD001501. **IF- 7,66**
2. **Grigore M**, Blidaru I, Iordache F. Intrauterine foreign bodies, other than contraceptive devices and systems, may affect fertility – Report of two very different cases, *Eur J of Contracep Reprod Health Care* 2014; 19:141-143. **IF- 1,394**
3. **Grigore M**, Iordache F. Laparoscopic removal of a giant ovarian cyst: case report and review of the literature, *Minerva Chirurgia*, 2014, 27: 47-49.
4. **Grigore M**, Gafitanu D, Esanu I, Carauleanu A, Ilea A, Popovici R Genital tuberculosis – a rare but still existing disease, *Clin and Experim Obstet Gynecol* 2018; 45: 620-621. **IF 0,404**

I.3.2. PRO AND CONS FOR ENDOMETRIAL ABLATION

I.3.2.1. Background

Medication and hysterectomy used to be the main treatment options for heavy menstrual bleeding (HMB). Both are still effective and safe options, but now there are available new treatments for removing the endometrium. These procedures involve either removing the endometrium (resection) or destroying it with thermal (heat) energy from a laser, electrical instruments, or other devices (ablation). These treatments can stop or reduce menstrual bleeding.

Women with benign heavy menstrual bleeding HMB have several options, either medical either surgical, to reduce their blood loss and improve quality of life. The role of the clinician is to provide information to facilitate women in making an appropriate choice.

Hormonal treatment of HMB is also endorsed as the first line of treatment in several international guidelines. The therapies include combined hormonal contraceptives, progestin-only preparations, and intrauterine release of levonorgestrel through the levonorgestrel-releasing intrauterine system (*Heikinheimo, Fraser, 2017*). Among them levonorgestrel-releasing intrauterine system is the best option, because adverse effect are minimal. A randomized control trial compared the use of LNG-IUS and cyclic oral progestin (10mg MPA/day on cycle days 16-25) among women with documented HMB. Treatment with LNG-IUS resulted in a mean reduction of 71% of measured monthly blood loss in comparison to 22% among women randomized for cyclic MPA; the treatment outcome was judged successful in 85% of the women randomized to LNG-IUS and in 22% of the women randomized to cyclic progestin (*Kaunitz et al., 2010*).

Gupta et al. performed a randomized study and compared LNG-IUS with hormonal and non-hormonal medical therapies (tranexamic acid, mefenamic acid, and combined preparations of estrogen and progestin or progestin-only) in the treatment of HMB. The LNG-IUS, compared with usual medical therapies, resulted in greater improvement over 2 years in women's assessments of the effect of HMB on their daily routine, including work, social and family life, and psychological and physical well-being (*Gupta et al., 2013*).

Hormonal medical treatments can be associated with hormonal side effects, prevention of fertility and lack of efficacy, leading to discontinuation of the treatment. Other medical options for HMB currently available to women are: antifibrinolytics, nonsteroidal anti-inflammatory preparations.

A particular category category is represented by woman with a history of thrombosis, or who is otherwise at high risk of thrombosis, or who takes medications for anticoagulation can present a challenge to health care providers. Hormonal therapy can be contraindicated in women with a history of thrombosis unless they are on anticoagulation. As 70% of women on anticoagulation experience HMB, successful management of HMB may involve a modification in the anticoagulation or antiplatelet regimen, hormonal therapy tailored to the patient's situation, and/or surgical therapy (*Rivara, James, 2018*).

Because of these side effects many women proceed to surgery due to treatment. Previously, surgery was represented by hysterectomy in order to cease the bleeding. However surgery can be associated with risk of bowel, bladder and ureteric damage, as well as haemorrhage, infection and even death. In the last years a novel approach have implemented in treating heavy menstrual bleeding. Endometrial ablation (EA), a minimally invasive technique for the management of AUB of benign origin was introduced in clinical practice. While hysterectomy still remains the definitive surgical treatment for HMB, endometrial ablation in contrast is less invasive, associated with shorter hospital stay and recovery, significantly less pain and fewer complications (*Cooper et al., 2011*).

Currently, there is a variety of endometrial ablation devices used worldwide, which are well-established alternatives to hysterectomy for the management of women with HMB. The endometrial ablation techniques can be classified in “first-generation” and “second-generation”.

The ‘first-generation’ techniques require direct visualization of the uterine cavity and include: include endometrial laser ablation (ELA), transcervical resection of the endometrium (TCRE) and rollerball endometrial ablation (RBEA). To ease the procedure and enhance the depth of destruction it is recommended to use endometrial-thinning agents before the procedure like danazol and gonadotropin-releasing hormone analogs. There are several studies in the literature that compare these techniques with hysterectomy, which is considered the gold standard. These techniques have been extensively evaluated against the gold standard hysterectomy and shown to be effective, minimally invasive alternatives to control HMB with fewer complications (*Lethaby, Hickey, 2002*).

“Second-generation” devices such as thermal balloon endometrial ablation (TBA), microwave endometrial ablation (MEA), hydrothermablation (HTA), bipolar radiofrequency endometrial ablation (RFA) and endometrial cryotherapy achieve deep endometrial destruction without the need for hysteroscopic surgical skills, so that visualization is no longer a prerequisite for endometrial ablation. The second-generation ablation devices are much easier to learn and perform than first-generation devices.

They can be performed in the outpatient setting under local anesthetic, thus expanding patient choice and potentially increasing cost-effectiveness of treatment. Non-resectoscopic techniques are technically easier to perform than resectoscopic techniques, have shorter operative times, and allow the use of local rather than general anaesthesia. However, both techniques have comparable patient satisfaction and reduction of heavy menstrual bleeding (*Laberge et al., 2015*).

Regarding the cost-effectiveness of different treatment for HMB, Spencer et al performed a study, evaluating 4 treatment options: hysterectomy, resectoscopic endometrial ablation, nonresectoscopic endometrial ablation, and the levonorgestrel-releasing intrauterine system. The levonorgestrel-releasing intrauterine system was superior to both hysterectomy and endometrial ablation in terms of cost and quality of life. For women who are not good candidates for the levonorgestrel-releasing intrauterine system as a first-course treatment for heavy menstrual bleeding, consideration of cost, procedure-specific complications, and patient preferences can guide the decision between hysterectomy and ablation (*Spencer et al., 2017*).

Published papers:

Bofill Rodriguez M, Lethaby A, **Grigore M**, Brown J, Hickey M, Farquhar C. Endometrial resection and ablation techniques for heavy menstrual bleeding. *Cochrane Database Syst Rev* 2019; 22;1: CD001501. **IF- 7,66**

I.3.2.2 Material and methods

We included all randomized controlled trials (RCTs) comparing techniques for ablation or resection of the endometrium for treatment of HMB.

Inclusion criteria

- Women of reproductive years with regular heavy periods measured objectively or subjectively

Exclusion criteria

- Postmenopausal bleeding (longer than 1 year from the last period)
- Irregular menstruation and inter-menstrual bleeding
- Pathological causes of HMB (e.g. uterine cancer)
- Iatrogenic causes of HMB (e.g. intrauterine coil devices)

We included studies that compared endometrial resection and ablation techniques (transcervical resection of the endometrium, laser ablation, rollerball ablation, saline irrigation, microwave ablation, radiofrequency ablation, heated balloon, photodynamic therapy, cryoablation, and any other endometrial destruction techniques) against each other or grouped in the broad categories of first- or second-generation techniques performed to reduce HMB.

We established for this study two types of outcomes: primary and secondary.

Primary outcomes were:

- a. Menstrual bleeding after the procedure
- b. Rate of satisfaction

Secondary outcomes were:

- a. Operative outcomes (duration of surgery, operative difficulties, proportion given local rather than general anesthesia)
- a. Recovery, time or ability to return to normal activities or work
- b. Quality of life
- c. Adverse effects.

We performed a systematic review of the literature and a meta-analysis of the randomized control trials included in the study.

Several database were studied: Cochrane Gynaecology and Fertility (CGFG) Specialised Register (PROCITE platform); Cochrane Central Register of Controlled Trials (CENTRAL), Cochrane Register of Studies Online (CRSO), MEDLINE (OVID platform), Embase (OVID platform), PsycINFO (OVID platform); Cumulative Index to Nursing and Allied Health Literature(CINAHL) (EBSCO platform). Also trial registries for ongoing and registered trials (ClinicalTrials.gov), The Cochrane Library and grey literature were studied.

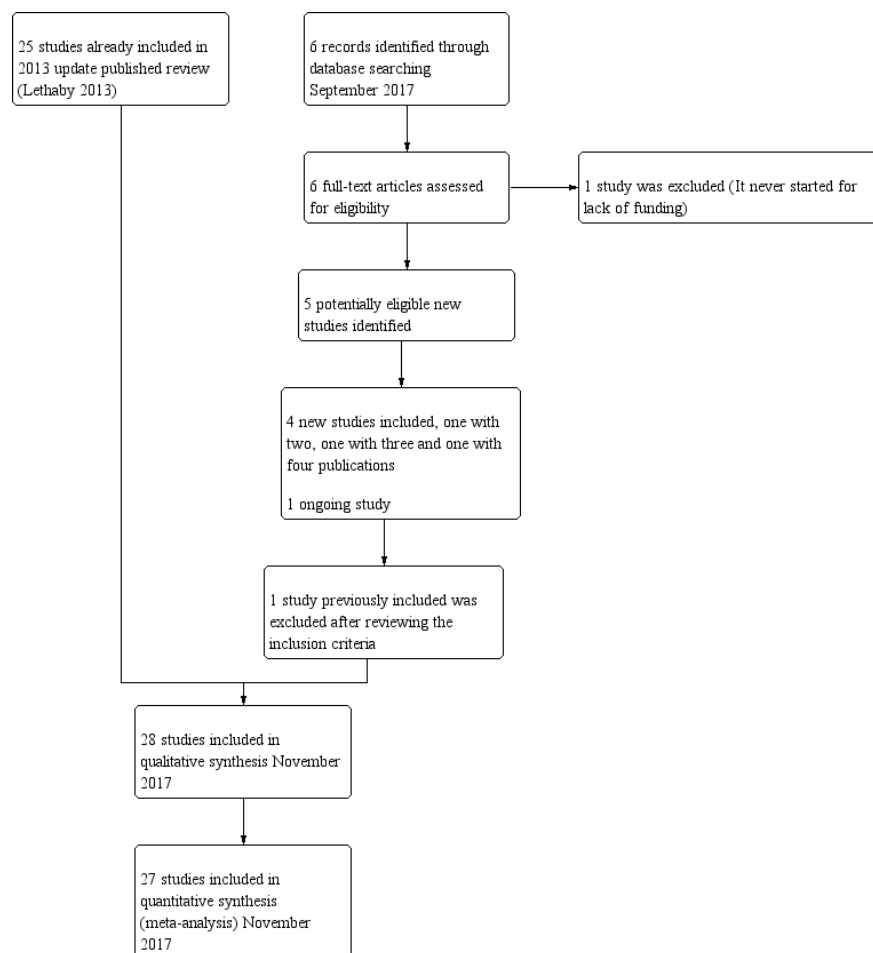


Fig. 16 Study flow diagram

The 28 included studies included 4287 premenopausal participants, most within the age range 30 to 50 years. All of these studies recruited women from secondary or tertiary referral centers or clinics who described HMB. Most studies had low risk of bias for randomisation, attrition, and selective reporting. Less than half of these studies had adequate allocation concealment, and most were unblinded. Using GRADE, we determined that the quality of evidence ranged from moderate to very low. We downgraded evidence for risk of bias, imprecision, and inconsistency. Study flow diagram is presented in Fig.16.

I.3.2.3.Results

Laser ablation versus transcervical resection of the endometrium (TCRE)

Two studies with a total of 176 women reported laser versus transcervical resection of the endometrium and no clear evidence showed any differences between laser ablation and TCRE groups in the rate of amenorrhoea at 6 months. One trial provided no clear evidence of a difference between laser ablation and TCRE groups in the rate of satisfaction at 12 months. Duration of laser ablation surgery was on average 9 minutes longer than for TCRE. Risks of equipment failure were greater among women who had laser ablation than among those with TCRE. Researchers found no clear evidence of a difference between laser ablation and TRCE at 12 months for the proportion of women reporting good general health. No clear evidence showed a

difference between laser ablation and TRCE in major complication rates (Fig. 17)

Laser ablation (first generation) versus transcervical resection of the endometrium (TCRE) (first generation)

Outcome or subgroup title	No. of studies	No. of participants	Statistical method	Effect size
• Bleeding - blood loss (mL) at 6 months	1	22	Mean Difference (IV, Fixed, 95% CI)	23.6 [-8.32, 55.52]
	2		Risk Ratio (M-H, Fixed, 95% CI)	Subtotals only
• Bleeding				
2.1 Amenorrhoea rate at 6 months	2	348	Risk Ratio (M-H, Fixed, 95% CI)	0.97 [0.66, 1.45]
2.2 Amenorrhoea/hypomenorrhoea rate at 6 months	1	326	Risk Ratio (M-H, Fixed, 95% CI)	0.97 [0.89, 1.05]
2.3 Amenorrhoea/hypomenorrhoea rate at 12 months	1	306	Risk Ratio (M-H, Fixed, 95% CI)	1.06 [0.92, 1.22]
3 Rate of satisfaction at 12 months (very/moderately)	1	321	Risk Ratio (M-H, Fixed, 95% CI)	0.99 [0.92, 1.06]
4 Duration of operation (minutes)	2	386	Mean Difference (IV, Fixed, 95% CI)	9.15 [7.21, 11.09]
5 Operative difficulties	1		Risk Ratio (M-H, Fixed, 95% CI)	Subtotals only
5.1 Procedure abandoned	1	366	Risk Ratio (M-H, Fixed, 95% CI)	1.47 [0.61, 3.51]
5.2 Failed instrumentation	1	366	Risk Ratio (M-H, Fixed, 95% CI)	0.20 [0.01, 4.05]
5.3 Equipment failure	1	366	Risk Ratio (M-H, Fixed, 95% CI)	5.54 [1.65, 18.60]
5.4 Immediate hysterectomy	1	366	Risk Ratio (M-H, Fixed, 95% CI)	0.33 [0.01, 7.95]
6 Good general health	1	321	Risk Ratio (M-H, Fixed, 95% CI)	1.03 [0.95, 1.12]
7 Improvement in menstrual symptoms	1		Risk Ratio (M-H, Fixed, 95% CI)	Subtotals only
7.1 Improvement in symptoms (general)	1	321	Risk Ratio (M-H, Fixed, 95% CI)	1.03 [0.87, 1.21]
7.2 Improvement in dysmenorrhoea at 6 months	1	253	Risk Ratio (M-H, Fixed, 95% CI)	1.17 [1.00, 1.38]
7.3 Improvement in dysmenorrhoea at 12 months	1	218	Risk Ratio (M-H, Fixed, 95% CI)	1.00 [0.87, 1.15]
8 Complication rate: major complications	2	2218	Risk Ratio (M-H, Fixed, 95% CI)	1.41 [0.83, 2.41]
8.1 Perforation	1	366	Risk Ratio (M-H, Fixed, 95% CI)	0.14 [0.01, 2.69]
8.2 Bowel obstruction	1	366	Risk Ratio (M-H, Fixed, 95% CI)	2.94 [0.12, 71.59]

8.3 Pelvic sepsis	1	366	Risk Ratio (M-H, Fixed, 95% CI)	0.82 [0.25, 2.62]
8.4 Haematometra	1	366	Risk Ratio (M-H, Fixed, 95% CI)	0.20 [0.01, 4.05]
8.5 Glycine toxicity	1	22	Risk Ratio (M-H, Fixed, 95% CI)	4.23 [0.23, 79.10]
8.6 Fluid overload (> 1.5 L)	1	366	Risk Ratio (M-H, Fixed, 95% CI)	4.89 [1.44, 16.61]
8.7 Uterine tamponade	1	366	Risk Ratio (M-H, Fixed, 95% CI)	1.14 [0.39, 3.33]
9 Complication rate: minor complications	1		Risk Ratio (M-H, Fixed, 95% CI)	Subtotals only
9.1 Burns	1	366	Risk Ratio (M-H, Fixed, 95% CI)	4.89 [0.24, 101.21]
9.2 Urinary tract infection	1	366	Risk Ratio (M-H, Fixed, 95% CI)	1.96 [0.36, 10.55]

Fig.17. Laser ablation (first generation) versus transcervical resection of the endometrium (TCRE)(first generation).

Thermal laser (second generation) versus TCRE (first generation).

One study with 111 women reported on thermal laser versus TCRE. Rates of amenorrhoea at 1 and 3 years after surgery were greater for women in the thermal laser group than in the TCRE group. Trials showed no clear evidence of a difference in satisfaction rates between thermal laser and TCRE at 1 year. Mean length of surgery was shorter for women in the thermal laser group than in the TCRE group. Researchers have provided no evidence of differences in the major complication rate between thermal laser and TCRE such as perforation (no events in either group). (Fig. 18).

Thermal laser (second generation) versus TCRE (first generation)

Outcome or subgroup title	No. of studies	No. of participants	Statistical method	Effect size
1 Bleeding - amenorrhoea rate	1		Risk Ratio (M-H, Fixed, 95% CI)	Subtotals only
1.1 At 1 year follow-up	1	111	Risk Ratio (M-H, Fixed, 95% CI)	2.46 [1.50, 4.03]
1.2 At 2 to 5 years' follow-up	1	111	Risk Ratio (M-H, Fixed, 95% CI)	2.49 [1.48, 4.21]
2 Rate of satisfaction	1		Risk Ratio (M-H, Fixed, 95% CI)	Subtotals only
2.1 At 1 year follow-up	1	111	Risk Ratio (M-H, Fixed, 95% CI)	1.04 [0.94, 1.16]
2.2 At 2 to 5 years' follow-up	1	111	Risk Ratio (M-H, Fixed, 95% CI)	1.02 [0.91, 1.14]
3 Duration of operation	1	111	Mean Difference (IV, Fixed, 95% CI)	-9.30 [-11.36, -7.24]
4 Complication rate: major complications	1		Risk Ratio (M-H, Fixed, 95% CI)	Subtotals only
4.1 Perforation	1	111	Risk Ratio (M-H, Fixed, 95% CI)	0.0 [0.0, 0.0]
5 Complication rate: minor complications	1	111	Odds Ratio (M-H, Fixed, 95% CI)	0.48 [0.04, 5.47]
5.1 UTI	1	111	Odds Ratio (M-H, Fixed, 95% CI)	0.48 [0.04, 5.47]
6 Requirement for further surgery	1	111	Risk Ratio (M-H, Fixed, 95% CI)	0.59 [0.15, 2.35]
6.1 At 2 to 5 years' rate (hysterectomy only)	1	111	Risk Ratio (M-H, Fixed, 95% CI)	0.59 [0.15, 2.35]

follow-up

Fig 18. Thermal laser (second generation) versus TCRE (first generation).

Cryoablation (second generation) versus rollerball (first generation)

Women undergoing cryoablation were less likely to have amenorrhoea 1 year after surgery than women receiving rollerball treatment. We found no evidence of clear differences between groups for satisfaction with treatment at 1 year. Women undergoing cryoablation were more likely to receive local rather than general anaesthesia than women undergoing rollerball ablation. No evidence showed clear differences between groups for major complications (Fig.19)

Cryoablation (second generation) versus rollerball (first generation)

Outcome or subgroup title	No. of studies	No. of participants	Statistical method	Effect size
1 Bleeding	1	228	Risk Ratio (M-H, Fixed, 95% CI)	0.50 [0.36, 0.69]
1.1 Amenorrhoea at 1 year follow-up	1	228	Risk Ratio (M-H, Fixed, 95% CI)	0.50 [0.36, 0.69]
2 Rate of satisfaction	1		Risk Ratio (M-H, Fixed, 95% CI)	Subtotals only
2.1 At 1 year follow-up	1	279	Risk Ratio (M-H, Fixed, 95% CI)	1.06 [0.96, 1.17]
2.2 At 2 years' follow-up	1	137	Risk Ratio (M-H, Fixed, 95% CI)	1.04 [0.91, 1.17]
3 Proportion given local anaesthesia (%)	1	279	Risk Ratio (M-H, Fixed, 95% CI)	6.62 [3.22, 13.63]
4 Complication rate: major complications	1		Risk Ratio (M-H, Fixed, 95% CI)	Subtotals only
4.1 Perforation	1	279	Risk Ratio (M-H, Fixed, 95% CI)	0.15 [0.01, 3.63]
5 Complication rate: minor complications	1	1116	Odds Ratio (M-H, Fixed, 95% CI)	0.56 [0.15, 2.09]
5.1 Vaginal bleeding	1	279	Odds Ratio (M-H, Fixed, 95% CI)	1.35 [0.05, 33.43]
5.2 Abdominal cramping	1	279	Odds Ratio (M-H, Fixed, 95% CI)	2.26 [0.11, 47.54]
5.3 UTI	1	279	Odds Ratio (M-H, Fixed, 95% CI)	0.15 [0.01, 3.65]
5.4 Severe pelvic pain	1	279	Odds Ratio (M-H, Fixed, 95% CI)	0.15 [0.01, 3.65]
6 Requirement for further surgery	1		Risk Ratio (M-H, Fixed, 95% CI)	Subtotals only
6.1 At 2 years' follow-up (any surgery)	1	279	Risk Ratio (M-H, Fixed, 95% CI)	1.00 [0.45, 2.22]
6.2 At 2 years' follow-up (hysterectomy)	1	279	Risk Ratio (M-H, Fixed, 95% CI)	0.83 [0.34, 2.00]

Fig. 19. Cryoablation (second generation) versus rollerball (first generation).

Electrode ablation (second generation) versus TCRE + rollerball (first generation)

Two studies with a total of 541 women compared electrode ablation (balloon or mesh) versus TCRE. Trial results showed no clear evidence of differences between groups for bleeding. Upon assessing rate of satisfaction with treatment after 1 year, study authors did not report clear differences between groups comparing the mesh

system to TCRE. The duration of the procedure was significantly longer for women

undergoing TCRE compared with ablation. Clear evidence showed differences in major complications such as perforation and cervical tears or lacerations between groups. Perforation (RR 0.13, 95% CI 0.02 to 1.01; 532 women; 2 studies; $I^2 = 0\%$) and cervical tears or lacerations (RR 0.11, 95% CI 0.01 to 0.87; 532 women; 2 studies; $I^2 = 0\%$) were less likely with electrode ablation than with TCRE (Fig. 20).

Electrode ablation (second generation) versus TCRE + rollerball (first generation)

Outcome or subgroup title	No. of studies	No. of participants	Statistical method	Effect size
1 Bleeding - amenorrhoea rate at 1 year follow-up	2	470	Risk Ratio (M-H, Fixed, 95% CI)	1.02 [0.79, 1.31]
1.1 Balloon system	1	234	Risk Ratio (M-H, Fixed, 95% CI)	0.89 [0.62, 1.29]
1.2 Mesh system	1	236	Risk Ratio (M-H, Fixed, 95% CI)	1.16 [0.82, 1.64]
2 Proportion with successful Rx (PBAC < 75)	2	470	Risk Ratio (M-H, Fixed, 95% CI)	1.06 [0.98, 1.15]
2.1 Balloon system	1	234	Risk Ratio (M-H, Fixed, 95% CI)	1.05 [0.94, 1.17]
2.2 Mesh system	1	236	Risk Ratio (M-H, Fixed, 95% CI)	1.08 [0.96, 1.22]
3 PBAC score 12 months after treatment			Other data	No numeric data
3.1 Balloon system			Other data	No numeric data
3.2 Mesh system			Other data	No numeric data
4 Rate of satisfaction with treatment at 1 year	1	236	Risk Ratio (M-H, Fixed, 95% CI)	0.99 [0.92, 1.06]
4.1 Mesh system	1	236	Risk Ratio (M-H, Fixed, 95% CI)	0.99 [0.92, 1.06]
5 Duration of operation (minutes)	2	520	Mean Difference (IV, Fixed, 95% CI)	-18.70 [-20.66, -16.75]
5.1 Balloon system	1	255	Mean Difference (IV, Fixed, 95% CI)	-16.20 [-19.55, -12.85]
5.2 Mesh system	1	265	Mean Difference (IV, Fixed, 95% CI)	-20.0 [-22.41, -17.59]
6 Procedure abandon	1	267	Odds Ratio (M-H, Fixed, 95% CI)	2.58 [0.10, 63.95]
7 Proportion given local anesthesia (%)	2	520	Risk Ratio (M-H, Fixed, 95% CI)	3.85 [2.94, 5.04]
7.1 Balloon system	1	255	Risk Ratio (M-H, Fixed, 95% CI)	3.66 [2.65, 5.07]
7.2 Mesh system	1	265	Risk Ratio (M-H, Fixed, 95% CI)	4.11 [2.61, 6.47]
8 Complication rate: major complications	2		Risk Ratio (M-H, Fixed, 95% CI)	Subtotals only
8.1 Cervical tear/stenosis	2	532	Risk Ratio (M-H, Fixed, 95% CI)	0.11 [0.01, 0.87]
8.2 Perforation	2	532	Risk Ratio (M-H, Fixed, 95% CI)	0.13 [0.02, 1.01]
8.3 Pelvic abscess	1	265	Risk Ratio (M-H, Fixed, 95% CI)	0.17 [0.01, 4.19]
8.4 Haematometra	2	532	Risk Ratio (M-H, Fixed, 95% CI)	0.43 [0.08, 2.23]
8.5 Fluid overload	1	267	Risk Ratio (M-H, Fixed, 95% CI)	0.29 [0.01, 6.93]

8.6 Myometritis	1	267	Risk Ratio (M-H, Fixed, 95% CI)	0.29 [0.01, 6.93]
8.7 Urinary incontinence	1	267	Risk Ratio (M-H, Fixed, 95% CI)	0.29 [0.01, 6.93]
8.8 PID	1	265	Risk Ratio (M-H, Fixed, 95% CI)	1.03 [0.09, 11.19]
8.9 Endometritis	1	265	Risk Ratio (M-H, Fixed, 95% CI)	0.34 [0.06, 2.01]
9 Complication rate: minor complications	2		Risk Ratio (M-H, Fixed, 95% CI)	Subtotals only
9.1 Nausea/vomiting or severe pelvic pain	2	532	Risk Ratio (M-H, Fixed, 95% CI)	1.10 [0.37, 3.27]
9.2 UTI	2	532	Risk Ratio (M-H, Fixed, 95% CI)	1.05 [0.39, 2.84]
9.3 Fever	1	267	Risk Ratio (M-H, Fixed, 95% CI)	0.85 [0.05, 13.51]
9.4 Haemorrhage	1	265	Risk Ratio (M-H, Fixed, 95% CI)	0.51 [0.03, 8.13]
9.5 Bradycardia	1	265	Risk Ratio (M-H, Fixed, 95% CI)	1.55 [0.06, 37.70]
10 Requirement for further surgery at 2 years (hysterectomy)	1	255	Risk Ratio (M-H, Fixed, 95% CI)	0.52 [0.18, 1.50]
10.1 Balloon system	1	255	Risk Ratio (M-H, Fixed, 95% CI)	0.52 [0.18, 1.50]

Fig. 20 Electrode ablation (second generation) versus TCRE + rollerball (first generation).

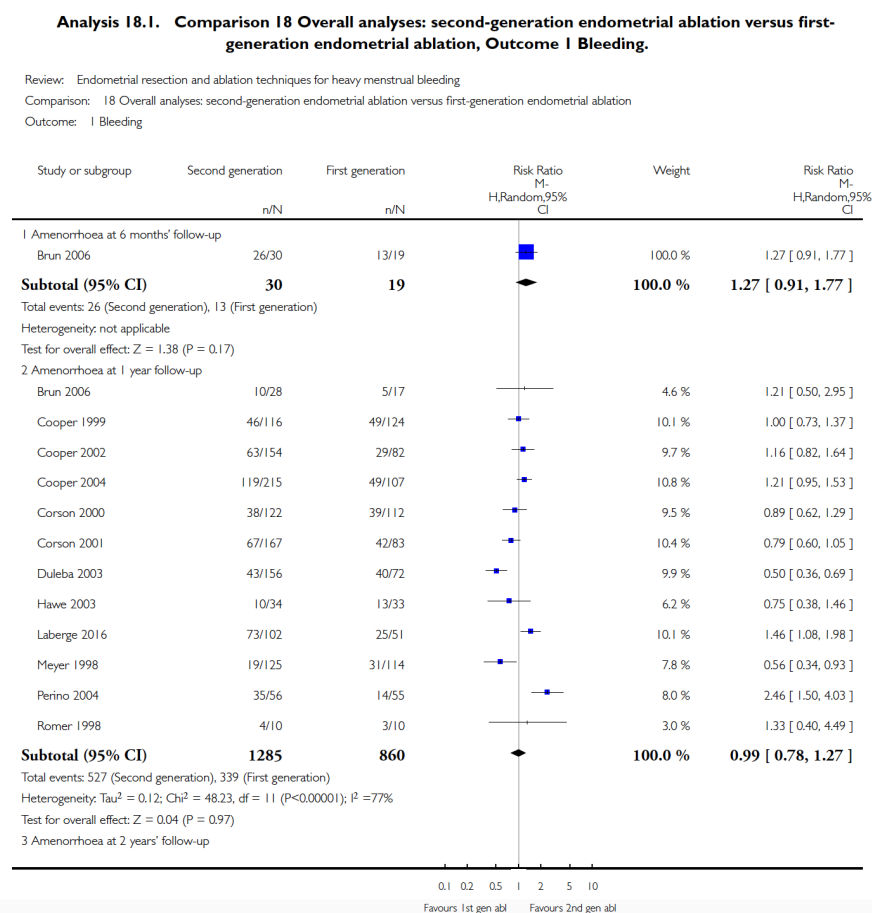


Fig. 21. Second-generation ablative techniques versus first generation ablation techniques- Bleeding (overall).

Second-generation ablative techniques versus first generation ablation techniques (overall)

When compare all methods of second-generation ablative techniques versus first generation ablation techniques (overall) the results for the main and secondary outcomes were as follow:

1. **Bleeding.** We found no evidence of clear differences in bleeding parameters such as the following (Analysis 18.1) (Fig.21).
 - a. Amenorrhoea at 6 months' follow-up (RR 1.27, 95% CI 0.91 to 1.77; 49 women; 1 study).
 - b. Amenorrhoea at 2 years' follow-up (RR 0.97, 95% CI 0.72 to 1.30; 70 women; 3 studies; $I^2 = 51\%$).
 - c. Amenorrhoea at 2 to 5 years' follow-up (RR 1.16, 95% CI 0.78 to 1.72; 672 women; 4 studies; $I^2 = 80\%$).
 - d. Amenorrhoea at up to 10 years' follow-up (RR 0.94, 95% CI 0.83 to 1.05; 189 women; 1 study).

2. Amenorrhoea at 1 year follow-up

Trials provided no evidence of clear differences in the rate of amenorrhoea between groups at 12 months' follow-up (RR 0.99, 95% CI 0.78 to 1.27; 2145 women; 12 studies; $I^2 = 77\%$). (Fig.22 and the funnel plot for this comparison in Fig. 23).

Amenorrhoea at 1 year follow-up

Analysis 18.2. Comparison 18 Overall analyses: second-generation endometrial ablation versus first-generation endometrial ablation, Outcome 2 Bleeding - amenorrhoea at 12 months' follow-up (final plot).

Review: Endometrial resection and ablation techniques for heavy menstrual bleeding

Comparison: 18 Overall analyses: second-generation endometrial ablation versus first-generation endometrial ablation

Outcome: 2 Bleeding - amenorrhoea at 12 months' follow-up (final plot)

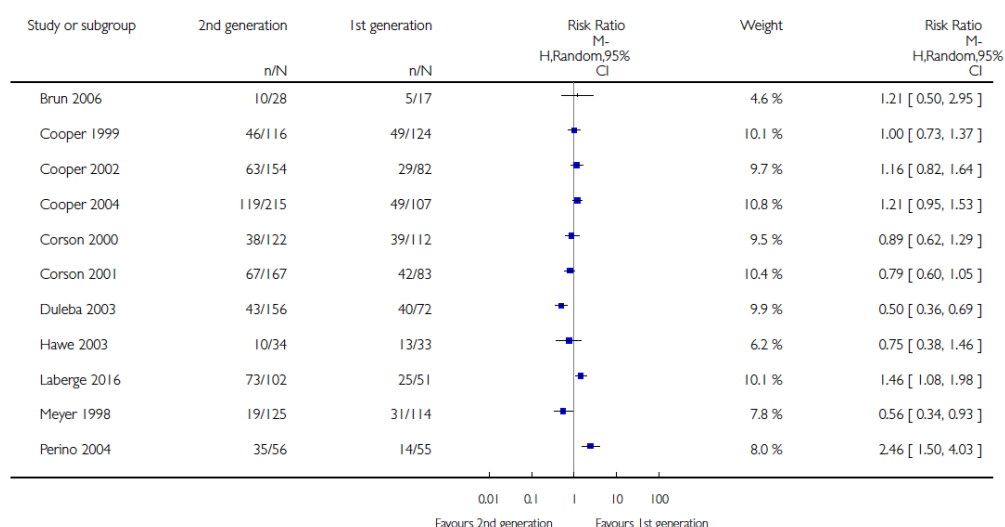


Fig. 22 Amenorrhoea at 1 year follow-up.

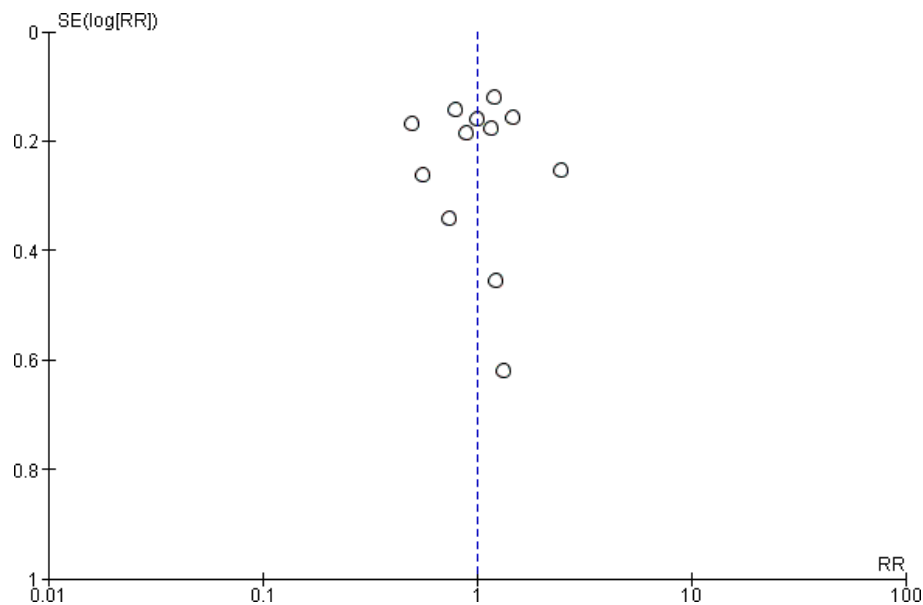


Fig. 23. Amenorrhoea at 1 year follow-up.

3. Rate of satisfaction

We found no evidence of clear differences in satisfaction rates up to 10 years' follow-up, including the following (Analysis 18.3).

- i. Satisfaction rate at 6 months' follow-up (RR 1.06, 95% CI 0.93 to 1.20; 50 women; 1 study).
- ii. Satisfaction rate at 2 years' follow-up (RR 1.09, 95% CI 0.99 to 1.21; 802 women; 5 studies; $I^2 = 52\%$).
- iii. Satisfaction rate at 2 to 5 years' follow-up (RR 1.02, 95% CI 0.93 to 1.13; 672 women; 4 studies; $I^2 = 81\%$) (Fig. 24)

Analysis 18.3. Comparison 18 Overall analyses: second-generation endometrial ablation versus first-generation endometrial ablation, Outcome 3 Satisfaction rate.

Review: Endometrial resection and ablation techniques for heavy menstrual bleeding

Comparison: 18 Overall analyses: second-generation endometrial ablation versus first-generation endometrial ablation

Outcome: 3 Satisfaction rate

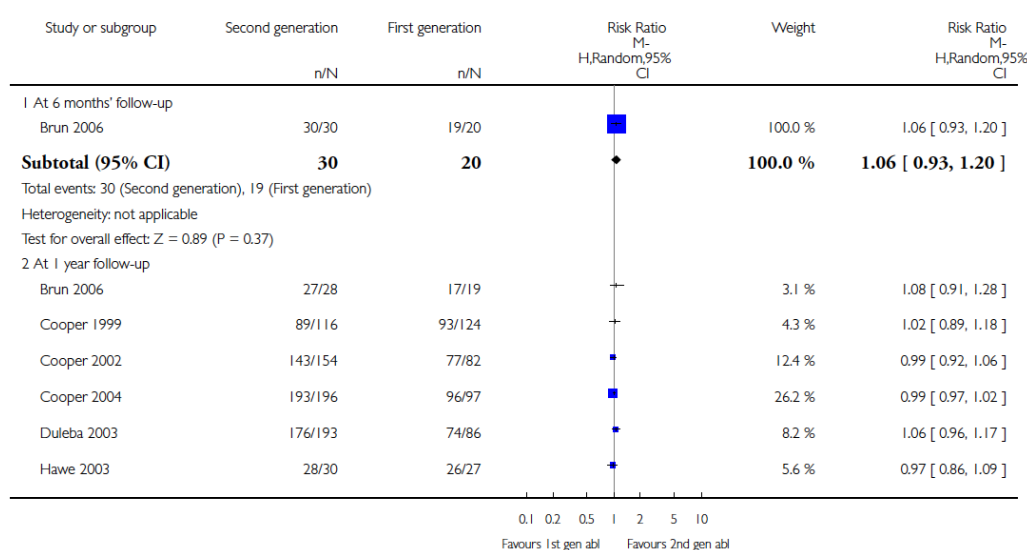


Fig. 24. Overall analysis: rate of satisfaction.

Satisfaction rate at 12 months’ follow-up

Study results showed no evidence of clear differences in rates of amenorrhoea between groups at 12 months’ follow-up (RR 1.01, 95% CI 0.98 to 1.04; 1750 women; 11 studies; $I^2 = 36\%$). (Fig.25 and the funnel plot for this comparison in Figure 26).

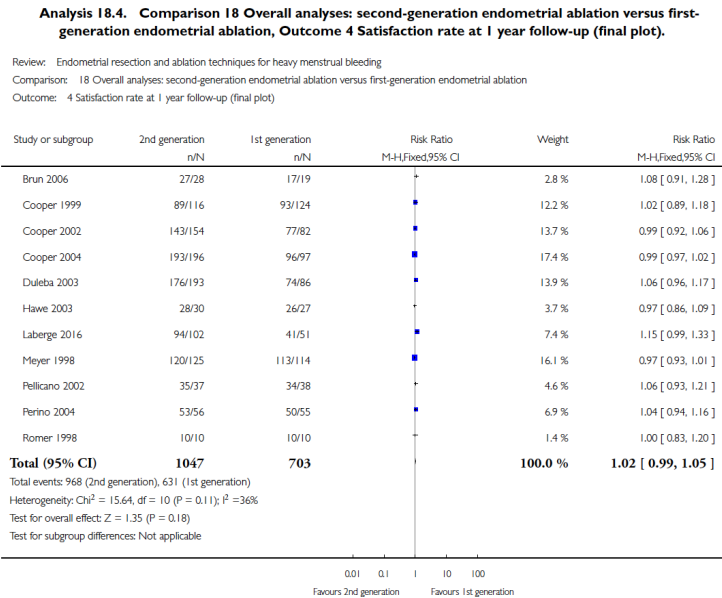


Fig. 25 Satisfaction rate at 12 months’ follow-up.

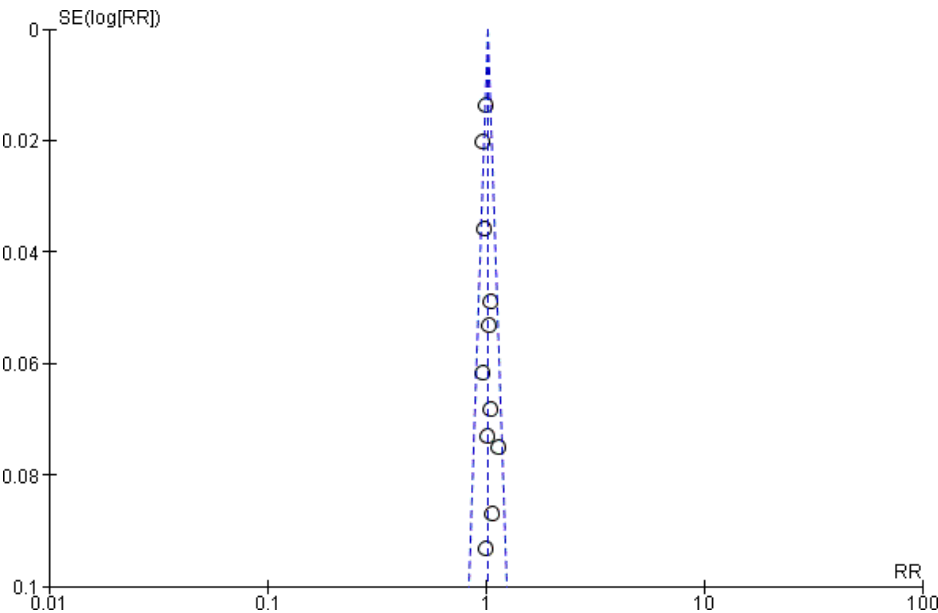


Fig. 26. Satisfaction rate at 12 months’ follow-up.

• Secondary outcomes -Duration of surgery

The mean difference in average surgical time between first- and second-generation techniques was 13 minutes, ranging between 17 and 10 minutes. Heterogeneity was very high (94%), so we could not pool the analysis; we found that removing studies with high risk of allocation bias did not make any difference (Fig. 27).

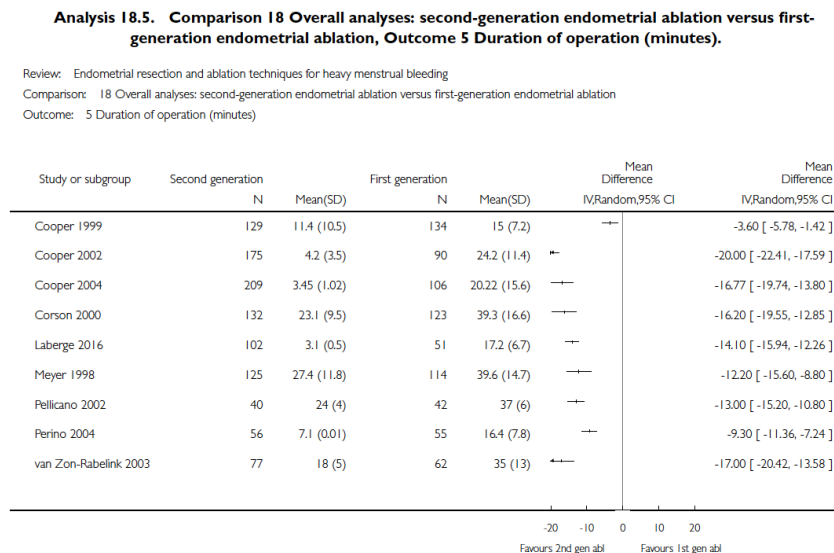


Fig. 27. Duration of surgery.

• Operative difficulties

Risk of equipment failure was greater with second-generation devices (RR 4.26, 95% CI 1.46 to 12.43; 384 women; 3 studies; $I^2 = 0\%$) (Fig. 28). It is important to mention here that only 3 of 10 studies comparing first- versus second-generation ablation techniques reported equipment failure. Lack of reporting of treatment failure does not necessarily mean that it did not happen. The theory that treatment failure could be associated with the beginning of the technique does not explain it; only one of the remaining seven studies is newer than the ones reporting equipment failure. We found no evidence of clear differences between groups in terms of abandoning the procedure (RR 1.18, 95% CI 0.38 to 3.67; 629 women; 3 studies; $I^2 = 0\%$)

• Proportion given local anaesthesia

The chance that local rather than general anaesthesia would be used was greater with second-generation devices (RR 2.78, 95% CI 1.76 to 4.40; $I^2 = 85\%$). This must be carefully interpreted because heterogeneity was high (Fig. 29)

Analysis 18.6. Comparison 18 Overall analyses: second-generation endometrial ablation versus first-generation endometrial ablation, Outcome 6 Operative difficulties.

Review: Endometrial resection and ablation techniques for heavy menstrual bleeding

Comparison: 18 Overall analyses: second-generation endometrial ablation versus first-generation endometrial ablation

Outcome: 6 Operative difficulties

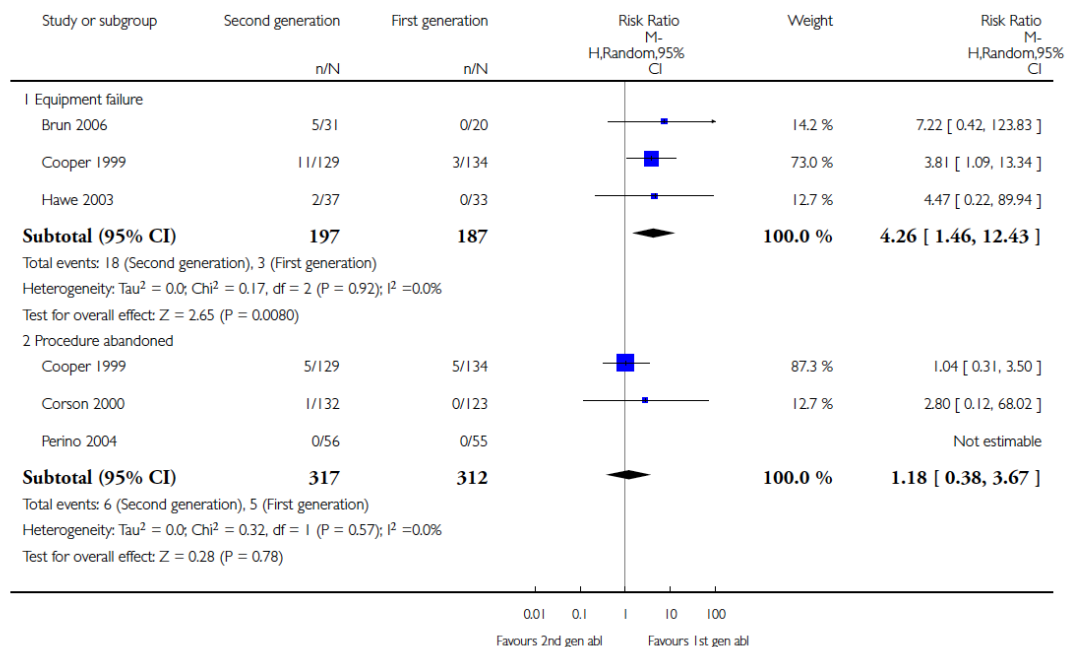


Fig. 28. Operative difficulties.

Analysis 18.7. Comparison 18 Overall analyses: second-generation endometrial ablation versus first-generation endometrial ablation, Outcome 7 Proportion given local anaesthesia (%).

Review: Endometrial resection and ablation techniques for heavy menstrual bleeding

Comparison: 18 Overall analyses: second-generation endometrial ablation versus first-generation endometrial ablation

Outcome: 7 Proportion given local anaesthesia (%)

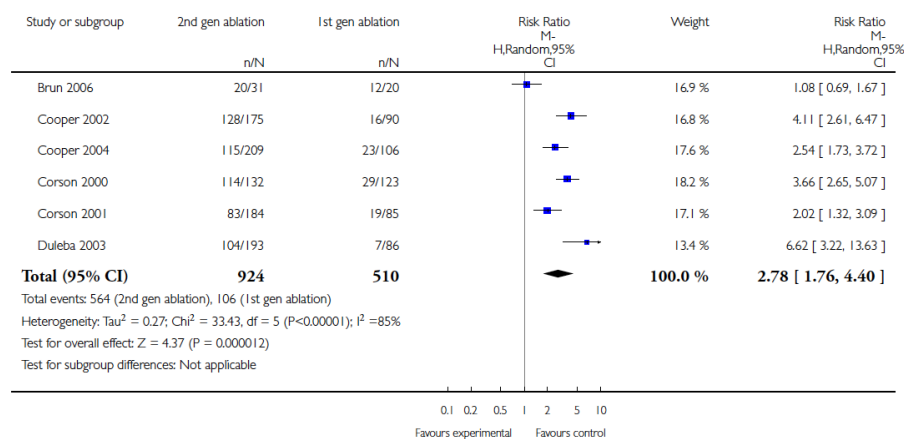


Fig. 29. Proportion given local anaesthesia.

Inability to work

We noted no evidence of a clear difference between groups in inability to work (RR 0.84, 95% CI 0.30 to 2.30; 279 women; 2 studies; $I^2 = 20\%$) (Fig. 30).

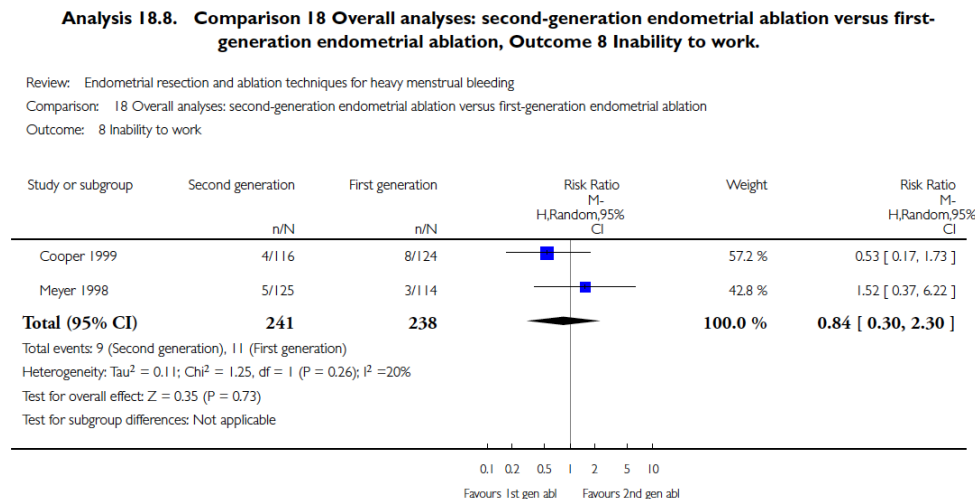


Fig. 30. Inability to work.

• Complication rate: major complications

Regarding major complications, women undergoing second-generation ablation procedures, when compared to the group having first-generation procedures, were less likely to have the following major complications (Fig. 31).

- Cervical lacerations (RR 0.21, 95% CI 0.07 to 0.61; 1583 women; 7 studies; $I^2 = 0\%$).
- Haematometra (RR 0.34, 95% CI 0.12 to 0.95; 1193 women; 5 studies;
- Fluid overload (RR 0.16, 95% CI 0.03 to 0.94; 588 women; 3 studies; $I^2 = 0\%$).

We found no clear evidence of differences between groups in other major complications such as the following (Analysis 18.9).

- Perforation (RR 0.32, 95% CI 0.10 to 1.01; 1885 women; 8 studies; $I^2 = 0\%$).
- Endometritis (RR 1.19, 95% CI 0.33 to 4.37; 1095 women; 4 studies; $I^2 = 25\%$).
- Myometritis (RR 0.29, 95% CI 0.01 to 6.93; 267 women; 1 study)
- Cervical stenosis (RR 1.50, 95% CI 0.06 to 36.52; 322 women; 1 study)
- Pelvic abscess (RR 0.17, 95% CI 0.01 to 4.19; 265 women; 1 study).
- Pelvic inflammatory disease (RR 1.18, 95% CI 0.18 to 7.98; 418 women; 2 studies; $I^2 = 0\%$).
- Blood transfusion (RR 5.24, 95% CI 0.26 to 105.97; 82 women; 1 study).

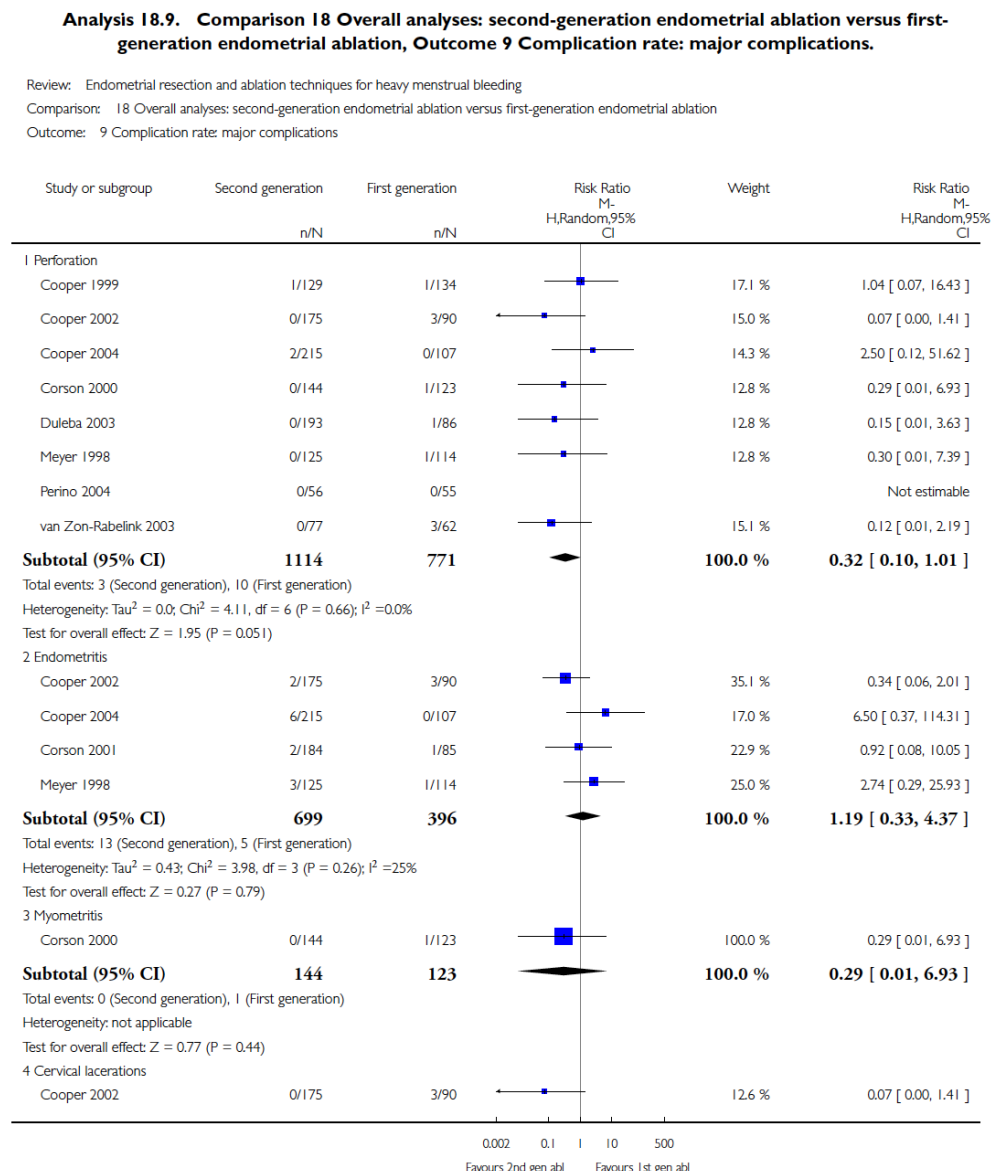


Fig. 31. Complication rate: major complications.

• Complication rate: minor complications

Regarding minor complications, women undergoing first-generation ablation procedures, when compared to those having second-generation procedures, were less likely to have the following minor complications (Fig. 32).

- Nausea and vomiting (RR 2.01, 95% CI 1.40 to 2.88; 997 women; 4 studies; $I^2 = 0\%$).
- Uterine cramping (RR 1.21, 95% CI 1.02 to 1.45; 601 women; 2 studies; $I^2 = 0\%$).

Trial results provided no clear evidence of differences between groups for other minor complications such as the following (Analysis 18.10).

- Urinary tract infection (RR 0.88, 95% CI 0.45 to 1.73; 1834 women; 4 studies; $I^2 = 0\%$).
- Fever (RR 0.98, 95% CI 0.22 to 4.26; 671 women; 3 studies; $I^2 = 0\%$).
- Haemorrhage (RR 0.64, 95% CI 0.26 to 1.58; 889 women; 4 studies; $I^2 = 4\%$).
- Muscle fasciculation (RR 2.57, 95% CI 0.11 to 62.41; 267 women; 1 study).

- External burns (first degree) (RR 2.32, 95% CI 0.11 to 47.89; 269 women; 1 study).
- Hydrosalpinx (RR 0.30, 95% CI 0.01 to 7.39; 239 women; 1 study).
- Severe pelvic pain (RR 0.95, 95% CI 0.36 to 2.48; OR 0.95, 95% CI 0.35 to 2.60; 683 women; 3 studies; $I^2 = 30\%$).

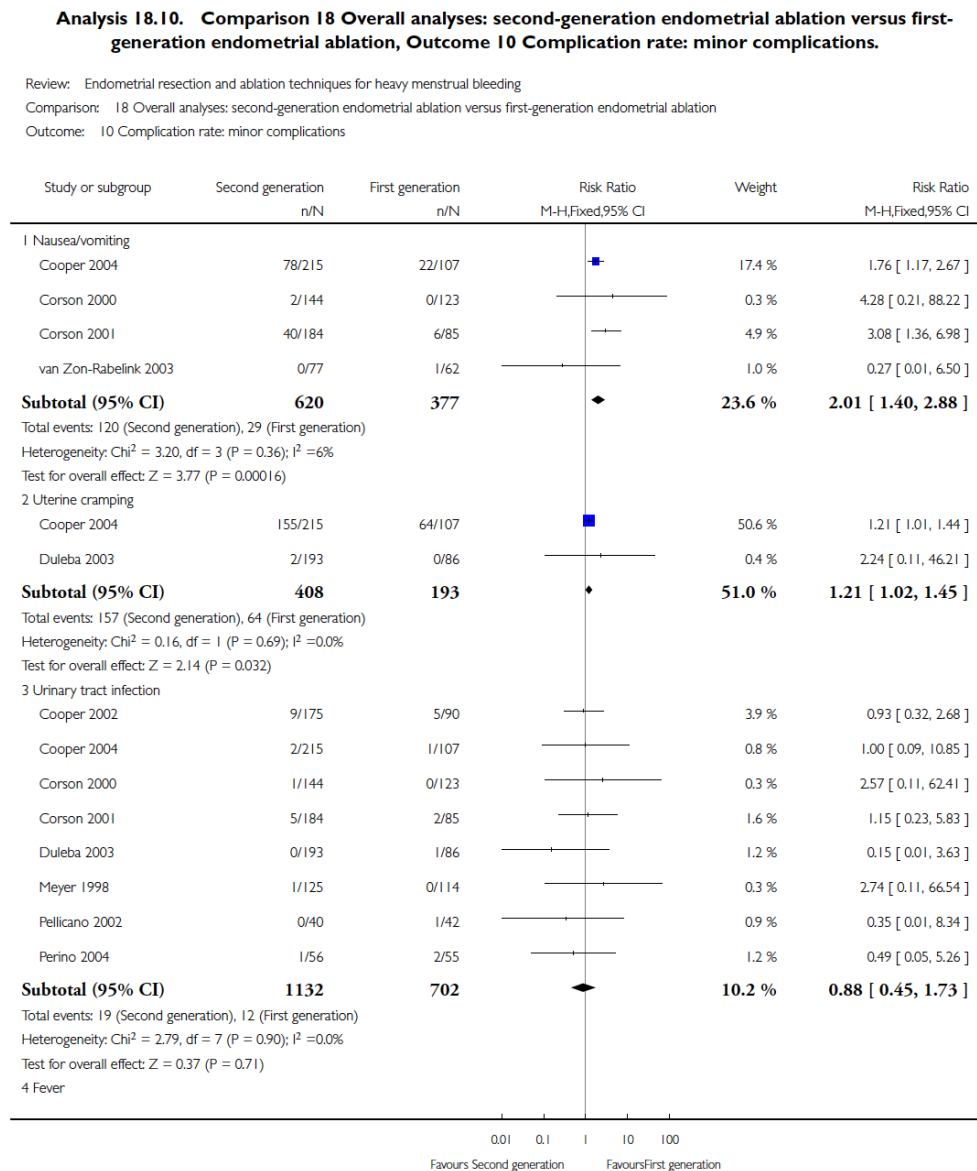


Fig. 32. Complication rate: minor complications.

Requirement for further surgery

We found no evidence of significant differences in the requirement for any additional surgery (hysterectomy or ablation) or hysterectomy in both groups up to 5 years' follow-up, including the following (Fig. 33).

- Requirement for any additional surgery (hysterectomy or ablation) at 1 year

- follow-up (RR 0.72, 95% CI 0.41 to 1.26; 935 women; 6 studies; $I^2 = 0\%$).
- ii. Requirement for any additional surgery (hysterectomy or ablation) at 2 years' follow-up (RR 0.83, 95% CI 0.52 to 1.32; 988 women; 5 studies; $I^2 = 13\%$).
- iii. Requirement for any additional surgery (hysterectomy or ablation) at 2 to 5 years' follow-up (RR 0.95, 95% CI 0.72 to 1.26; 647 women; 3 studies; $I^2 = 0\%$).
- iv. Requirement for hysterectomy at 1 year follow-up (RR 0.66, 95% CI 0.35 to 1.21; (RR 0.66, 95% CI 0.35 to 1.21; 925 women ; 5 studies; $I^2 = 0\%$).
- v. Requirement for hysterectomy at 2 years' follow-up (RR 0.86, 95% CI 0.52 to 1.42; 920 women; 4 studies; $I^2 = 0\%$).
- vi. Requirement for hysterectomy at 2 to 5 years' follow-up (RR 0.85, 95% CI 0.59 to 1.22; 758 women; 4 studies; $I^2 = 14\%$).

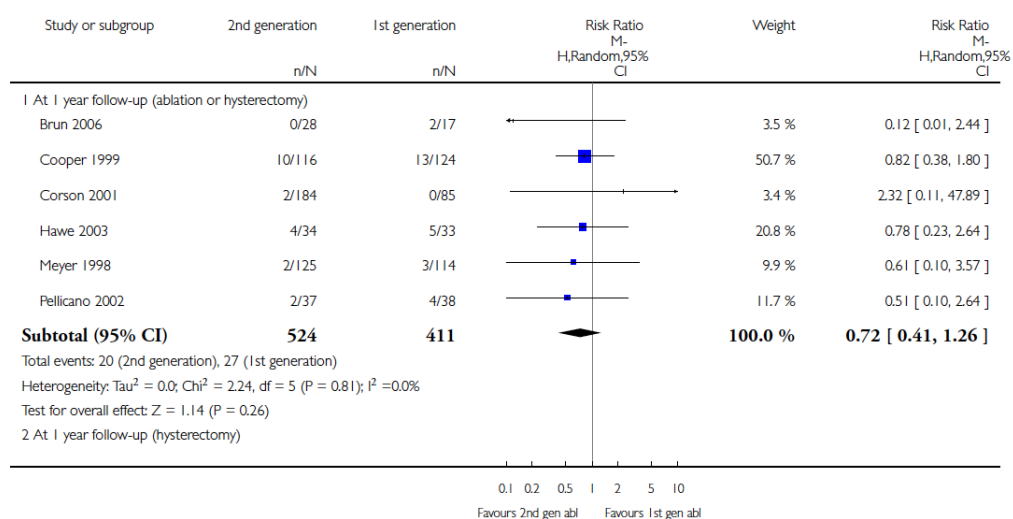
At 10 years' follow-up, women undergoing second-generation techniques have reduced possibilities of undergoing any further surgery (ablation or hysterectomy) (RR 0.57, 95% CI 0.37 to 0.87; 189 women; 1 study) or a subsequent hysterectomy (RR 0.60, 95% CI 0.38 to 0.96; 189 women; 1 study). These results must be interpreted cautiously; they reflect only one trial, in which more than 25% of participants were lost to follow-up. Study authors also reported 9% requiring further hysteroscopies with the second-generation technique but did not provide further details.

Analysis 18.11. Comparison 18 Overall analyses: second-generation endometrial ablation versus first-generation endometrial ablation, Outcome 11 Requirement for additional surgery.

Review: Endometrial resection and ablation techniques for heavy menstrual bleeding

Comparison: 18 Overall analyses: second-generation endometrial ablation versus first-generation endometrial ablation

Outcome: 11 Requirement for additional surgery



(Continued ...)

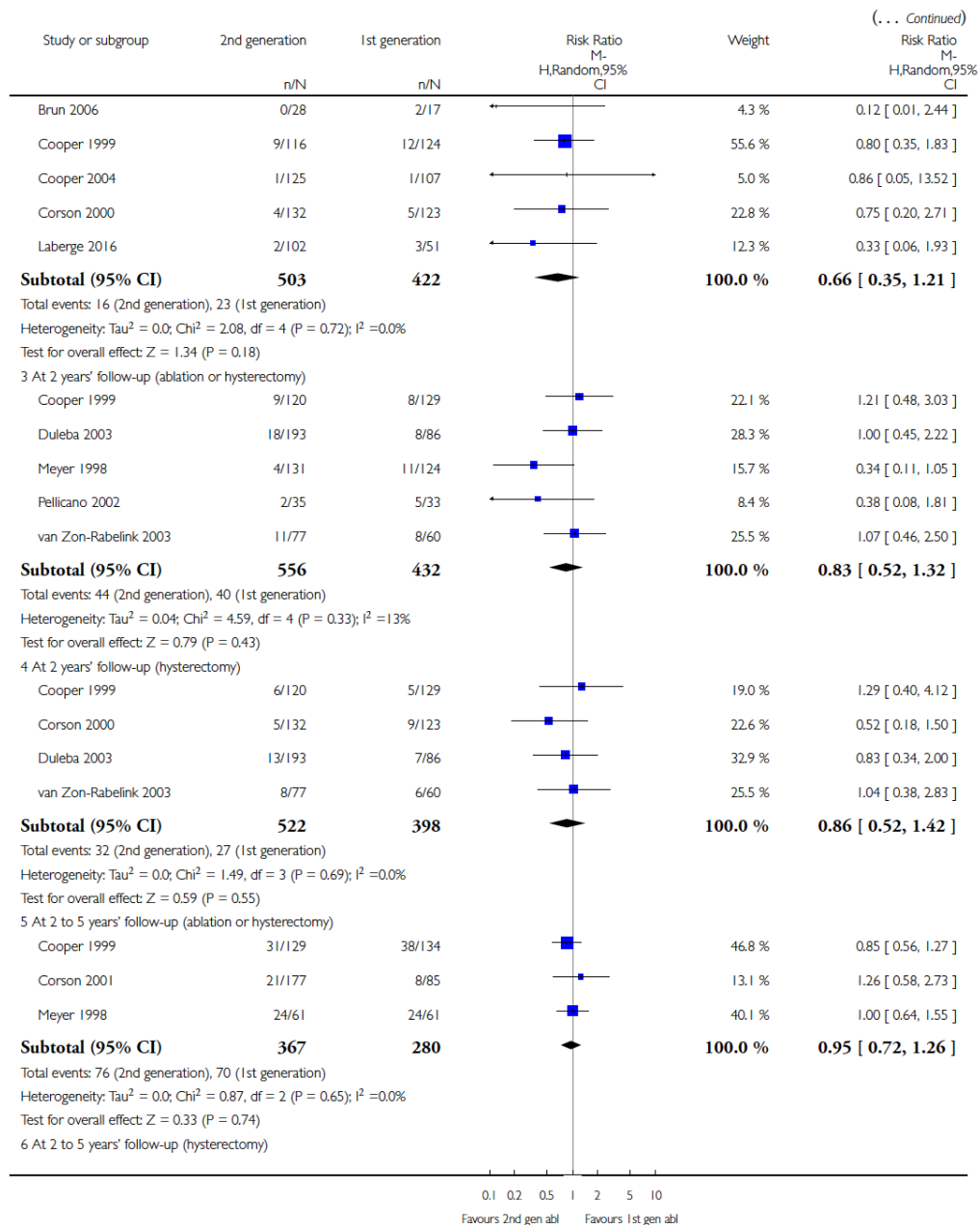


Fig. 33. Requirement for further surgery.

I.3.2.4.Discussion

This review has assessed a wide range of efficacy, satisfaction, and safety outcomes related to different techniques for ablation or resection of the endometrium for women with heavy menstrual bleeding.

Overall comparison of first-generation versus second-generation techniques

Some types of intraoperative and postoperative complications such as fluid overload, cervical lacerations, and haematometra were more common with first-generation ablation; other types of complications, nausea and vomiting, and uterine cramping and pain were more common with second-generation techniques. No clear

evidence shows differences in perforation rates between first- and second-generation techniques. Concerns about these 'blind' methods leading to bowel injuries from undetected uterine perforation did not seem to be confirmed in published studies. However, many anecdotal examples indicate that such events can occur, and great care must be taken to minimize the risk of such potentially serious complications.

Trial results showed no differences in rates of re-intervention - either repeats ablation or hysterectomy or both - between first- and second-generation ablation up to 5 years' follow-up. Only one small trial reported a clear difference at 10 years, but this should be interpreted cautiously because if repeated hysteroscopy is considered a surgical procedure, the difference is not significant, and no report provided the number of women transitioned through menopause. A recurrent comment about newer techniques that rely on 'devices' inserted into the uterine cavity to destroy the endometrium involved the incidence of equipment failure. This may represent expected 'teething problems' associated with new equipment. However, given that the older methods are extremely simple (a loop, laser, or diathermy to destroy the endometrium below it) and that newer techniques are potentially complex (microwaves, bags of fluid, etc.), the potential remains for mechanical break-down to occur. In addition, considerable experience in intrauterine cavity assessment and manipulation is required for safe use any of these devices.

Comparison of different types of first-generation ablation techniques

First-generation ablation techniques have been acknowledged traditionally as the 'gold standard' by which other, newer procedures were judged (*Papadopoulos, Magos, 2007*). Improvement in menstrual bleeding and satisfaction seems to be similar between first-generation techniques. The complication profile between techniques is slightly different; for example, fluid overload was more likely with laser ablation than with TCRE and was more likely with TCRE than with vaporising electrode ablation. However, it is likely that operator safety is a much more important arbiter of patient safety than the instrument itself. Duration of surgery was longer with the laser than with TCRE and was longer with TCRE than with vaporising electrode ablation. Equipment failure was more likely with laser ablation than with TCRE, and the procedure was more difficult with TCRE than with vaporising electrode ablation.

Comparison of different types of second-generation ablation techniques

Bipolar radiofrequency ablation was associated with significantly higher rates of amenorrhea than was balloon ablation up to 12 months' follow-up, but researchers report no significant differences at 2, 5, and 10 years' follow-up. In accordance with the amenorrhea report, the satisfaction rate is higher at 12 months for bipolar radiofrequency ablation but trials show no significant differences at 6 months' or 10 years' follow-up. Surgery was shorter with bipolar ablation, and premenstrual syndrome scores were reduced. No evidence shows that bipolar radiofrequency ablation resulted in lower rates of further surgery for heavy menstrual bleeding when compared to balloon ablation.

Bipolar ablation also increased rates of amenorrhea and satisfaction when compared with hydrothermal ablation. Procedure time was shorter with bipolar ablation and women were less likely to require additional surgery at later follow-up when compared to hydrothermal ablation. Amenorrhea rates appeared to be increased with microwave when compared with balloon, but trials reported no differences in Pictorial Blood Assessment Chart (PBAC) scores or satisfaction. Operation time was also reduced with

microwave ablation.

Comparison of different types of first-generation and second-generation ablation Technique

With reference to comparisons of different types of second-generation techniques versus first-generation techniques, thermal laser was more effective than TCRE in reducing blood loss (as measured by rates of amenorrhea), but research shows no differences in patient satisfaction between approaches (using the same measurement tools). Although rollerball ablation was more likely to result in amenorrhea when compared to cryoablation, trial results showed no difference in patient satisfaction between approaches. Patients appeared to be more satisfied with microwave than with TCRE at 2 and 5 years after surgery, but these findings were not significant at 1 and 10 years' follow-up. With regards to secondary outcomes, duration of surgery was consistently shorter with second-generation ablation, and procedures were more likely to be performed with the patient under local anaesthesia. Post-surgical pain was also more likely with some types of second-generation techniques such as thermal laser, balloon, and Hydro ThermAblator (HTA), but not all trials measured this outcome. Data show no significant differences between procedures in terms of improvement in dysmenorrhea.

Overall completeness and applicability of evidence

The diagnosis of HMB is based on subjective complaints and its impact on quality of life - not on objective measures of blood loss (*Munroe, 2006; NICE, 2018*). However, many women with heavy menstrual bleeding (HMB) referred from primary to tertiary care do not describe HMB when directly questioned, suggesting a tendency for broad description of menstrual characteristics to be re- framed as excessive bleeding at referral and during management (*Warner et al., 2001*). This is likely to result in women receiving inappropriate care and will influence the actual and perceived efficacy of treatment modalities for HMB. Published literature on endometrial destruction techniques for HMB covers a wide range of surgical methods and uses a variety of outcome measures to assess treatment success, making clear comparisons between studies difficult. Participant groups showed varied and often potentially important clinical factors such as the presence of uterine fibroids or a perimenopausal state, which were not mentioned in the inclusion or exclusion criteria. This is particularly important with longer follow-up studies. Current clinical approaches to HMB advise that medical therapy should be offered in the first instance, and it would be unusual in normal practice to advise endometrial resection or ablation without trying any medical therapies. Indeed, medical treatment with the levonorgestrel-releasing intrauterine system (Mirena, Schering) reduces menstrual blood loss (MBL) by 94% at 3 months, and it is equally effective as thermal balloon ablation (*Shaw et al., 2007, de Souza et al., 2010*), rollerball endometrial ablation (*Ergun et al., 2012*), and endometrial ablation. Surgical approaches to resect or ablate the endometrium are generally second-line after medical therapies. Fourteen published studies focused on women with failed medical management of HMB.

Published studies show wide variation in the outcome criteria used to assess the efficacy of endometrial ablation and resection techniques. No studies have used women's perceptions of HMB as an inclusion criterion nor women's perception of improvement as an outcome, even though this is the main diagnostic criterion. Several studies used the PBAC (*Higham, O'Brien & Shaw, 1990*), but entry and success criteria for PBAC score varied widely between studies. It is important to identify core

outcomes for future trials on treatments for HMB for better comparisons. The COMET initiative (Core Outcome Measures in Effectiveness Trials) is working towards this objective; it is hoped that this initiative will help to improve study outcomes for HMB (*COMET, 2018*).

Implications for practice

Second-generation techniques are safer, quicker, and equally effective when compared with first-generation techniques for treatment of HMB; also, the potential for second-generation methods to be performed under local anaesthesia offers a considerable advantage. Satisfaction rates and reduction in HMB are similar with both approaches. Second-generation endometrial ablation should be considered for women with a normal uterus presenting with heavy menstrual bleeding, which are not planning a present or future pregnancy.

Implications for research

Future studies should focus on comparing different second-generation approaches to clarify real advantages are associated with one method over the others; researchers should also compare third-generation versus second-generation approaches to assess which are better. Future research should use as inclusion criteria women's reports of heavy menstrual bleeding, according to International Federation of Gynecology and Obstetrics (FIGO) and National Institute for Health and Care Excellence (NICE) guidelines (Munro, Critchley & Fraser, 2012; *NICE 2018*). One alternative involves using a questionnaire to evaluate the woman's menstrual bleeding such as "the menstrual bleeding questionnaire", which has been developed and validated to improve the assessment of women with self-reported HMB in both clinical practice and research (*Matteson et al., 2015*). At this point, research shows no significant differences in bleeding outcomes between second-generation techniques; therefore it will be important to evaluate the cost of different techniques for both women and the healthcare system.

I.3.3. THE ROLE OF MINIMALLY INVASIVE SURGERY IN RARE CLINICAL CONDITIONS

I.3.3.1. Introduction

Minimally invasive surgery gained an important place in the fields of gynecologic surgery. There are now standardized operations that are performed by laparoscopy or by hysteroscopy like adnexectomy or hysterectomy. After passing the learning curve, these procedures can be undertaken with minimal complications, a low risk of conversion to laparotomy and early discharge from hospital, even in cases of large and multiple fibroids that historically would have required the open approach. This allows even the most complex of cases to now benefit for the advantages of the minimal access approach (*Mallick, Odejinmi, 2017*). Sometimes in surgery we can push the boundaries of the standard techniques.

One example is using laparoscopy in the treatment of large ovarian tumors and now there are in the literature published several cases with giant ovarian cyst operated by minimally invasive approach. Although laparoscopy is the gold standard approach for treating benign ovarian cysts, laparotomy is still used for removing giant ovarian cysts. Giant ovarian cysts (i.e., cysts of more than 15 cm) are very rare. Management

of ovarian neoplasms is determined by the cyst size and structure, the risk of malignancy and also by the patient age and desire to preserve fertility. Using a laparoscopic approach to remove giant ovarian cyst raises some concerns, such as risk of cyst rupture, limited working space, and risk of malignancy. We describe a case of a giant ovarian cyst that was successfully treated by laparoscopy.

Hysteroscopy proved her utility in the diagnosis of some rare conditions of the uterine cavity. There are some rare clinical situations where foreign bodies present in the uterine cavity and act as involuntary intrauterine devices (IUDs) (*Wokoma, Adum & Gbolade, 2010*). Unintentionally left behind foreign bodies in the uterus can act as an IUD and lead to uterine contraception or infertility. Hysteroscopy gained the title of “the gold standard technique” in the diagnosis of uterine pathology.

Another rare condition where hysteroscopy proved to be very useful for the diagnosis and management is genital tuberculosis. Tuberculosis remains a global health problem and the abdominal pelvic cavity is one of the common sites for extra pulmonary tubercular infections. Unlike pulmonary tuberculosis, genital tuberculosis is difficult to diagnose because there is no pathognomonic clinical feature or imaging findings for definite diagnosis. Usually female genital tuberculosis is diagnosed while investigating patients with amenorrhea or infertility. Sometimes genital tuberculosis can be difficult to be diagnosed because of particular forms of the disease. Nevertheless an early diagnosis is mandatory in order to enhance the chances for restoring fertility.

Published papers:

1. **Grigore M**, Blidaru I, Iordache F. Intrauterine foreign bodies, other than contraceptive devices and systems, may affect fertility – Report of two very different cases, *Eur J of Contracep Reprod Health Care* 2014; 19:141-143. **IF- 1,394**
2. **Grigore M**, Iordache F. Laparoscopic removal of a giant ovarian cyst: case report and review of the literature, *Minerva Chirurgia*, 2014; 27: 47-49.
3. **Grigore M**, Gafitanu D, Esanu I, Carauleanu A, Ilea A, Popovici R Genital tuberculosis – a rare but still existing disease, *Clin and Experim Obstet Gynecol* 2018; 45:620-621. **IF 0,404**

I.3.3.2. Material and methods

- ***Laparoscopic removal of a giant ovarian cyst: case report and review of the literature***

We present one case with a giant ovarian cyst laparoscopically excised. Although laparotomy is still used for giant ovarian cyst our case proved that minimally invasive technique is possible in well-selected cases.

- ***Intrauterine foreign bodies, other than contraceptive devices and systems, may affect fertility – Report of two very different cases***

We present two unusual cases where different foreign intrauterine bodies acted as involuntary IUD. The first case had endometrial osseous metaplasia, a rare condition and consequence of a true osseous metaplasia or could appear after a second-trimester abortion.

- ***Genital tuberculosis – a rare but still existing disease***

We present a case of genital tuberculosis (tubal and endometrial), which poses some difficulties both in the diagnosis but also in management. In this case ultrasound and laparoscopy and hysteroscopy was useful for the final diagnostic and proper management of the case.

I.3.3.3. Results

- ***Laparoscopic removal of a giant ovarian cyst: case report and review of the literature***

We present a case of a 23-year-old patient with a giant ovarian cyst. The cyst extended from the pelvis up to the epigastric area, but the exact size was difficult to approximate because the borders fell outside the range of the US probe (Fig. 34,35). Color Doppler exam showed no blood supply to the cyst or inside the cyst wall. Tumor markers (CA125, CA19-9 and HCG) were normal. Because no suspicion of malignancy was found, after patient counseling, a laparoscopy was scheduled. The patient was aware about the possibilities of converting the surgery to laparotomy if complications occurred during the procedure. After a 3 cm umbilical incision was made, we entered the abdominal cavity with the telescope to examine the exterior wall of the cyst and to check for the presence of adherence or signs of malignancy. We observed a giant, entirely cystic smooth mass, lying between the symphysis and the xiphoid. We observed a giant, entirely cystic smooth mass, lying between the symphysis and the xiphoid. The superior pole of the cyst was in contact with right liver lobe (Fig. 36). The cystic content was evacuated using a mini-laparotomy approach in a controlled manner, and 5 L of clear fluid was removed. Thereafter, a laparoscopic cystectomy was performed (Fig. 37). The patient had an uneventful postoperative recovery. The microscopic examination described a benign serous cystadenoma.

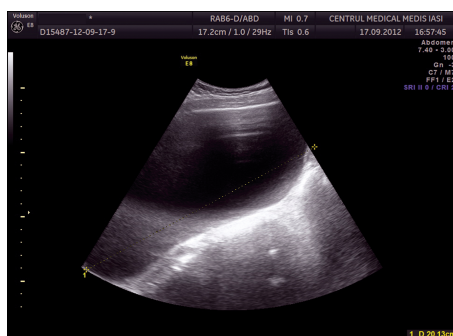


Fig. 34. Abdominal ultrasound of unilocular giant abdominal tumor.

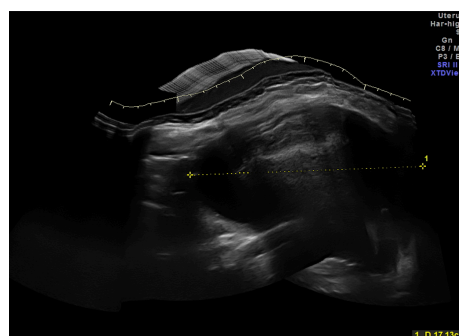


Fig. 35. Picture of the whole tumor.

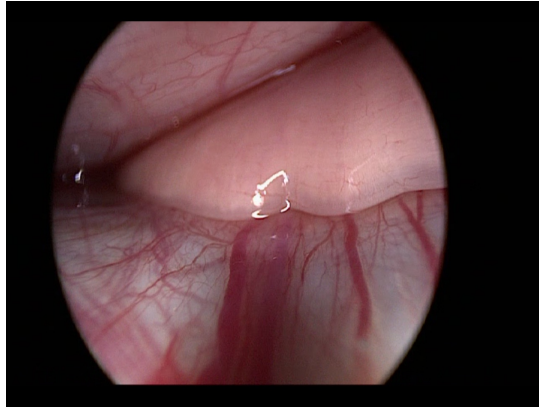


Fig. 36. Superior pole of the cyst; thin regular wall of the cyst in contact with right liver lobe.

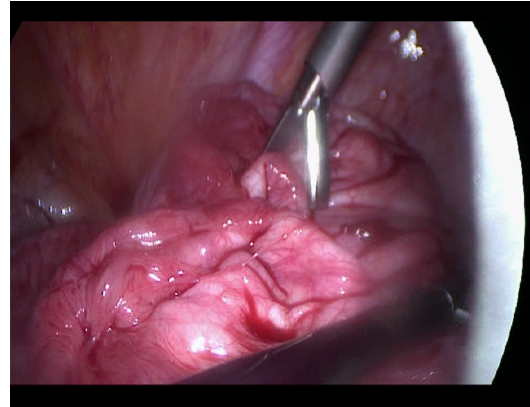


Fig. 37. Cyst wall after fluid aspiration.

➤ ***Intrauterine foreign bodies, other than contraceptive devices and systems, may affect fertility – Report of two very different cases***

CASE 1

A 41-year-old nulligravida presented with primary infertility for seven years. Her medical history was normal, and she had regular menses, without dysmenorrhoea. The patient's clinical gynaecological examination, hormonal profile and ovarian reserve, and the husband's semen analysis were normal. Transvaginal ultrasound revealed a hyperechogenic area in the endometrial cavity with posterior shadows (Fig. 38a). A hysteroscopy showed several coral-like bony fragments in the uterine cavity (Fig. 38b). The bony fragments were removed under hysteroscopic control with the grasping forceps. On histopathological examination, bony trabeculae were observed. After two months, the patient became spontaneously pregnant without any other treatment.

CASE 2

A 34-year-old woman, gravida 2, para 2, presented with a history of two years of metrorrhagia and pelvic pain following her second caesarean section. The patient, although not using any contraception since then, had not conceived. Ultrasound revealed small hyperechogenic foci in the isthmic part of the uterus (Fig. 39a). At hysteroscopy non-absorbable sutures in the isthmic region were seen; they were extracted with a grasping forceps under visual control (Fig. 39b). The patient's symptoms improved immediately after surgery. As she did not wish to become pregnant, after counselling, she decided that she and her husband would use condoms for some time.

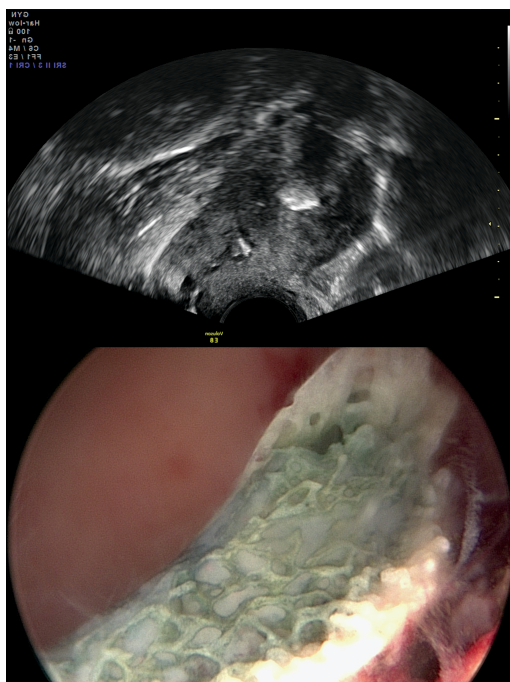


Fig. 38. Endovaginal ultrasound – hyperechogenic image in the uterine cavity (mimics an IUD) and hysteroscopy image – coral-like bony fragments inside of the uterine cavity.

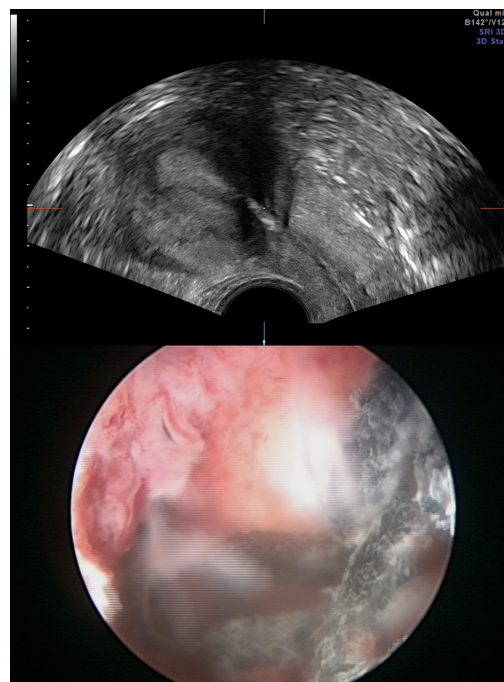


Fig. 39. Endovaginal ultrasound-hyperechogenic images in the isthmus part of the uterus and hysteroscopy image-unabsorbed suture material in the uterine cavity on the anterior wall.

➤ ***Genital tuberculosis – a rare but still existing disease***

A 23-year-old patient presented to gynecologist for primary amenorrhea. General physical and gynecological examination detected no abnormality, external genital organs being normal. The hormonal profile and the karyotype were normal. Ultrasound revealed normal ovaries with the presence of follicles. In the uterine cavity a round shape, 22 mm, hyperechogenic well-delimited structure was present, resembling a calcified uterine myoma (Fig. 40). A laparoscopically assisted hysteroscopy was performed (Fig. 41). The laparoscopy revealed adhesions in the pelvis and hysteroscopy revealed the uterine cavity completely filled with a snow-like mass (Fig. 42, 43). The diagnosis of tuberculosis was suspected and culture of the endometrium was positive for *Mycobacterium tuberculosis*. The patient received antituberculosis treatment. A uterine IUD was inserted in the uterine cavity. The patient had menstrual bleeding for 8 months and thereafter amenorrhea appeared again. A new hysteroscopy was scheduled and clinical images of tuberculosis were observed again. After hysteroscopy an anti-adhesions gel with hyaluronic acid was utilized in the uterine cavity.

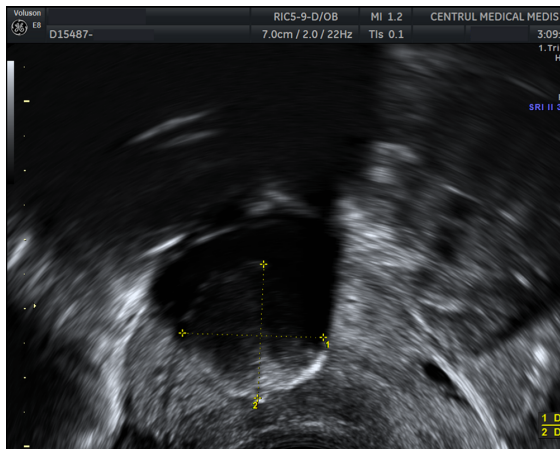


Figure 40. Endovaginal ultrasound- hyperechoic image in the uterine cavity.

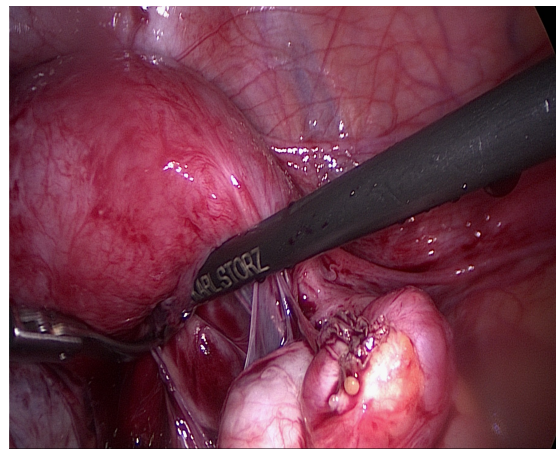


Figure 41. Laparoscopy- intraabdominal adhesions.

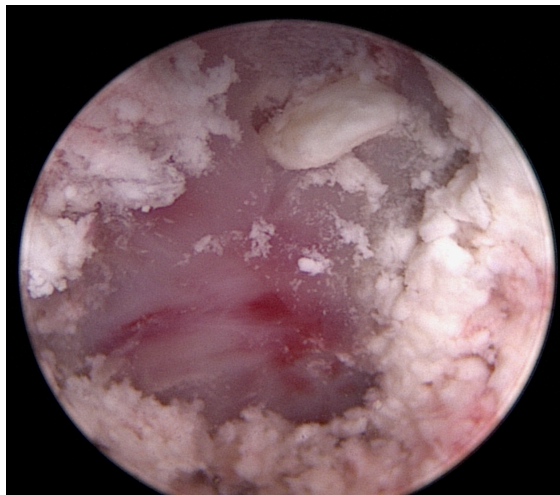


Fig. 42. Hysteroscopic image of the uterine cavity- white snow-like mass occupy the entire cavity.

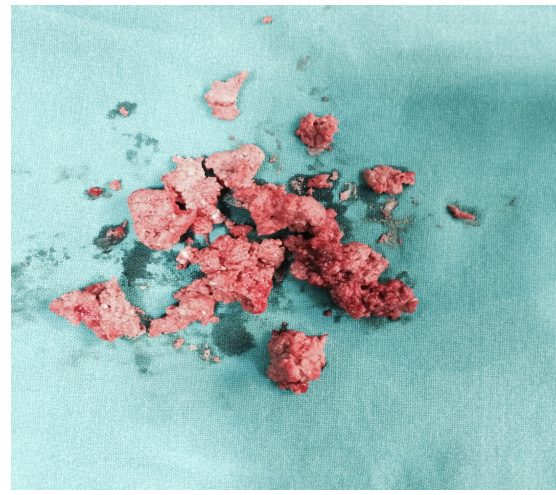


Fig. 43. The content extracted from the uterine cavity.

I.3.3.4. Discussion

➤ *Laparoscopic removal of a giant ovarian cyst: case report and review of the literature*

Although the gold standard approach for treating benign ovarian cysts is laparoscopy, laparotomy is still used to remove giant ovarian cysts. Using a laparoscopic approach for removing giant ovarian cyst raises some concerns. The main concern when operating an ovarian tumor by minimally invasive approach is risk of dissemination of atypical cells into peritoneal cavity in case of malignancy.

Therefore it is of great importance before deciding a minimally invasive approach in a giant tumor to establish the nature of the tumor. Both imagistic and tumoral markers are useful tools in clarifying this problem. There are some ultrasound signs useful to orientate toward the diagnosis of benign or malignant. The ultrasound signs of malignancy include bilateral lesions, thick internal septations (> 2 mm), and predominantly solid lesion, contrast enhancement of wall and vascular septation and solid components. If the cyst is unilateral, unilocular, has a thin wall without solid parts and ascites, malignancy risk is very low. In addition to ultrasonic findings, serum tumor markers (CA 125, CA 19-9, HE4) could be helpful. For the cyst found in our patient, there were no criteria met for malignancy.

Currently, laparoscopy is the gold standard management for benign ovarian tumors. In young patients who desire fertility, preserving ovarian tissue is an important issue. Giant ovarian cysts are rarely seen, especially in recent decades, because imaging modalities have improved and diagnosis has been made earlier. Ovarian cysts are considered large if they are more than 5 cm; they are considered giant if they are more than 15 cm. Usually giant ovarian cysts with slow growth are benign, but there have been reports of giant malignant tumors or low malignant potential. Giant ovarian cysts always require surgical management. Traditionally, this has meant a full midline laparotomy with a large abdominal incision. Minimally invasive surgery has been proposed for the management of giant cysts. Using a laparoscopic approach for removing giant ovarian cyst raises some concerns, including risk of cyst rupture, risk of malignancy, and limited working space. For large cysts that exceed the umbilicus, the risk of perforation could increase during the trocar insertion (*Ma et al., 2004*). Despite these risks, in the last years, several authors have reported cases of giant ovarian cysts managed by laparoscopy (*Salem, 2002, Ates et al., 2006*). However, the experience with laparoscopic surgery as a primary treatment modality for large adnexal masses is still limited.

The key problem in minimally invasive treatment of giant cysts is the aspiration of the cyst content to create space for performing laparoscopy and to avoid cyst rupture. Several methods for cyst aspiration were proposed in the literature, including suprapubic catheter and abdominal or endovaginal ultrasonic guidance. During ultrasound-guided cyst drainage, the needle could release from the cyst wall, and the fluid could spill into the abdominal cavity (*Ates et al., 2006*). In cases of dermoid cysts, this incident could be followed by chemical peritonitis, or in cases of mucinous cysts, a pseudomixoma peritonei could later occur. Even if the procedures are performed blindly or under ultrasound guidance, these techniques do not rule out the risk of spillage and do not allow inspection of the abdominal cavity, which represents an important step before performing cystectomy. For our case, after carefully assessing the abdominal cavity, we chose mini-laparotomy aspiration. We wanted to rule against any sign of malignancy, in which case aspiration would have been very dangerous for accidental spillage of the cyst content. Also, using mini-laparotomy aspiration allows the possibility of controlling the spillage after the aspiration by placing a file on the hole for aspiration. Sometimes, it is not possible to aspirate the entire contents of the cyst. For these cases, the suture placed forbids the spillage into the abdominal cavity, which is particularly important in cases of mucinous tumors for avoiding the occurrence of pseudomixoma peritonei. Decompression of the cyst followed by laparoscopy will allow safe laparoscopic excision. Although removing a giant ovarian cyst could be a challenge for the surgeon, laparoscopic excision of a giant ovarian cyst seems to be a safe and advantageous procedure. With proper patient selection, the size of an ovarian cyst is

not necessarily a contraindication for laparoscopic surgery. Giant ovarian cysts may be treated using a minimally invasive procedure when there is no risk of malignancy

Recently, the introduction of several rules in the ultrasonographic examination proved to be valuable in the evaluation of the ovarian tumors. International Ovarian Tumour Analysis (IOTA) group defined a standardized technique for preoperative classification of adnexal masses. This group defined 10 simple ultrasound rules (five rules for benign tumors B-rules and five rules for malignant tumors M-rule) that had high sensitivity and specificity and were applicable to a large number of tumours. If there are more M-rules in the absence of a B-rule, or one or more B-rules in the absence of a M-rule, the mass is classified as malignant or benign respectively. If both M-rules and B-rules apply, or if no rule applies, the mass could not be classified by ultrasound examination (Kaijser *et al.*, 2013). IOTA ultrasound rules proved to be highly sensitive and specific in predicting ovarian malignancy preoperatively and at the same time easy to train and use (Garg *et al.*, 2017). Some authors found that IOTA simple rules had higher diagnostic accuracy compared with RMI to discriminate between benign and malignant adnexal masses but in nearly 20% of cases IOTA results are inconclusive and need expert consultation (Auekitrungrueng *et al.*, 2019).

➤ ***Intrauterine foreign bodies, other than contraceptive devices and systems, may affect fertility – Report of two very different cases***

Foreign bodies in the uterus such as retained fetal bones or unabsorbed suture material can act like IUDs. The presence of bone fragments in the uterine cavity is generally associated with a history of previous, second-trimester abortion. The incidence of this condition is not fully known, but Ghaffari estimated an incidence of 0.02% among women with infertility (Ghaffari, Tehraninejad & Kiani, 2009). Makris estimated an incidence of 0.15% according to the hysteroscopies performed in an infertility clinic (Makris *et al.*, 2006). Because this incidence is in a population with already abnormal findings, the incidence in the general population is much lower.

Endometrial ossification may cause involuntary contraception by three different mechanisms: prevention of implantation as a result of obliteration of the uterine cavity (mechanical effect), increased prostaglandin production, and direct toxicity of osseous particles on the embryo (embryo toxicity) (Onderoglu *et al.*, 2008). Endovaginal ultrasound plays an important role in the diagnosis of patients with osseous metaplasia. In our case, the patient denied any other pregnancy, so it probably was a true osseous metaplasia.

The characteristic hyperechogenic pattern is strongly suggestive for the diagnosis. Diagnosis is confirmed after hysteroscopy, which should be regarded not only as a diagnostic tool, but also as a therapeutic one.

The second case had unabsorbed suture material after a caesarean section resulted in foreign bodies acting as an IUD. The presence of unabsorbed suture material is a condition very rarely reported in the literature. The low incidence could be explained by the fact that material usually used for uterine suture is absorbable. In very rare cases, where non-absorbable material is still used, these sutures could act as a foreign body. The symptomatology caused by this material includes pelvic pain, metrorrhagia and infertility. The suture material can act as an IUD, and the mechanism is probably the same as for bone metaplasia. The diagnosis, which could

be suspected based on the patient's history and on hyperechogenic foci in the region of the uterine scar, is confirmed with hysteroscopy. Hysteroscopy is useful for removing the foreign body under direct visual control. Because of these adverse effects, we propose that for uterine suture, the suture material should always be absorbable to avoid such complications.

Foreign intrauterine bodies, such as foci of osseous metaplasia or unabsorbed suture material, are rare clinical conditions that can cause infertility. Ultrasound is useful as a screening tool, and the presence of hyperechogenic foci in the uterine cavity necessitates hysteroscopy. The latter is useful both for confirming the diagnosis, and for removing the foreign bodies and restoring fertility

➤ ***Genital tuberculosis – a rare but still existing disease***

Tuberculosis should be always being considered, while investigating patients with infertility and amenorrhea, especially in the regions that are endemic for the disease. However because of the large mobility of the population in nowadays, even in well-developed countries we should bear in mind the possibility of genital tuberculosis when confronting with infertility and primary or secondary amenorrhea.

Pelvic tuberculosis can be caused by reactivation of the organism (spread via blood stream, lymphatic system or direct from the involved abdominal organs such as intestines) or rarely by sexual transmission (*Hasanzadeh et al., 2014*). Usually genital tuberculosis involves fallopian tubes (95-100%), endometrium (50-60%) and ovaries (20-30%). Very rarely uterine cervix or vulvar region can be affected ^{3,4}. Female genital tuberculosis is an important cause of infertility, amenorrhea or hypomenorrhea, especially in developing countries where tuberculosis is endemic⁵. Infertility is typically explained by fallopian tubes and a blockage of ovum transport either and/or pathology in the endometrium (*Hasanzadeh et al., 2014*). Hypomenorrhea or amenorrhea are caused by intrauterine adhesions and the degree of menstrual disorder is in direct correlation with the extent of the adhesions. Other symptoms that could rarely appear in genital tuberculosis are pelvic pain, ascites and pelvic mass and in these cases the disease can be easily confused with ovarian cancer or peritoneal carcinomatosis. CA-125 level, a tumor marker for ovarian cancer may also increase in tuberculosis. Laparoscopy with peritoneal biopsy provided rapid and correct diagnosis of abdominal tuberculosis and should be performed early in suspected cases. For endometrial tuberculosis hysteroscopy is extremely useful and may reveal various forms of intrauterine adhesions from mild adhesions to severe one (Asherman syndrome). In our case hysteroscopy, revealed a particular aspect, entire cavity being filled with white, snow-like caseum. Once the disease diagnosed the anti tubercular treatment should be initiated. Unfortunately, even if the tuberculostatic treatment was initiated after several months amenorrhea repapered in our case. We performed a second-look hysteroscopy and images suggestive for endometrial tuberculosis was observed. A local anti-adhesions gel with hyaluronic acid proved to be efficient.

Tuberculosis should be always being considered, while investigating patients with infertility and amenorrhea, especially in the regions that are endemic for the disease. However because of the large mobility of the population in nowadays, even in well-developed countries we should bear in mind the possibility of genital tuberculosis when confronting with infertility and primary or secondary amenorrhea.

Our case demonstrates that even diagnosed, sometimes endometrial tuberculosis can be difficult to be managed. Although the correct medical treatment was applied

the uterine cavity proved to be affected by the disease. This observation is particular important in young women with desire to conceive. It is a fact that genital tuberculosis could lead to female infertility. In cases with endometrial tuberculosis even IVF treatments have very small chances for success. Therefore, an early diagnosis is mandatory in order to enhance the chances for restoring fertility.

In the last years, polymerase chain reaction (PCR), especially nested protocol has been found to be the most sensitive technique for rapid detection and differentiation of *M. tuberculosis* complex in paucibacillary clinical conditions (Cheng, Yew, Yuen, 2005). The heat shock protein (*hsp65*) gene is highly conserved and has already been targeted for the diagnosis of *M. tuberculosis* complex. This gene is slightly less conserved than the 16S rRNA sequences and therefore, it provides better opportunity to target genetically related species of mycobacteria, i.e., *M. tuberculosis* complex from *M. tuberculosis* (Zakham et al., 2012). The heat shock protein gene (*hsp65/groEL2*) of *Mycobacterium tuberculosis hsp65* identified by PCR can be used as a noninvasive screening test for early diagnosis of GTB. Chaubey et al studied this method on sample of menstrual blood (MB) and endometrial tissue (Chaubey et al., 2019). They concluded that the *hsp65* nested PCR of MB can thus be used as a noninvasive screening test for rapid detection GTB. However, further study is needed involving more cases with multiple samples for the validation of the observation made in this preliminary study.

I.4. STUDIES IN THREE-DIMENSIONAL ULTRASOUND AND MODERN IMAGISTIC TECHNIQUES IN OBSTETRICS AND GYNECOLOGY

I.4.1.INTRODUCTION

Over the past 40 years, ultrasound imaging has revolutionized gynecologic medicine. Despite the obvious advantages of magnetic resonance imaging (MRI) and computer tomography (CT), the ultrasound remains the first-line modality for gynecologic applications. Conventional sonography provides two-dimensional (2D) views of three-dimensional (3D) structures that an experienced sonographer has to examine dynamically in order to adequately assess complex 3D anatomical features.

Although its clinical importance is well established, 2D ultrasonography has several limitations, which can be overcome with the help of 3D ultrasonography (3D US). 3D volume ultrasound data is composed of multiple 2D planes with known spatial relationships. The process of 3D scanning consists of four basic steps: data acquisition, volume analysis and processing, image animation (cine loop), and archiving. Uniquely, 3D sonography allows demonstration of the coronal plane perpendicular to the transducer face, thus facilitating the identification of surface irregularities, which can then be accounted for during volume measurement (*Maymon, et al., 2000*).

Once the volume data has been stored, a single point in space can be selected and visualized in all three perpendicular planes. The examiner can navigate through the volume, keeping track of a single point in space in all three planes. This is valuable not only for the imaging of different organs in the coronal plane, but also for measuring distances and even volumes of organs. It is possible to rotate the structure analyzed by spinning the image in any of the planes. Another advantage of the 3D ultrasonography is navigation through a single plane while watching the corresponding effect on the other two planes. This provides complete control of the volume in order to view it or perform measurements in any display desired.

Modern 3D ultrasound systems allow the reconstruction of images in rendering and multiplanar modes and also the possibility of image post-processing. The render mode with surface or transparent reconstruction facilitates the detailed assessment of fetal surface, particularly face and limbs, while X-ray reconstruction helps with the assessment of fetal skeleton ossification. The multiplanar mode enables the clinician to obtain an unlimited number of two-dimensional planes, derived from the rotation of the image on the three orthogonal axes (x,y and z). Advocates of 3D US (*Pretorius, Nelson, 1995*) suggest that these features offer the user the following advantages in comparison to two-dimensional sonography:

1. Accurate measurement of organ dimensions and volumes
2. Improved information on anatomy and blood flow
3. Improved assessment of complex anatomic anomalies
4. Better specificity with regard to the confirmation of normality
5. Standardization of the sonographic examination procedure
6. Reduced scanning times with cost-effective use of equipment and sonographer's time
7. Possibility to post process the volumes

8. Telemedicine and tertiary consultation.

Although much of the initial interest in 3D US, particularly in obstetrics, was focused on the display of surface-rendered images, the applications of 3D US gradually expanded to domains such as multiplanar reconstructions, tomographic slicing, volume calculations, image manipulation, and other forms of image rendering. The role of 3D US in gynaecology includes the assessment of Müllerian abnormalities, intrauterine devices, the endometrium, polyps, the location of a pregnancy, and the mapping of uterine leiomyomata, ovarian follicles, adnexal lesions, and the pelvic floor.

Volume contrast imaging (VCI) increases the resolution and contrast while also reducing the occurrence of artifacts. VCI can be applied to any multiplanar, tomographic and selected plane display in order to enhance the image clarity and contrast. The image appears as a plane but in reality it is a fine slice.

Tomographic ultrasound imaging (TUI) is one of the latest applications in ultrasound. It is a novel way of displaying diagnostic information contained in a static or dynamic 3D dataset. In particular, it allows the display of numerous 2D slices from any given volume on any of the three orthogonal planes. In some clinical situation TUI is superior to magnetic resonance imaging because it is easily possible to change slice width, to rotate the images, to magnify images, and to rotate images to any directions. This function is extremely useful for detailed assessment of volumes both in obstetrics and in gynecology. In gynecology for example TUI proved to be a reliable tool for determining the position of the implanted tension-free transobturator tape in the treatment of stress urinary incontinence. Graf et al performed a study on 32 women with urinary stress incontinence, which underwent tension-free transobturator tape procedure and routine sonographic control at day 1 postoperatively and at follow-up visit. Measurements of the position of the tape demonstrated high intraclass correlation coefficients and the authors concluded that TUI could be a reliable method for determining the position of the tape (*Gräf et al., 2016*).

The latest achievement in the field of 3D/4D ultrasound is the **High Definition live (HDlive) technology**. HDlive uses an adjustable light source and software that calculates the propagation of light through surface structures in relation to the direction of the light (*Nebeker, Nelson, 2012*). The virtual light source produces selective illumination, and the respective shadows are created by the structures where the light is reflected (*Bonilla-Musoles et al., 2013*). This combination of light and shadows increases depth perception and produces remarkable images that appear more natural than those obtained via more conventional 3D US. Depending on the desired viewing angle, the virtual light source can be placed in the front, back, or lateral sides until the best image is achieved. When the light source is positioned behind the area of interest, a spectacular effect of translucency can be obtained. The software can process all the images stored in the memory of the machine (*Bonilla-Musoles et al., 2013*). HDlive was developed especially for obstetric usage because it provides a natural and realistic appearance of the fetus, but it has also proven its usefulness in gynecology.

One advantage of 3D US is the possibility to archive and share volumes. This is useful when reviewing cases as well as for teaching purposes. Ultrasonography has rapidly developed rapidly in short period of time, from B-mode grey-scale maps and real-time imaging, to the modern techniques like 3D and 4D ultrasound. In this dynamic context, my ongoing scientific interest in 3D ultrasound in obstetrics and gynecology has resulted in writing more than 21 scientific articles over the course of

the last decade. My research in this field has been directed towards in the **three directions** of study outlined below:

I.4.2. 3D ULTRASOUND AND HDLIVE TECHNOLOGIES IN OBSTETRICS

I.4.2.1. Background

Ultrasound has a great contribution in obstetrics and its application and use is now widespread. Ultrasound is useful in prenatal diagnosis and also in fetal therapy. Ultrasound devices are non-invasive tools that are safe both for the fetus and for the mother. Ultrasound examination is useful for: confirmation of pregnancy and multiple gestation, estimation of gestational age, localisation of placenta and monitoring of fetal wellbeing, evaluation of caesarean section scar integrity and post partum haemorrhage, diagnosis of ectopic pregnancy or gestational trophoblastic disease. Today, 2D sonography represents the most important tool for the diagnosis of congenital fetal malformations. The prevalence of fetal structural malformations is 3 to 5% of all pregnancies (*Garne et al 2010*). The diagnosis of congenital malformation provides information for decisions during pregnancy and appropriate treatment perinatally. We assist to an improvement of perinatal and long-term outcome. The management of antenatal diagnosis of malformations is related to the severity of the malformations detected. Major congenital defects can now be diagnosed early during pregnancy and this is important especially in countries where only before viability is termination of pregnancy authorized by law. The gestational age at which a severe malformation is diagnosed is therefore important to further management of the pregnancy. Moreover over the last few decades' fetal surgery has developed due to rapid advances in imaging and instrumentation technology. The progresses in fetal imaging have markedly improved prenatal diagnostic accuracy and paved the way for the development of novel in-utero interventions. Great success has already been seen the treatment of several anomalies such as myelomeningocele, congenital cystic malformations of the lung, twin-twin transfusion, and sacrococcygeal teratomas. Although still limited, these innovative techniques have unique potential to improve outcomes in the most devastating fetal anomalies (*Maselli Badillo, 2016*).

In majority of countries worldwide, the standard ultrasound examination for evaluating the morphology of the fetus is performed between 18 and 22 weeks. However, most recent literature shows a significant improvement in detection of fetal abnormalities in first trimester of pregnancy. There are some clear benefits of first trimester ultrasound: early detection and exclusion of major congenital anomalies (not compatible with life or followed by severe handicap), reassurance, and relatively easier pregnancy termination if required (*Syngelaki et al., 2011*). A systematic review and meta-analysis was recently performed to assess the diagnostic accuracy of two-dimensional transabdominal and transvaginal ultrasound in the detection of congenital fetal anomalies prior to 14 weeks' gestation. This study evaluated the factors that may impact the detection rates including population characteristics, gestational age, healthcare setting, ultrasound modality, use of an anatomical checklist for detection of first-trimester anomalies and type of malformation included in the study. The authors analyzed 30 studies published between 1991 and 2014. The pooled estimate for the detection of major abnormalities in low-risk or unselected populations (19 studies, 115 731 fetuses) was 46.10% (95% CI, 36.88–55.46%). The detection rate for all

abnormalities in low-risk or unselected populations (14 studies, 97 976 fetuses) was 32.35% (95% CI, 22.45–43.12%), whereas in high-risk populations (six studies, 2841 fetuses) it was 61.18% (95% CI, 37.71–82.19%). Detection rates of first-trimester fetal anomalies ranged from 32% in low-risk groups to more than 60% in high-risk groups, demonstrating that first-trimester ultrasound has the potential to identify a large proportion of fetuses affected with structural anomalies. It was found a statistically significant relationship between the use of a standardized anatomical protocol during first-trimester anomaly screening and its sensitivity for the detection of fetal anomalies in all subgroups. This recommends the use of a standardized anatomical protocol improves the sensitivity of first-trimester ultrasound screening for all anomalies and major anomalies in populations of varying risk (*Karim et al., 2017*).

Early detection of malformation is refined with improvement in imaging technology. Using 3D technique in obstetrics has many advantages, including an enhanced diagnosis of fetal anomalies, accurate volume measurement of organs with irregular shape, and offering the possibility of storing the volumes.

3D US is superior in demonstrating superficial fetal defects such as facial clefts and studies from several groups have shown that the technique has a high sensitivity for diagnosing defects of the secondary palate, which are rarely detected by 2D ultrasound (*Campbell, 2007*). In fetal echocardiography the capture of a volume of the beating fetal heart (called spatio-temporal image correlation) allows the study of tomographic slices of cardiac anatomy and movement in slow motion.

The introduction of high-resolution endovaginal probes and recent developments in the volumetric sonography has permitted detailed evaluation of the morphology of the embryo in utero (*Pooh, Shiota & Kurjak, 2001*). The possibility of studying an embryo at this stage introduced the term sonoembryology (*Timor-Trisch, Peisner, Raju, 1990*). The potential benefits of 3D US in the first trimester would be a reduction in the exposure time of the embryo to the ultrasound system, the possibility of storage of the volumes, and its later processing and analysis without the presence of the patient (*Kurjak et al., 1999*). Ultrasound is unique in that it is safe even for the smallest embryo and that the examination is convenient and causes no discomfort. Four-dimensional sonography can supplement the study of fetal behavior and is useful for observing specific movements, such as yawning, sucking, smiling, crying or blinking. This technology offers the basis for the study of fetal neurophysiologic development and simultaneous detection of anatomic pathology.

Because imaging techniques have evolved constantly during last decades, the diagnosis in areas of obstetrics and gynecology constantly improved. Developed more than 15 years ago, 3D US has been widely used in clinical practice in the last decade and continues to widen its reach as researchers explore innovative new applications. HDlive was developed especially for obstetric usage because it provides a natural and realistic appearance of the fetus, but its use in gynecology should not be neglected (*Raga et al., 2013*). A main application of this technology is studying normal and pathologic embryonic and fetal development. HDlive could be a key in perinatal research and could provide a better understanding of the development of the early embryo and the fetus. HDlive technology could be used during all three trimesters of pregnancy. This technology could be useful in studying normal embryonic and fetal development, as well as in providing information for fetuses at risk for specific congenital malformations by confirming normality. Because of the natural pictures of the fetus that provide, HDlive could be beneficial for increasing the fetal maternal bonding, which represent an important factor for a healthy behavior during the

pregnancy. This technology could be useful in studying normal embryonic and fetal development, as well as in providing information for fetuses at risk for specific congenital malformations by confirming normality (*Bonilla-Musoles et al., 2013*). Motherhood is an extraordinary opportunity for both the mother and child to participate in a relationship that is irreplaceable in value and meaning (*Rustico et al., 2005*). HDlive may play a role in further strengthening this relationship between parents and their future child, but the exact role remains to be established in the future. Several authors have studied the effects of volumetric sonography on fetal-maternal bonding. According to Steiner, patients recognize easier 3D images of the fetus than 2D images, and they feel more attached to the fetus after 3D ultrasound (*Steiner et al., 1994*).

Although all these advantages need to be further explored. Within the direction of researches on 3D ultrasound in obstetrics, I have published 6 articles (original research articles, review articles and case reports) in journals indexed in ISI Web of Science with impact factor.

Published papers

1. **Grigore M**, Gafitanu D, Socolov D, Grigore A, Nemeti G, Micu R. The role of 4D US in evaluation of fetal movements and facial expressions and their relationship with fetal neurobehaviour. *Med Ultrason* 2018; 4:88-94. **IF 0,8**
2. **Grigore M**, Mareş A. The role of HDlive technology in improving the quality of obstetrical images. *Med Ultrason* 2013; 15:209-214. **IF 1,54**
3. **Grigore M**, Vulpoi C, Preda C, Martiniuc V, Vasiliu I, Gorduza V. Using HDlive technology to diagnose Turner syndrome in the first trimester of pregnancy: clinical cases presentation and literature review. *Acta Endocrinol* 2015; 11:93-98. **IF-0,23**
4. **Grigore M**, Iliev G. Diagnosis of sacrococcygeal teratoma using two and three-dimensional ultrasonography: two cases reported and a literature review. *Med Ultrason* 2014;16:274-277. **IF 1,32**
5. **Grigore M**, Furnica C, Esanu I, Gafitanu D. Pentalogy of Cantrell associated with unilateral anophthalmia: Case report and literature review. *Medicine (Baltimore)*. 2018; 97:e11511. **IF 1,63**
6. **Grigore M**. Early diagnosis of limb body wall complex: a case report. *Clin Experimental Obstet Gynecol* 2014; 41:354-356. **IF 0,73**

I.4.2.2 Material and methods

- ***The role of 4D US in evaluation of fetal movements and facial expressions and their relationship with fetal neurobehaviour***

We performed a systematic literature search of PubMed/MEDLINE, Google Scholar, and Ovid for all research articles using the terms “fetal neurobehaviour” “facial expressions” “ultraosund” “four-dimensional” “4D” published up until May 2017. The references of those articles were then reviewed and additional publications

were evaluated. The paper represent an up-date of the published papers of the literature on fetal movements, facial expressions and their relationship with fetal neurobehaviour and at the same time illustrate with personal images different fetal expression useful for the evaluation of fetal neurobehaviour.

- ***The role of HDlive technology in improving the quality of obstetrical images.***

Herein, we provide a pictorial essay focused on HDlive technology and its applications in obstetrics. The volumes and pictures were obtained with a Voluson E8 (General Electric, Zipf, Austria) with a volumetric transvaginal and abdominal transducers.

- ***Rare clinical conditions***

- *Using HDlive technology to diagnose Turner syndrome in the first trimester of pregnancy: clinical cases presentation and literature review*

Turner syndrome, a genetic disorder with an exclusively feminine phenotype, is caused by complete or partial X monosomy in some or all cells. The condition is characterized in adults by low stature and gonadal streaks in more than 90% of cases. Although diagnosis is made usually after puberty, there is now the possibility to detect the syndrome prenatally. We present two clinical cases where Turner syndrome was diagnosed in the first trimester of pregnancy using 2D and 3D US and genetically analysis.

- *Diagnosis of sacrococcygeal teratoma using two and three-dimensional ultrasonography: two cases reported and a literature review*

The occurrence of a fetal tumor is rare. Prenatal diagnosis of this condition is important for monitoring of the affected fetuses and for establishing the mode and time of delivery. We describe diagnosis of two cases of fetal sacrococcygeal teratoma where 3D US proved to be useful both in the diagnosis and patient counseling. The combination of 2D and 3D US enable the diagnosis to be made during the first trimester of pregnancy.

- *Pentalogy of Cantrell associated with unilateral anophthalmia: Case report and literature review*

Pentalogy of Cantrell, a very rare congenital condition, has an estimated incidence of 5.5 per 1 million live births. It includes five defects: a midline supraumbilical wall defect, a diaphragmatic defect, a cleft distal sternum, a defect in the diaphragmatic pericardium, and an intracardiac defect. We present a case of pentalogy of Cantrell associated with cranioschisis and unilateral anophthalmia diagnosed at 14 weeks of amenorrhea with two-dimensional and three-dimensional ultrasound.

- *Early diagnosis of limb body wall complex: a case report*

Limb body wall complex is a rare polymalformative syndrome. The majority of cases presented in the literature have been diagnosed in the second or third trimester

of pregnancy. We present a case of LBWC diagnosed in the first trimester of pregnancy. The combination of two-dimensional and three-dimensional ultrasound proved to be useful for establishing the diagnosis and differentiating from other abdominal wall defects.

I.4.2.3. Results

- *The role of 4D US in evaluation of fetal movements and facial expressions and their relationship with fetal neurobehaviour*

Herein, we provide a pictorial essay focused on the applications of 4D US on fetal movement and facial expressions. 3D US and 4D US were performed with Voluson 730 Pro (General Electric, Zipf, Austria) and a Voluson E8 (General Electric, Zipf, Austria) with a volumetric transvaginal transducers. We several facial expressions as presented in the figures below (Fig. 44-47):

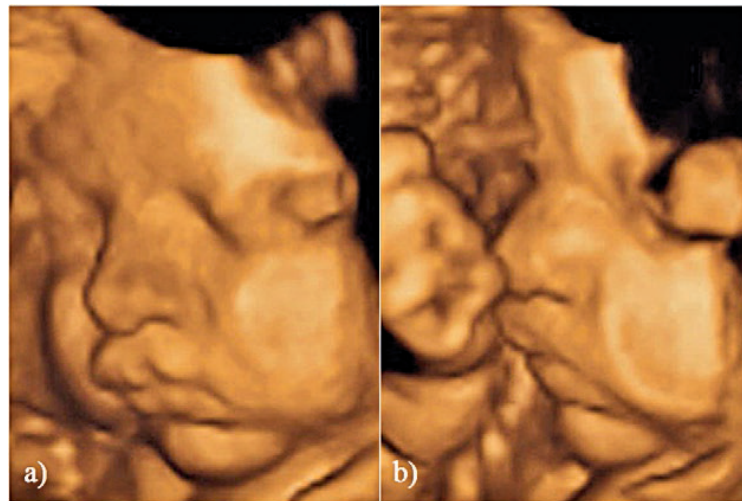


Fig. 44. 4D US image of fetal face at 32 weeks of gestation: a) image of the nose, mouth and cheeks are clearly observed; b) the fetus is touching his nose with the hand.

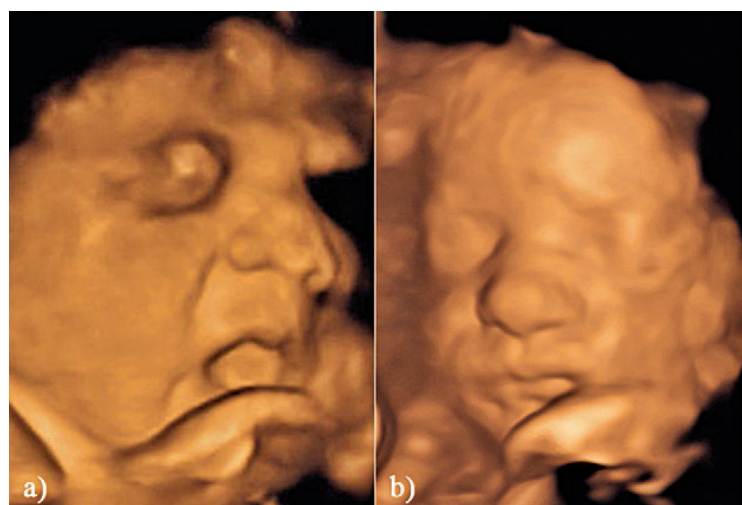


Fig. 45. 4D US image of the fetus at 33 weeks of gestation: a) the mouthing movement is observed; b) the same fetus observed while blinking.

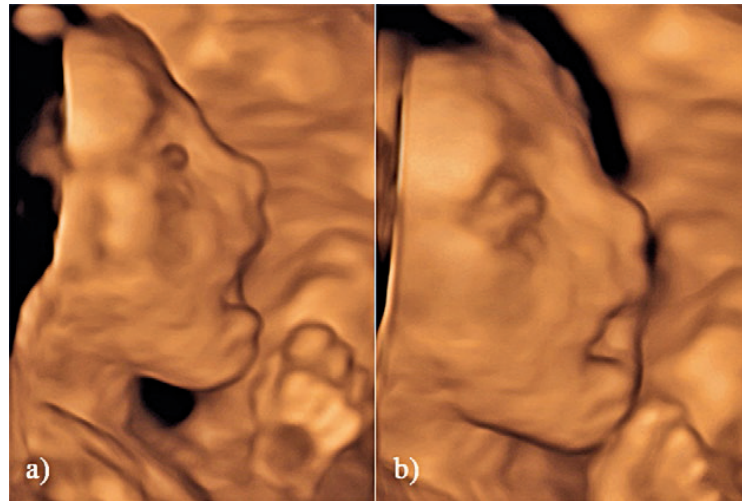


Fig. 46. 4D US image a fetus at 29 weeks of gestation: a) the profile view of the fetus while yawning; b) the same fetus with the hand near the face while yawning.

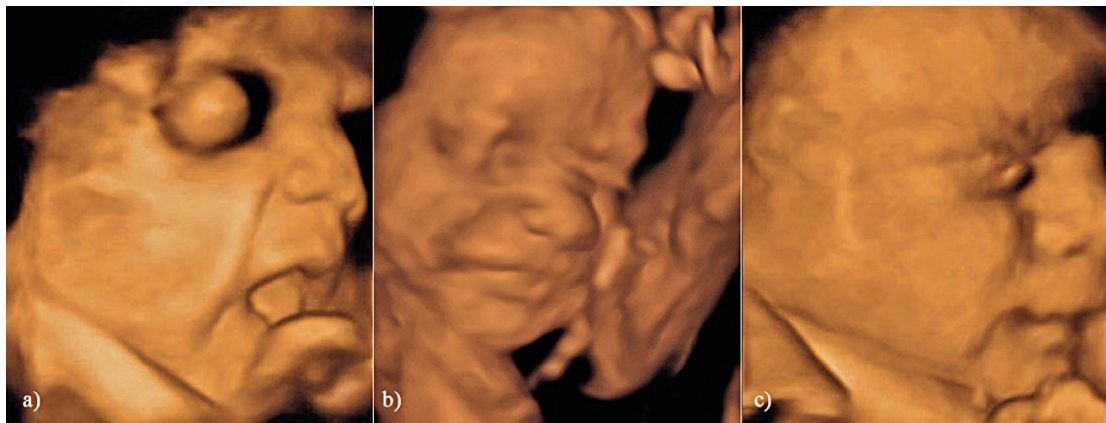


Fig. 47 a.4D US image of blinking at fetus while yawning 33 week of gestation. 4D US image of scowling at 33 weeks of gestation c. A 4D US image of smiling at 32 weeks of gestation.

- ***The role of HDlive technology in improving the quality of obstetrical images***

With the use of HDlive, both structural and functional developments in the first 12 weeks of gestation can be assessed more objectively and reliably. Figures 48- 51 represent several examples of first trimester embryos and fetuses examined with HDlive software.

In the second and third trimesters, images of fetal faces are very natural and could also create a deep connection with the parents. HDlive is useful not only in face examination, but also in examining the surface details: hands, feet, abdomen, or spine (fig 52). Also, the clear images of fetal genital organs are impressive (fig 53). Visualization of the fetal face has become one of the main applications of 3D ultrasound scanning (fig 54). Moreover by providing the natural pictures of the fetus, HDlive could increase the fetal maternal bonding, which is an important element for correct management of the pregnancy.

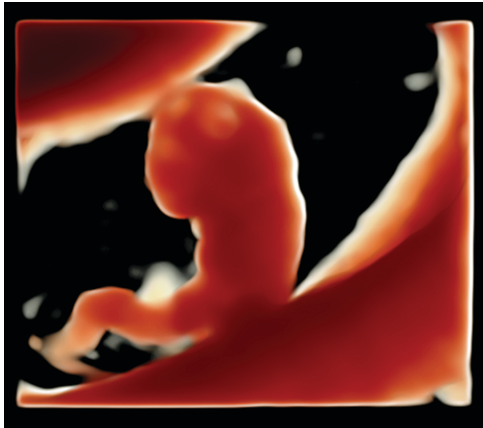


Fig. 48. HDlive at 8 weeks of amenorrhea.

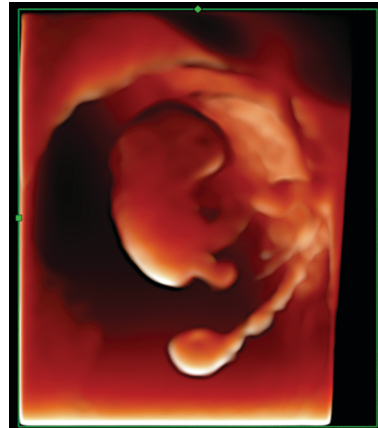

Fig. 49. The light is positioned behind the embryo and translucency effect is obtained

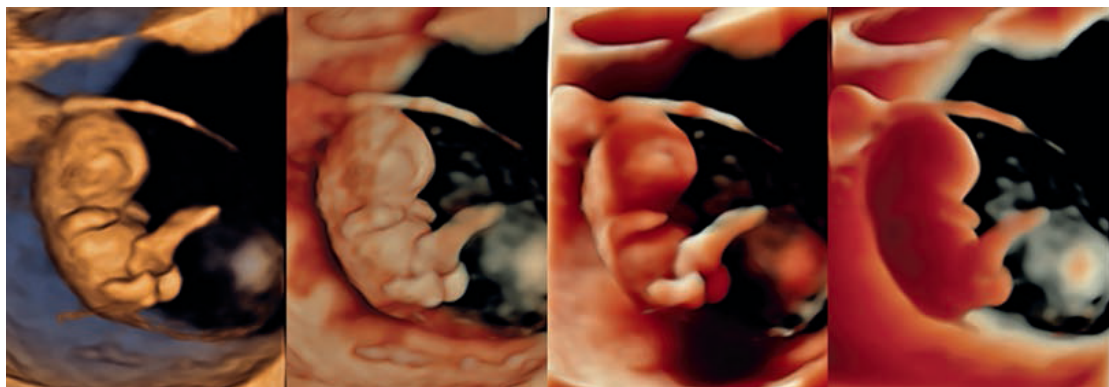

Fig. 50. HDlive at 9 weeks of gestation demonstrating the fetus and the yolk sac; the amnion can be seen as a spherical hyperechoic membrane.

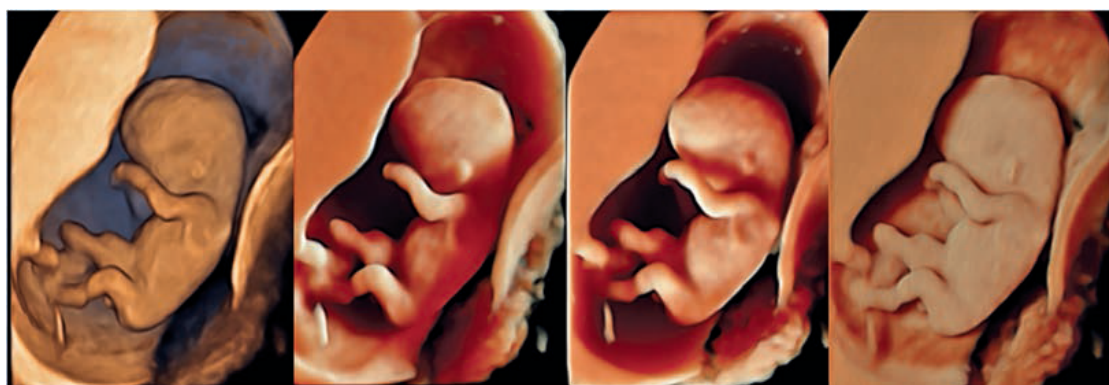


Fig. 51. HDlive at 12 weeks of amenorrhea - complete morphologic development is observed; the limbs are completely developed and their segments are discernible.

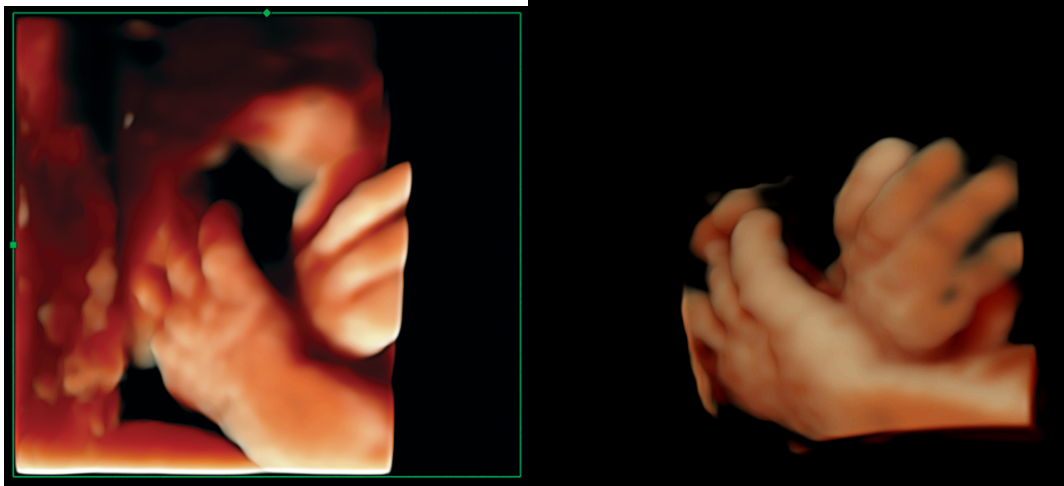


Fig. 52. HDlive images demonstrating the anatomic structures of the fetal fingers; the anatomy of the fetal hand depicted by 3D ultrasound and HDlive technology.

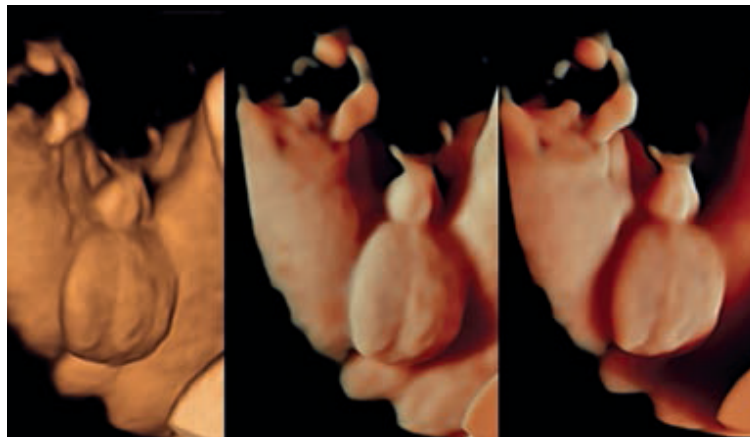


Fig. 53. External genital male genitalia can be clearly depicted by 3D HDlive.

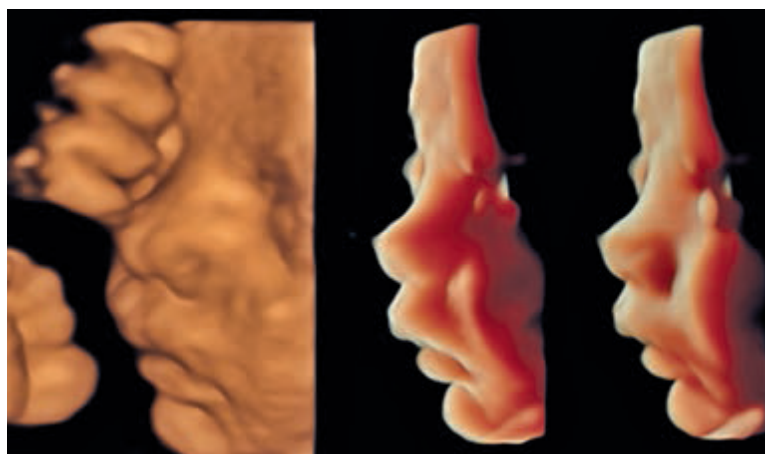


Fig. 54. Fetal face – 3D and HDlive surface rendering of a fetal face at 32 weeks.

- **Rare clinical conditions**

- *Using HDlive technology to diagnose Turner syndrome in the first trimester of pregnancy: clinical cases presentation and literature review*

The Turner syndrome was suspected because of specific ultrasound signs, and both 3D ultrasound and HDlive technology were helpful in formulating the diagnosis (Fig.55,56). The diagnosis was confirmed cytogenetically in both cases and by karyotype after an invasive prenatal technique. In one case, the fluorescent in situ hybridization, (FISH) technique was applied, and in the other case, the chromosomal anomaly was detected using G banding (57,58).

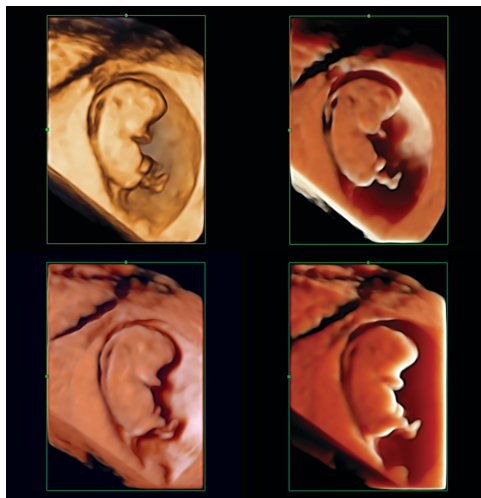


Fig. 55 Three-dimensional ultrasound and HDlive of first trimester pregnancy (9 weeks of amenorrhea) with generalized hydrops.

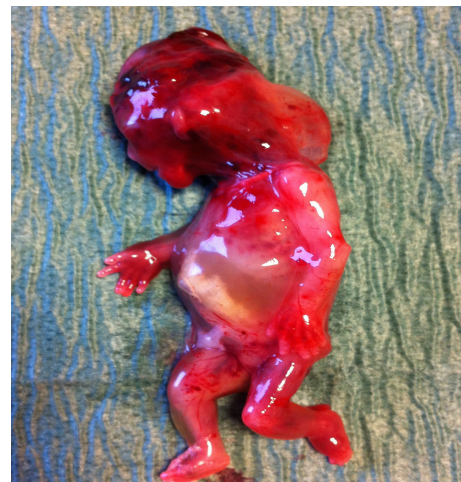

Fig. 56. The macroscopic imaging of the aborted fetus.

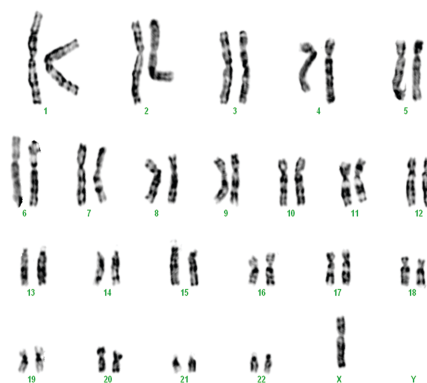


Fig. 57. G banding karyotype – X homogenous monosomy.

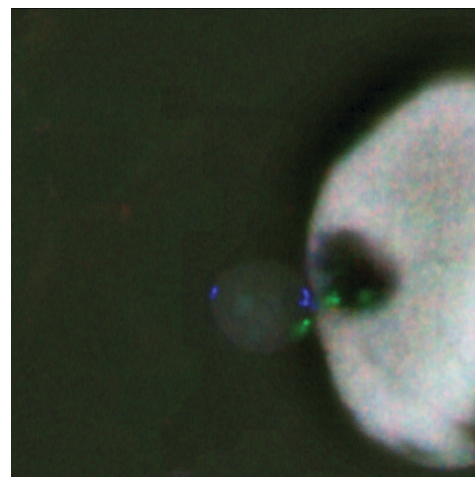


Fig 58. TS confirmed by FISH technique, using centromeric probes from Anevisyon®, blue signal for 18 chromosome; green signal for X chromosome.

➤ *Diagnosis of sacrococcygeal teratoma using two and three-dimensional ultrasonography: two cases reported and a literature review*

A 34-year-old patient, gravida 3 para 3, with 20 weeks of amenorrhea has presented for routine fetal examination. The 2D ultrasound revealed a bulky mass (97 x 68 x 67 mm) at the sacral area that was predominantly solid and had a few cystic components (Fig 59 a,b). The patient had a sonography in the first trimester of pregnancy, but at that time, the anomaly was not detected. No other fetal abnormalities were observed. A 3D ultrasound was performed with the volumetric transducer (Voluson 730 Pro, General Electric, Zipf, Austria). The 3D ultrasound depicted the relationship between the mass and the fetal pelvis and enabled the parents to better understand this anomaly (Fig 59 c,d). A diagnosis of a SCT type I was formulated. Because of the tumor's large size and the predominantly solid component, a poor prognosis was determined. The parents opted for a therapeutic abortion, and the diagnosis was confirmed thereafter

Case 2

A 32-year-old patient, gravida 1 para 1, with 33 weeks and 4 days of amenorrhea was referred for an ultrasound from an ob-gyn specialist who had discovered at ultrasound a mass in the sacral area. A 2D ultrasound examination revealed a large mass of 44 x 44 x 41 mm starting from the sacral area. Using a volumetric transducer, 3D ultrasound was performed with Voluson 730 Pro (General Electric, Zipf, Austria)(Fig. 60). No other fetal abnormalities were detected. The patient returned two weeks later at 35 weeks and 2 days gestational age. The previously identified mass had slightly increased in size to 57 x 46 x 44 mm. After a consulting examination with the neonatologist, pediatric surgeon, and anesthesiologist, delivery was scheduled to be performed in a tertiary center. A cesarean section was performed at 38 weeks amenorrhea, and a newborn (3100 g) was delivered. The prenatal diagnosis of SCT type II was confirmed, and surgery was performed. The child had a normal development. Three years later, the women become pregnant again and delivered a healthy newborn (38 weeks, 3200 g).

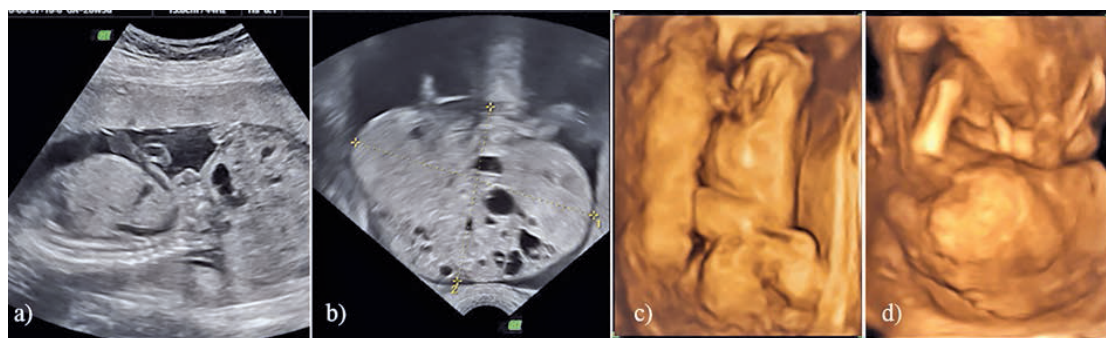


Fig. 59 Case 1: a) longitudinal plane- this fetus displays a huge complex, well-delineated solid mass (sacrococcygeal teratoma) in the sacral area, growing from the distal spine; b) coronal plane clearly shows the large size of the mass. The mass extends below the gluteal region and expands both laterally and anteroposteriorly and projects below the fetal body; c) The structure of the mass is complex, predominantly solid with a few cysts; d) The 3-D ultrasound images show characteristic features of sacrococcygeal teratoma in this second trimester fetus; e) 3D skeleton mode shows the relationship of the tumor with the skeleton. The skeleton 3D mode is particularly useful for differential diagnosis with lumbo-sacral meningocele or myelomeningocele

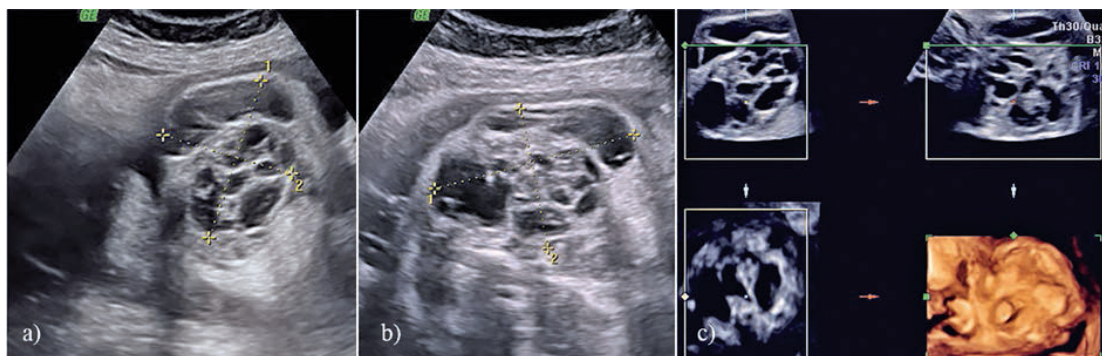


Fig.60. Case 2: a) Ultrasound picture of a sacrococcygeal teratoma diagnosed at 33 weeks of pregnancy. Note the large welldefined cystic mass originating from the fetal sacrum; b) The mass is cystic like and has a thick external wall. This sign is useful for a differential diagnosis with a meningocele, which has thin walls; c) 3D surface-rendered image enhances the cystic aspect of the tumor.

➤ *Pentology of Cantrell associated with unilateral anophthalmia: Case report and literature review*

A 42-year-old, gravida 3, para 2, came for medical examination because of amenorrhea. The woman had a child with a cardiac malformation- pulmonary artery stenosis. The combination of abdominal and vaginal sonography established the diagnosis of 14 weeks of amenorrhea with a plurimalformative syndrome: ectopia cordis, large suprabilical anterior abdominal wall defect, omphalocele, anomaly of the shape of the skull, and anomalies of the brain. Doppler examination and 3D ultrasound were particularly useful for observing the anomalies (Fig.61,62). The diagnosis of Cantrell pentology was formulated and after counseling the parents, the pregnancy was interrupted on the request of the family. Although having a karyotype examination was discussed with the family, they refused to have the analysis conducted. Pathological examination of the fetus after the therapeutic abortion confirmed the diagnosis and the malformations described by ultrasonographic examination (Fig. 63). The fetus showed asymmetric head and the pouch of the amniotic membranes near the skull and unilateral anophthalmia (Fig. 64). Unfortunately, because of the size of the heart, it was not possible to establish if there was an intracardiac malformation present.

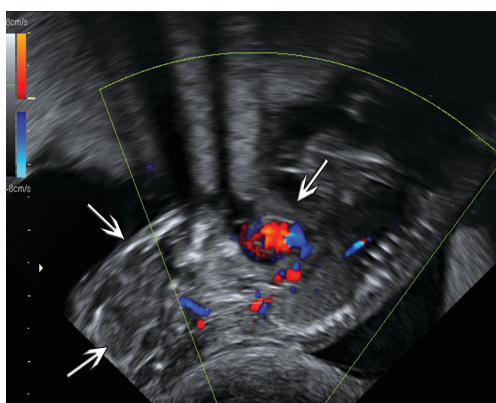


Fig. 61. Pregnancy 14 weeks of amenorrhea. Color Doppler ultrasound is helpful for the diagnosis of ectopia cordis.

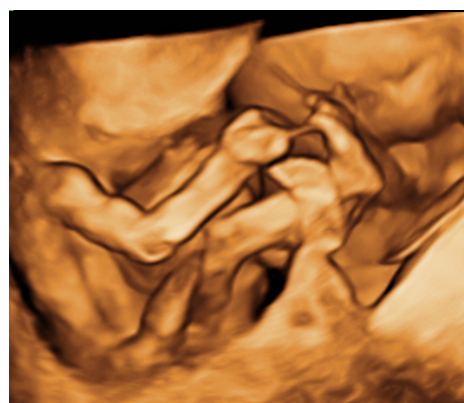


Fig. 62. Pregnancy 14 weeks of amenorrhea. Three-dimensional ultrasound- A large defect of the anterior abdominal wall is visible.

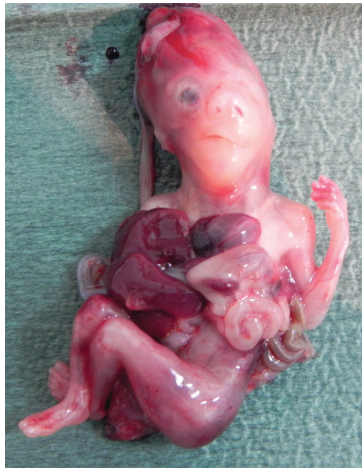

Fig.63. Macroscopic image of the fetus. Anophthalmia is visible.

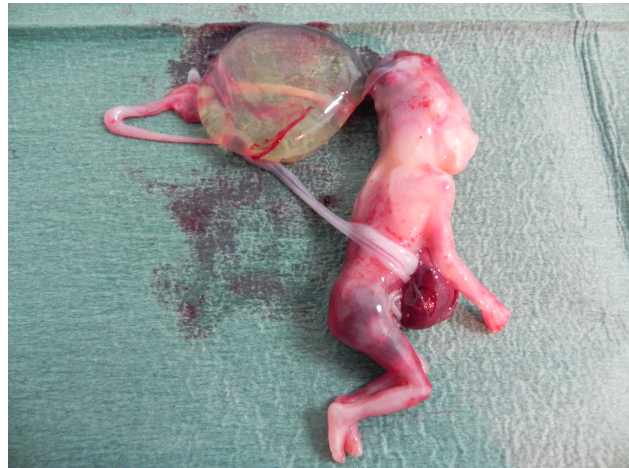

Fig. 64. Asymmetric head and the pouch of the amniotic membranes near the skull.

➤ *Early diagnosis of limb body wall complex: a case report*

We present one case with limb body wall complex followed by a review of the literature. The combination of two-dimensional and three-dimensional ultrasound proved to be useful for establishing the diagnosis and differentiating from other abdominal wall defects (Fig. 65, 66). The diagnosis was followed by therapeutic abortion at 14 weeks' gestation, and the pathological report confirmed the diagnosis (Fig. 67). In our case, the diagnosis was established at the end of the first trimester of pregnancy.

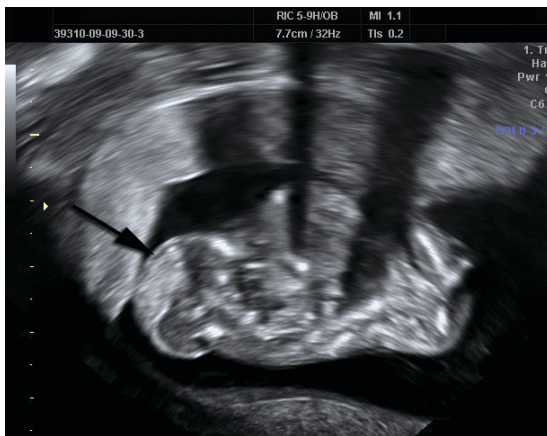


Fig. 65. 2D ultrasound of the fetus. Large defect of the abdominal anterior wall, the cephalic extremity is not well defined and has a bizarre shape, spine kyphosis is present.

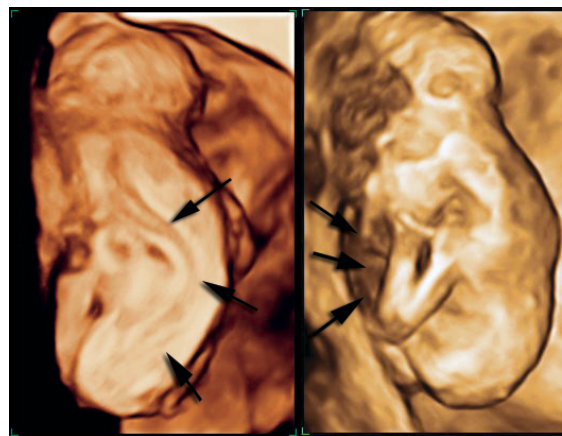


Fig. 66 3D ultrasound. Severe scoliosis of the spine. Large defect of the anterior abdominal wall.

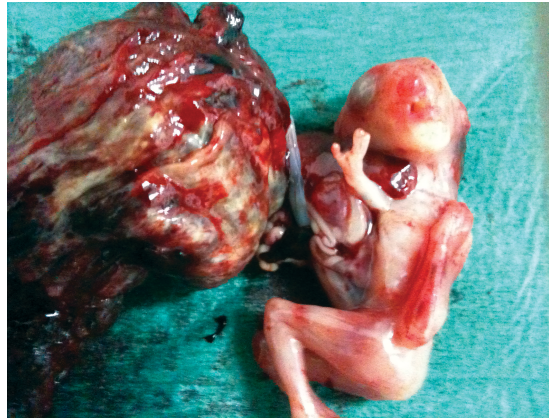


Fig.67. The fetus after abortion. Ventral view. Exencephaly, large abdominal defect, anomalous implantation of the right arm, missing forearm, oligodactyly, short umbilical cord.

I.4.2.4. Discussion

- *The role of 4D US in evaluation of fetal movements and facial expressions and their relationship with fetal neurobehaviour*

4D UD combines the benefit of 3D captures of the fetal face with time addition, and even more, supplies a tool for viewing the face area, giving the appearance and duration of every facial gesture to be settled and measured. The assessment of fetal behavior via 4D US can be achieved starting with the early period of gestation until the end of pregnancy. The technique includes a convex volumetric transducer for automatic scan, commencing with unusual fetal evaluation through the 2D method and setting out which region of interest to be assessed. Later, the 4D mode and 3D live captures are reconditioned based on 2D images chosen through an obtained plan. Rapidly processed volumetric data offers the possibility of estimating over 40 volumes in a second, providing a real-time effect of fetal examination for the practitioner (Kurjak *et al.*, 2008).

For fetal movement visualization, the transducer must capture a sagittal plan of the fetus, which contains the fetal head, thorax and abdomen, automatically obtaining a 3D volume. When the surface mode is rendered, it is possible to visualize and videotape 4D captures. For facial expression visualization, it is right to place the transducer to obtain a sagittal view of the fetus' face, which includes forehead, nose and chin. It depends of which area of references is to be pictured and analyzed: forehead and eyebrow area, eyelids and eyes, naso-labial fold and flexible nasal tissue, tongue and oral cavity, chin and lower lip, mouth and its angles or facial gestures (Guimarães Filho, 2013). Using 4D US, movements like sucking, swallowing and hiccups can be observed starting with the 9th week. At the beginning of the late stage of the first trimester, around 10 weeks, additional complex movements become visible by ultrasonography, consisting in anterior and posterior flexion of the head and cephalic rotation, jaw opening, and yawning but also breathing-like movements.

4D US had demonstrated that this technique brings better comprehension in both motor and somatic fetal development. Moreover, it helps to assess the complexity of facial activities and expressions, opening a new stage in the understanding of the neurological status of the fetus (Amiel *et al.*, 2006, Stanojevic *et al.*, 2011).

Many studies had evaluated the impact on parents of 3D and 4D US for fetal assessment. It had been shown that these two techniques compared with 2D US have a positive outcome, leading to an increased emotional attachment to the fetus or a determination to pass over various problems associated with the pregnancy and creating a bonding between parents and the fetus while reducing anxiety (*Kurjak et al., 2012*).

4D US assessment shows a parallel between prenatal behavior pattern, represented by extremities movements and facial expressions, and postnatal pattern, assessed in the neonatal stage through the postnatal test, named Amiel-Tison Neurological Assessment at Term (ATNAT), to evaluate quantitative and qualitative variations of movements during intrauterine development and the neonatal stage. There had been no significant differences between them, but an unceasing behavior during prenatal and postnatal period was noticed even for isolated eye movements, mouth and eyelid opening, tongue extrusion, smiling, yawning and hand movements to the face (*Amiel-Tison et al., 2006*).

The observation of intrauterine behavioral quality may predict neurological disabilities. Various fetal face gestures and body part motions had been observed by 4D US in the last two trimesters of pregnancy, indicating fetal awareness manifestations. Also, a raised incidence of facial gestures, with increased speed, strength and range of the movements associated with a multiplex perception, suggests signs of fetal awareness, being an accurate signal for the quality of a fetus' behavioral and intrauterine neurological disorders (*Kurjak A. et al., 2008*). 4D US development brought new scientific perspectives, opening such new fields as fetal psychology and neurology. The outcomes of 4D US provides valuable information about normal and abnormal neurobehavior of the fetus, which enables more accurate evaluation of fetal neurobehavioral development, especially in the fetal brain and CNS tasks. 4D US aids to optimize parent guidance, offering them more clarity regarding a potentially grave fetal condition. KANET screening test was made by 4D US evaluation of fetuses with optimal neurologic findings and seriously brain-impaired fetuses by the analogy of fetal and neonatal findings (*Kurjak A. et al., 2008*).

This newly developing field may enhance knowledge of fetal neurobehavioral functions and may lead, in coming times, to the identification of novel human interrelation. Currently, extensive research is needed for maximum application of 4D US to fetal neurodevelopment and neurobehavior.

- ***The role of HDlive technology in improving the quality of obstetrical images***

In obstetrical ultrasound, HDlive could be used during all three trimesters of pregnancy. The images obtained with HDlive in the first trimester of pregnancy are very impressive for both parents and their relatives. The images closely resemble those from anatomy atlases or scientific documentaries. The introduction of 3D/4D sonography in the first trimester of pregnancy has resulted in remarkable progress in sonographic visualization of early embryos and fetuses and in the development of the 3D sonoembryology (*Bonilla-Musoles et al., 2013*). HDlive assesses both structural and functional developments in the first trimester of pregnancy with greater reliability than 2D ultrasound. The ability to visualize fetal hands, fingers, feet, and toes is better with volumetric ultrasound than 2D ultrasound. The software enables visualization of the same picture with different light and shadows. HDlive and 3D ultrasound are important tools in the diagnosis of some fetal anomalies. Hata et al. proved the

superiority of 3D ultrasound compared to 2D ultrasound in the assessment of the surface of anatomical structures (face, hand, and foot). They concluded that 3D ultrasound was a promising technique in assessing and detecting abnormalities in embryonic and early fetal development during the first trimester of gestation (*Hata et al., 2015*). HDlive will likely have its own contribution to the development of this field.

Some limitations of HDlive include the reduced image quality that can occur with embryonic or maternal movement and surface rendering of the embryo depends on the presence of enough amniotic fluid around the embryo. Another limitation is the distance of the embryo from the uterine wall and the curvature of the gestational sac.

Visualization of the fetal face has become one of the main applications of 3D ultrasound scanning. Sometimes, the fetal position or the conditions of the exploration prevent appropriate slices being obtained in the 2D examination. In these cases, with appropriate rotations and translations, it is possible to move through the 3D volume until the target plane is obtained. Both 3D and the realistic pictures of HDlive are important tools in evaluating the facial anatomy of the fetus. HDlive and 3D ultrasound permit to obtain a true midsagittal plane of the face. HDlive not only provides information about face anomalies, but also provides more appropriate image of the normal face, very important information in cases with increased risk of recurrent surface malformations. Beyond the beauty of the HDlive images, this technique will probably provide much more information to assess the fetal face.

HDLive is useful not only in face examination, but also in examining the surface details. A clear picture of the hands, feet, abdomen, spine, and fetal genital organs can be obtained as outlined in our article.

2D and 4D US are complementary methods used for the evaluation of fetal movements. The introduction of 4D ultrasound into clinical practice allows better viewing of facial expressions, such as mouth opening, tongue protrusion, yawning, smiling, and eye opening and blinking, to be studied in great detail. The recent development of the advanced technique of 4D sonography and HDlive open a new perspective for research into fetal behavior and, particularly, facial movements.

Visualization of the fetus by the mother may arouse emotions capable of triggering or improving maternal-fetal bonding, and that may lead to changes in behavior and lifestyle that promote maternal and fetal health. Because of the natural appearance of the image with HDlive, the movements of the fetus could have a great impact on the parents. Several studies suggest that patients who are undergoing volume sonography and viewing the 3D and 4D images report enhanced bonding with their fetuses and more positive feelings about the experience than do patients having 2D sonography. According to Steiner, patients more easily recognize 3D images of the fetus than 2D images, and they feel more attached to the fetus after having 3D ultrasound (*Steiner et al., 1994*). Rustico published a study in which the addition of 4D sonography did not significantly change the perception women had of their fetuses compared to 2D ultrasound (*Rustico et al., 2005*). Preliminary analyses of a current study that we are performing in our center show that the role of HDlive should not be neglected. We intend to publish the results of this study in the near future. HDlive images can contribute not only to fetal-maternal bonding, but also to physician-patient bonding with the aid of life-like images. We believe that the impressive images obtained with HDlive offer us the occasion to feel closer to our patients, and we can establish a friendlier professional environment that is useful during the monitoring of the pregnancy.

HDlive was developed especially for obstetric usage because it provides a natural and realistic appearance of the fetus, but its use in gynecology should not be neglected because 3D ultrasound allows unique ways for assessing uterine and adnexal pathology. The main advantage of 3D ultrasound in uterus scanning is the possibility of displacing the coronal plane of the uterus. This plane is particularly important for diagnosing uterine congenital anomalies. Also, 3D ultrasound is the ideal imaging modality for examining ovarian morphology. Improved delineation of the ovarian lesions provides a more reliable diagnosis. The introduction of 3D Doppler differentiates between high- and low-risk lesions with far greater diagnostic confidence. In ovarian pathology, HDlive could be useful for clearly viewing the papillary projections within the tumor and the extent of these projections. HDlive enables a complete inspection of the inner surface of the tumor and a clearer evaluation of the papillae and the septum in cases of complex tumoral masses.

- ***Rare clinical conditions***

- *Using HDlive technology to diagnose Turner syndrome in the first trimester of pregnancy: clinical cases presentation and literature review*

In this paper, we present two cases of TS diagnosed during the first trimester of pregnancy, and we discuss the possibility of this early diagnosis and management. TS, a genetic disorder with an exclusively feminine phenotype, is caused by complete or partial X monosomy in some or all cells. The condition is characterized in adults by low stature and gonadal streaks in more than 90% of cases. Although diagnosis is made usually after puberty, there is now the possibility to detect the syndrome prenatally. These two cases confirm that diagnosis of Turner syndrome is possible during the first trimester of pregnancy using sonography as a screening method to select the suspected cases and using invasive prenatal techniques for confirmation.

The results of our study were thereafter reinforced in the literature. Wiechec et al evaluated the possibility of identifying TS in the first trimester of pregnancy on a prospective study. They studied a population of 5644 pregnancies: 5613 with a normal karyotype and 31 cases of TS. They found statistically significant differences ($p < 0.05$) between euploidy and TS groups in terms of nuchal translucency (NT; 1.7 mm versus 8.8 mm) and fetal heart rate (160 versus 171 beats per minute). Fetal hydrops was observed in 14 cases of TS (43.8%) and in 5 of euploidy (0.1%). Increased nuchal translucency and abnormal ductus venosus velocimetry flow (aDV or revDV) were the most common markers found in combination in TS cases ($n = 17$; 54.8%). In backward regression model, nuchal translucency > 3.5 mm and right dominant heart augmented the risk of Turner syndrome risk by 991 and 314 times, respectively. According to these authors when the first-trimester pattern of TS is considered, a highly thickened nuchal translucence, fetal heart rate above the 95th percentile, abnormal ductus venosus velocimetry and fetal hydrops should be specifically searched for. According to these authors first-trimester sonography is a feasible method to identify the most characteristic features of Turner syndrome (Wiechec et al., 2018).

➤ *Diagnosis of sacrococcygeal teratoma using two and three-dimensional ultrasonography: two cases reported and a literature review*

Although a rare condition, the diagnosis of fetal tumors should be established as early as possible for a proper management. Half of all fetal tumors are sacrococcygeal teratomas, and the reported incidence ranges from 1 in 27,000 to 1 in 40,000 live births (Swamy, Embleton & Hale, 2008). Prenatal diagnosis of this condition is important for monitoring of the affected fetuses and for establishing the mode and time of delivery. Before the routine use of ultrasonography in obstetrics, most fetuses with SCT were diagnosed at delivery. Advances in ultrasound have enabled accurate prenatal diagnosis of SCT, and in some cases, diagnosis can be made during the first trimester of pregnancy (Batukan, Ozgun, Basbug, 2001). In our paper we presented these two fetal sacrococcygeal teratomas diagnosed using two- and three-dimensional ultrasound. Ultrasound was useful not only for diagnosis, but also for monitoring the evolution of the tumor, detecting complications, and establishing the management. 3D UD can be beneficial for monitoring the evolution of the tumor and for conveying to the parents a better understanding of this anomaly. The combination of 2D and 3D US enable the diagnosis to be made during the first trimester of pregnancy.

Along with the diagnosis it is important to predict neonatal survival in sacrococcygeal teratoma. In sacrococcygeal teratoma, the presence of high-output cardiac failure resulting from arteriovenous shunting through the large tumor has been associated with an adverse outcome. Lee et al analyzed the relationship between tumor size and cardiac biomarkers in cord blood and the survival in sacrococcygeal teratoma on 25 neonates with sacrococcygeal teratoma. They concluded that a tumor volume index of greater than 60 cm³/cm, elevated NT-pro-BNP (>2000 pg/mL), and elevated cTnT (>0.08 ng/mL) had sensitivity of 100% for prediction of neonatal death (Lee et al., 2018).

➤ *Pentalogy of Cantrell associated with unilateral anophthalmia: Case report and literature review*

3D ultrasound is particular useful in cases with rare malformations and in this article we describe a case of a rare congenital condition- pentalogy of Cantrell diagnosed during early pregnancy. Pentalogy of Cantrell has an estimated incidence of 5.5 per 1 million live births (Carmi, Boughman, 1992). It includes five defects: a midline supraumbilical wall defect, a diaphragmatic defect, a cleft distal sternum, a defect in the diaphragmatic pericardium, and an intracardiac defect. Very few cases of this condition have been reported in the literature, most of them diagnosed in the second or third trimester of pregnancy. In this article we presented a case of pentalogy of Cantrell associated with cranioschisis and unilateral anophthalmia diagnosed at 14 weeks of amenorrhea with 2D and 3D ultrasound. To the best of our knowledge, the presence of unilateral anophthalmia in Cantrells' pentalogy has not been reported yet.

The pentalogy of Cantrell can be diagnosed with ultrasound, which reveals the association between an omphalocele and an ectopic heart. Color Doppler examination, which visualizes the heart outside the thorax, is very useful especially for making the differential diagnosis with other plurimalformative syndromes like limb body wall complex body syndrome. Pleural and pericardial effusion are common, and some authors consider them to be indirect markers for the pentalogy. Additionally, 3D ultrasound can be useful to confirm the diagnosis providing a

complete prenatal view of the anomaly (Rodgers *et al.*, 2010). Because of the poor prognosis of Cantrell's pentalogy, early antenatal sonographic detection is important and allows for elective abortion before viability.

In pregnancies diagnosed with the pentalogy of Cantrell parents should receive counseling relative to mortality and morbidity risks. Recently, in a case of monochorionic twin pregnancy complicated by pentalogy of Cantrell, ultrasound guided bipolar coagulation of the cord allowed for selective termination of the affected fetus with preservation of the remaining fetus (Abehsera *et al.*, 2016). Advances in fetal surgery will modify the therapeutic options available for patients with pentalogy of Cantrell. Engels *et al* performed in utero pericardio-amniotic shunting for a large pericardial effusion for a fetus with this disease. The therapeutic draining of the effusion allowed for a suspected improvement in lung growth and development prior to delivery (Engels *et al.*, 2017). However, aggressive prenatal interventions must be balanced with associated risks as well as informed post-natal expectations for prognosis (Williams, Marayati & Beierle, 2019). A recent study by Antiel *et al* suggested that parent counseling can often be influenced by the physician's demographic characteristics or personal beliefs and there are differences among pediatric surgeons, neonatologists and maternal- fetal-medicine specialists (Antiel *et al.*, 2018).

➤ *Early diagnosis of limb body wall complex: a case report*

Limb body wall complex (LBWC) is a rare polymalformative syndrome. Diagnosis is based on the presence of at least two of three essential features: exencephaly/encephalocele and facial clefts, thoraco-and/or abdominoschisis and limb defects (Van Allen, Curry & Gallagher, 1987). A constant finding is coelosomia, which can be variably associated with encephalic, vertebral, visceral or limb anomalies. The anomaly has also been referred to in the literature as short umbilical cord syndrome or body stalk anomaly. The majority of cases presented in the literature have been diagnosed in the second or third trimester of pregnancy. Although the syndrome can also be diagnosed in the first trimester of pregnancy, very few cases of diagnosis in early gestation have been reported in the literature (Paul *et al.*, 2001; Murphy, Platt, 2011).

Russo *et al* identified two distinct LBWC phenotypes: placento-cranial and placento-abdominal types (Russo *et al.*, 1993). The placento-cranial type is characterized by craniofacial defects, facial clefts, and amniotic adhesions. The placento-abdominal type has no cranial defects, rather, more frequently has been associated with coelosomia lumbosacral meningomyelocele and kyphoscoliosis, as well as urogenital anomalies. Our case has the characteristic for the former type of LBWC. Usually, LBWC is diagnosed during the second trimester of pregnancy by ultrasound. Although the syndrome can also be diagnosed in the first trimester of pregnancy, very few cases of diagnosis in early gestation have been reported. In any case, the diagnosis cannot be formulated before 10 weeks' gestation because of the physiological herniation characteristic of this period. In our case, the diagnosis was established at the end of the first trimester of pregnancy. The presentation of this case clearly showed the importance and the benefit of a correct prenatal diagnosis. Because the ultrasound examination was correctly performed, this condition was diagnosed early and a therapeutic abortion was performed. The prognosis for LBWC is very poor, and because it is considered incompatible with life, pregnancy should be

terminated after a correct sonographic diagnosis. It is also important to explain to the families affected that there is no recurrence risk in this anomaly. Our case demonstrated the importance of performing a thorough morphologic survey at the time of nuchal translucency screening and the value of 3D sonography in the delineation of first-trimester anomalies. Also, 3D ultrasound is a valuable tool for counseling parents to provide a better understanding of the problems that could appear.

A special situation in clinical practice is the appearance of LBWC in twins. There are few documented cases reported on dizygotic twins discordant for this anomaly, but the rarest cases described in the literature are those identified in monozygotic twins. There are several case reports of LBWC associated with diamniotic fetuses in triplet pregnancy. In cases of twin gestation even if diagnosed early the management are more challenging because the unaffected fetus usually survives with no major complications, being however, at increased risk for a preterm delivery. A selective feticide of the affected fetus late in pregnancy, in accordance with parents' decision focused on the neonatal well-being of the unaffected twin can be performed (*Caldas et al., 2018*).

I.4.3. 3D ULTRASONOGRAPHY AND NOVEL TECHNOLOGIES IN UTERINE AND OVARIAN PATHOLOGY

I.4.3.1. Background

Imaging techniques have developed remarkably during recent years. The use of 3D UD provided new possibilities for diagnosing gynecological disease. In comparison to 2D US, 3D US better reveals the normal anatomy, and affords a more precise depiction of abnormal anatomy, as the coronal plane of the uterus can be easily obtained using reconstruction techniques. Moreover, it offers obvious advantages: reproducible image acquisition, enhanced visualization and post-processing capabilities.

In recent years, 3D US has proved to be a very powerful tool for diagnosing uterine anomalies. The coronal plane obtained clearly outlines the external contour of the uterus, and provides accurate information about the shape of the cavity. The sensitivity, specificity, positive and negative predictive values of 3D US in the detection of a septate uterus is 98.4%, 100.0%, 100.0% and 96.0%, respectively (*Kupesic, Kurjak, 2000*). On coronal plane we can measure the distance between the two internal tubal ostia, the length of a septum, the remaining cavity length, and the depth of an external fundal indentation (*Woelfer et al., 2001*). Quantification of these parameters provides a reproducible standard that can be used to compare studies from different institutions. It is useful for differentiation of septate from bicornuate uteri. Even so, some difficulties could appear in diagnosis of a septate uterus with an external indentation. In this case the differential diagnosis with a bicornuate uterus could be difficult. On the coronal plane obtained with 3D it is easy to measure the length of indentation; if it is less than 1 cm the diagnosis is bicornuate uterus and if it is larger than 1 cm the diagnosis is bicornuate uterus. Also it is stated that an angle of less than 75° between the uterine horns is suggestive of a septate uterus, and

an angle of more than 105° is more consistent with bicornuate uteri. The coronal 3 D plane permits a very precise measurement of this angle. 3D US has been reported to allow differentiation of a septate from a bicornuate uterus if a true orthogonal view along the long axis can be obtained. The septate uterus is defined by a fundal indentation of more than 5 mm above the interstitial line (*Homer, Li & Cooke, 2000*). Reconstruction of the coronal plane is also helpful in assessing gestational sac location within a bicornuate or septate uterus thus not mistaking a sac within a horn as a cornual pregnancy.

The correct position of an intrauterine device (IUD) is important for routine follow-up after insertion. The shaft of the copper IUDs are easy to visualize with 2D ultrasound because of the shadow produced by the copper filament. However, it may fail to show the side arms with 2D ultrasound. In hormone releasing IUD difficulties could occur because of the absence of the metallic component and in some cases because of the associated uterine pathology (uterine myome, adenomyosis). Coronal view of the uterus in 3D US can clearly show the entire IUD, its location in the cavity, and its relationship with the myometrium.

Leiomyomas, the most common benign tumor in women, are relatively easily diagnosed by 2D US. Difficulties can appear when it is necessary to differentiate a submucosal leiomyoma from an intramural one, or to establish its relationship with the endometrial cavity. The borders and exact location of multiple leiomyomas can be difficult with 2D US and all this data are important in patients with fertility problems, recurrent pregnancy failures, and abnormal uterine bleeding when making clinical decisions

3D US ensures a more precise calculation than 2DUS of the ovarian volume, stromal volume and follicle volume. In addition, 3D US ensures an exact count of the ovarian follicles. By using the inverted contrast and spindle rotation of the volume one accurately can count the number of the ovarian follicles. This precise count is important for the assisted reproduction techniques methods, because it is envisaged the response to the ovarian stimulation treatment (*Kyei-Mensah et al., 1996*). With the aid of the sonoAVC software (automated volume count) one can determine exactly the number of the ovarian follicles (*Ehrmann et al., 2006*).

The 3D US of the adnexa can be useful in ovarian tumors by observing the inner surface and content of the cystic tumors. HDlive software has been used in order to better view the content of the cyst. 3D US or HDlive views could clearly establish the presence of the loculation inside of the cyst. They are also useful tools for counting the loculi inside of the cyst. This counting is recommended because it was shown that the number of the loculi and the maximum diameter of the tumor might be alternate indicators for differentiating malignant from benign mucinous cystic neoplasms (*Okamoto et al., 2007*). Ovarian endometriomas are characterized by fine hyperechogenic areas uniformly distributed in their interiors, characteristic in 82%-95% of cases (*Moore et al., 2002*). Endometrioma often have thickened walls, and in 10%-20% of the cases, nodosities could be present. These nodosities could lead to confusion with the intracystic vegetations, which appear in borderline ovarian tumors or ovarian adenocarcinoma (*Van Holsbeke et al., 2010*). Doppler examination is useful in these cases showing the lack of blood flow in the interior of the pseudo-vegetations of the endometriom (*Alcazar, 2001*). With 3D and niche mode it is possible to navigate throughout the tumor.

Tomographic ultrasound imaging (TUI) allows the analysis of serial sections of a certain anatomical segment using echography. The distance between the sections can be modified and is usually dependent on the area of interest. Using TUI, the

examiner can establish with a higher degree of accuracy the extent of the lesions and also the adjacent organ damage. TUI is extremely useful in the analysis of large endometrioma and of the adnexal complex masses because it allows the evaluation of the whole organ in only one image. It can also identify the normal, functional ovarian tissue in the large endometrioma.

The polycystic ovary syndrome is a heterogeneous condition whose definition has undergone changes over the years. The diagnostic criteria as defined by the 2003 Rotterdam consensus give to ultrasound examination a well-defined function. The ultrasound criteria required for the diagnosis are as following: the presence of at least 12 ovarian follicles of 2-9 mm or an ovarian volume of at least 10 cm³. Due to the criteria defined by the Rotterdam consensus, 2D US is enough to establish the diagnosis of polycystic ovaries. Meanwhile, 3D US ensures an exact count of the ovarian follicles. By using the inverted contrast and spindle rotation of the volume one accurately can count the number of the ovarian follicles. This precise count is important for the assisted reproduction techniques methods, because it is envisaged the response to the ovarian stimulation treatment (*Deb et al., 2010*). With the aid of the sonoAVC software (automated volume count) one can determine exactly the number of the ovarian follicles (*Raine-Feninning et al., 2008*). In 2D US, the vascularization assessment is made either qualitatively with power Doppler or color power or quantitatively by measuring the resistance indices through pulsed wave Doppler. Both methods are limitative because they appreciate only partially the vascularization of the studied organ. The use of VOCAL software in 3D ultrasound ensures the vascularization assessment throughout the studied volume and gives us an objective image over the entire vascular system, and not only for a studied blood vessel. 3D US is a desideratum for the clinical trials and the research. In the future it is possible to assist to a reshaping of the 3D US in the diagnosis routine of polycystic ovaries. Due to its high specificity and reproducibility it is possible to assist in the future to new and refined ultrasound criteria and a distinct position for three-dimensional ultrasound in the diagnosis of PCOS.

Imaging techniques play an important role in the diagnosis of adenomyosis, the main diagnostic techniques being ultrasonography and MRI. A meta-analysis showed that transvaginal 2D US and MRI has high levels of accuracy for the noninvasive diagnosis of adenomyosis (*Champaneria et al., 2010*). Adenomyosis is not a uniform disease. Rather, it represents a spectrum of lesions, ranging from increased thickness of the endometrial-myometrial junction to overt adenomyosis and adenomyomas. 3D ultrasound enables visualization of the coronal plane of the uterus and consequently gives a clear image of the endometrial-myometrial junction. The endometrial-myometrial junction appears on the coronal plane as a hypoechoic zone around the endometrium (*Exacoustos et al., 2011*). Also, it is believed that the features revealed by 3D US define the stage of the disease. It has been reported that changes in the thickness of the junctional zone and protrusion of the endometrium into the inner myometrium represent an early stage in the development of adenomyosis (*Naftalin, Jurkovic, 2009; Exacoustos C, 2011*). Conventional findings such as myometrial cysts and asymmetry of the myometrium are more likely to be signs of advanced disease. To diagnose adenomyosis, 3D US is useful because it enables the examination of the coronal plane of the uterus and the endometrial-myometrial junction (EMJ) changes (*Naftalin, Jurkovic, 2009*). Using the volume contrast imaging during 3D examination generates a more accurate picture of this interface. Because of the clear view with volume contrast imaging 3D ultrasound represents the indicated modality of analyzing and measurement of the endometrial-

myometrial junction (*Exacoustos et al., 2011*). Because of the possibility of visualizing the EMJ, 3D US opens up new horizons for the diagnosis of adenomyosis. The combined information gained from the 2D and 3D US examinations not only allows diagnosis of adenomyosis but also pinpoints the stage of the disease. Once clear criteria have been established for such staging, we can set up proper protocols for managing the disease.

The introduction of harmonic imaging, as well as the implementation of new graphic software for the reduction of artifacts, such as speckle reduction imaging and crossbeam resolution imaging, have allowed more precise diagnosis in pelvic peritoneal endometriosis cases. Speckle reduction-imaging increases the visibility of organs and lesions through improved contrast resolution and border detection while reducing the artifact characteristics of ultrasound. Crossbeam resolution imaging enhances tissue and border differentiation with an exclusive spatial compounding acquisition and processing technique. A much clearer distinction of the interface between cyst and ovarian tissue is visible when using these softwares (*Qiu et al., 2012*). Detecting these modifications could be useful in identifying patients that have a risk of developing endometriosis.

The new imaging technologies developed in recent years have significantly improved the diagnosis of both uterine and ovarian pathology. Within the direction of researches on 3D US in uterine and ovarian pathology, I have published 4 article ISI indexed journal.

Published papers

1. **Grigore M**, Grigore A, Gafitanu D, Furnica C. Pictorial essay of ultrasound-reconstructed coronal plane images of the uterus in different uterine pathologies. *Clin Anatomy* 2018; 3:373-379. **IF 1,5**
 ➤ Awarded in the UEFISCDI competition “Premierea Rezultatelor 2018” PN-III-P1-1.1-PRECISI-2018-26007
2. **Grigore M**. HDlive pictures of a serous ovarian borderline tumor, *Ultrasound Obstet Gynecol* 2013; 4: 598-599. **IF 3,32**
3. **Grigore M**, Popovici R, Furnica C, Pristavu A, Hamod A, Gafitanu D. Three-dimensional ultrasound and HDlive in tubal serous cystadenofibroma: a case report and literature review. *Med Ultraon* 2017; 19:444-446. **IF 0,8**
4. **Grigore M**, Pristavu A, Gafitanu D. Ultrasound features of osseous metaplasia of the endometrium- Case series and review of the literature. *Clin Imaging* 2018; 52:260-263. **IF 1,13**

I.4.3.2. Material and methods

- ***Pictorial essay of ultrasound-reconstructed coronal plane images of the uterus in different uterine pathologies***

Herein, we provide a pictorial essay focused on the gynecologic clinical applications of coronal plane images of the uterus obtained via 3D ultrasound. 3D US was performed with Voluson 730 Pro (General Electric, Zipf, Austria) and a Voluson E8 (General Electric, Zipf, Austria) with a volumetric transvaginal transducers. We analyzed several uterine condition and we underlined the benefits of adding 3D US with coronal plane to obtain a more precise diagnosis.

- ***HDlive pictures of a serous ovarian borderline tumor***

We present the case of a serous borderline tumor at a patient of 25 year-old. The preoperative ultrasound reveals a unilateral ovarian tumor of 5.5 cm with papillae inside of the tumor.

- ***Rare clinical conditions***

- *Ultrasound features of osseous metaplasia of the endometrium- case series and review of the literature*

Osseous metaplasia of the endometrium is a rare disorder associated with the presence of bone in the uterine endometrium. Although rare, it is important that physicians and sonographers are familiar with this pathology, which has a quite characteristic, even pathognomonic ultrasound pattern. We present a case series of four women with osseous metaplasia of the endometrium and provide a review of the literature.

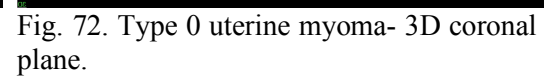
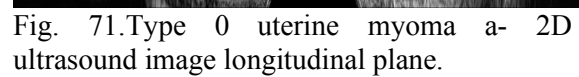
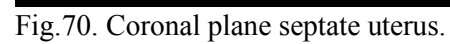
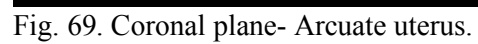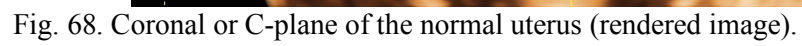
- *Three-dimensional ultrasound and HDlive in tubal serous cystadenofibroma: a case report and literature review*

Cystadenofibromas of the fallopian tubes are rare benign and very few cases have been reported in the literature worldwide. Usually, the tumor is asymptomatic, and for almost all cases reported, the tumors were incidentally discovered during surgery for other genital pathology. We report the case of a 30-year-old woman with a serous cystadenofibroma of the fallopian tube, presenting with chronic abdominal pain and secondary infertility.

I.4.3.3. Results

- ***Pictorial essay of ultrasound-reconstructed coronal plane images of the uterus in different uterine pathologies***

We analyzed several uterine condition and we underlined the benefits of adding 3D with coronal plane to obtain a more precise diagnosis. The uterine conditions analyzed with both 2D and 3D ultrasonography were: uterine congenital anomalies (Fig. 68-70), submucosal fibroids (Fig.72,72), IUDs (Fig. 73,74), Caesarean scar defects (Fig.75,76).



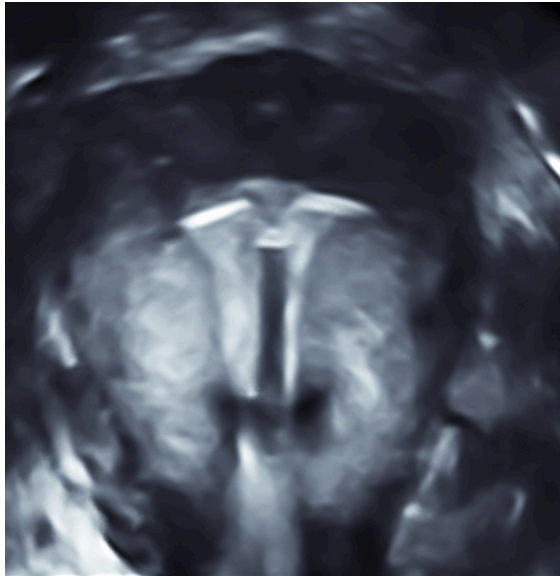


Fig. 93. Coronal plane- T-shaped intrauterine device (IUD) in the correct intrauterine position.

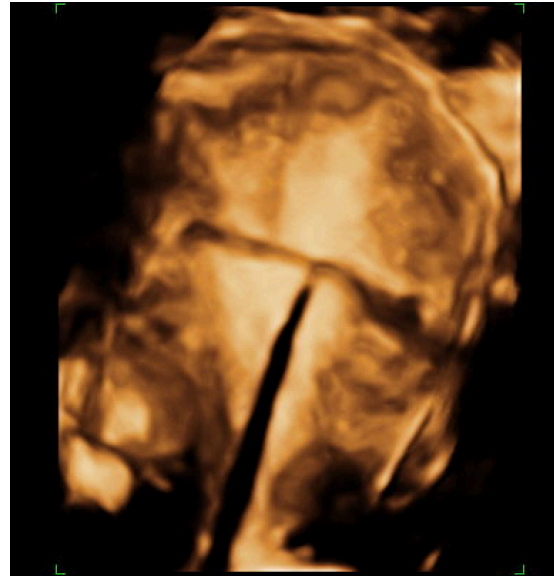


Fig. 94. Coronal plane- A descended IUD.

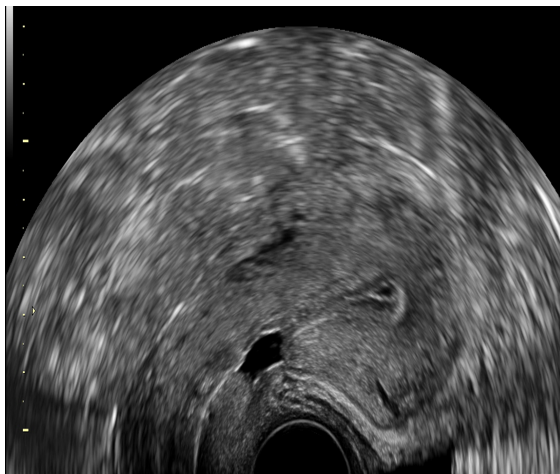


Fig. 75 Cesarean scar defect- longitudinal plane.

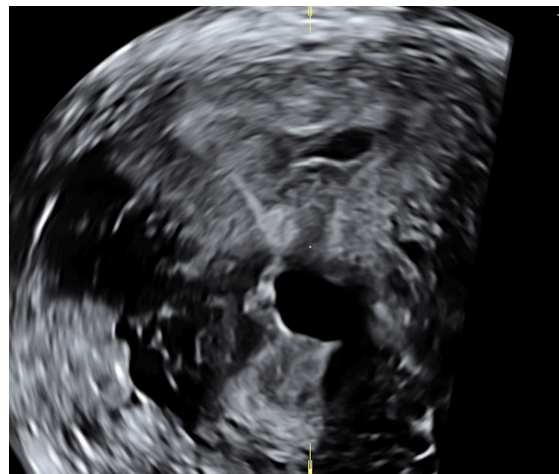

Fig. 76. Cesarean scar defect- coronal plane- white arrows show the surface of the defect in coronal plane.

- ***HD live pictures of a serous ovarian borderline tumor***

In this paper I present the case of a serous borderline tumor in a 25-year-old patient. I examined the tumor using 2D sonography (Figure 77) and 3D HD*live* (Fig. 78). Using 2D sonography we observe a unilateral ovarian tumor of 5.5 cm with papillae inside. HD*live* provided a better view of the papillary vegetation and the extent of the vegetation inside of the tumor. We observed that the HD*live* image was similar to the macroscopic image of the specimen (Fig. 79-80).

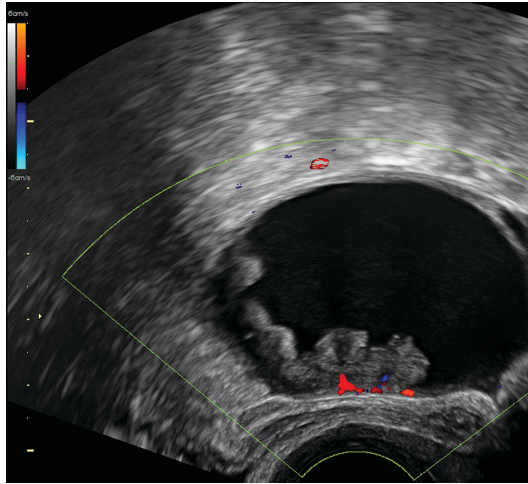


Fig. 77 Two-dimensional ultrasound images of a serous borderline ovarian tumor.

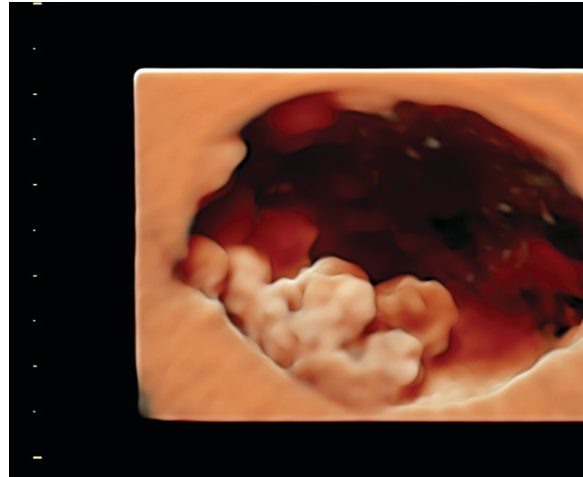


Fig. 78 HDlive- The papillae within the tumor are particularly clearly seen using HDlive.

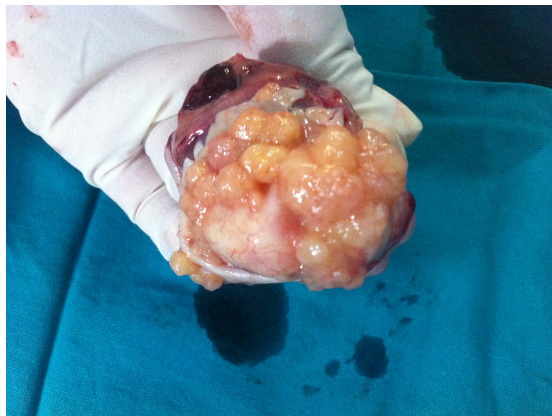

Fig. 79. Macroscopic appearance of the excised serous borderline ovarian tumor. The papillae within the tumor are particularly clearly seen.

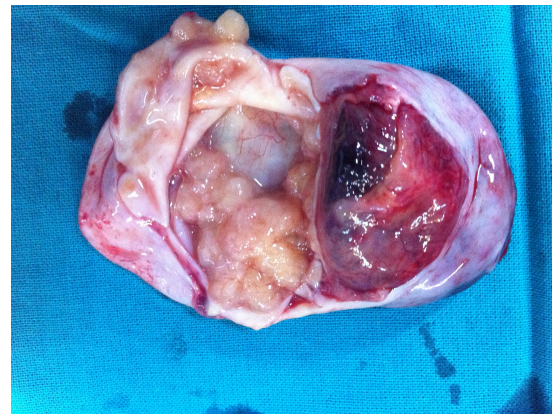


Fig. 80. Macroscopic appearance of the excised serous borderline ovarian tumor.

- ***Rare clinical conditions***

- *Ultrasound features of osseous metaplasia of the endometrium- case series and review of the literature*

Case 1

A 35-year-old woman (P1G2) with a history of secondary infertility presented for gynecologic examination. Her obstetric history included one term pregnancy and two spontaneous abortions in the late first trimester. Her menstrual cycles were regular and the genital clinical exam was normal. She had a history of contraceptive intrauterine device (IUD) placement, which had been removed; no known indwelling device was present. Two-dimensional (2D) endovaginal examination revealed a linear hyperechoic structure with posterior acoustic shadowing in the uterine cavity (19 x 2.1 x 8.5 mm), which led to the suspicion of an intrauterine device (Fig. 81). Visualization of the coronal plane of the uterus with three-dimensional (3D) ultrasound was very useful for the differential diagnosis showing the irregular shape of the hyperechoic area, and the diagnosis of osseous metaplasia was formulated (Fig.

82). Hysteroscopy confirmed the diagnosis. She conceived spontaneously 6 months later.

Case 2

A 30-year-old woman (P0G1) with a history of secondary infertility (lasting 2 years) presented to a gynecologic consult. She had a previous abortion via sharp curettage in the first trimester of pregnancy. Her menstrual cycles were regular and she did not have any previous workup for infertility. 2D endovaginal ultrasound revealed multiple bright images within the endometrium with some posterior acoustic shadowing in the uterine cavity. A hysteroscopy confirmed the diagnosis of osseous metaplasia and the fragments were extracted with graspers. The patient conceived spontaneously 4 months later; however, she experienced a missed abortion.

Case 3

A 34-year-old woman (P3G4) presented to a gynecological examination because of menorrhagia. She had a history of three full-term vaginal deliveries and a miscarriage, subsequent to which she underwent dilatation and curettage at 13 weeks gestation (four years prior to the current presentation). Her menstrual history was normal before the event. Her general examination, bimanual exploration, and routine hematological parameters were normal. Transvaginal ultrasound revealed a hyperechogenic curvilinear structure centrally positioned at the isthmic region of the uterine cavity with posterior acoustic shadowing, suspicious for foreign body (Fig. 83). The patient underwent a diagnostic hysteroscopy, which showed a white meshwork of bony material in the isthmic region of the uterus, with a hard tactile consistency (Fig. 84). The mass was completely excised by hysteroscopy and a levonorgestrel IUD was placed for the management of her menorrhagia.

Case 4

A 34-year-old woman (P1G3) presented to a routine gynecologic examination. She had a history of one live birth followed by two miscarriages. Her menstrual cycles were regular and she had no complaints. Transvaginal ultrasound revealed an intrauterine hyperechoic structure with posterior acoustic shadowing, suggestive of a foreign body. Hysteroscopy confirmed a diagnosis of osseous metaplasia; the bone fragment was removed (Fig. 85,86).

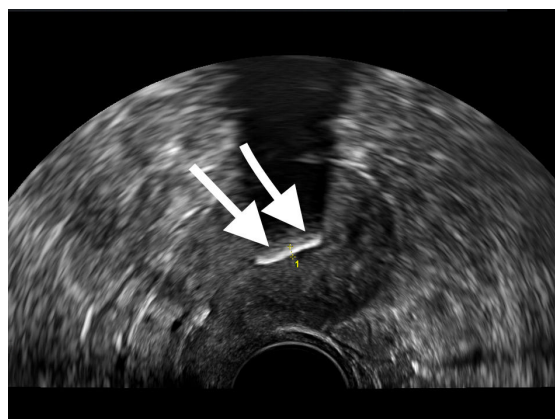

Fig.81. 2D endovaginal examination-longitudinal plane ultrasound- linear hyperechoic structure with posterior acoustic shadowing in the uterine cavity.

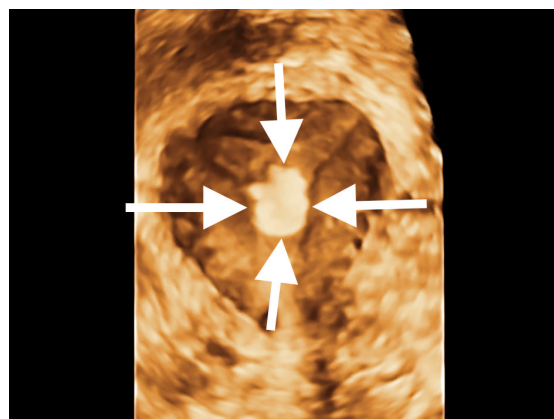


Fig.82. 3D ultrasound coronal plane-hyperechoic area with irregular shape in the uterine cavity.

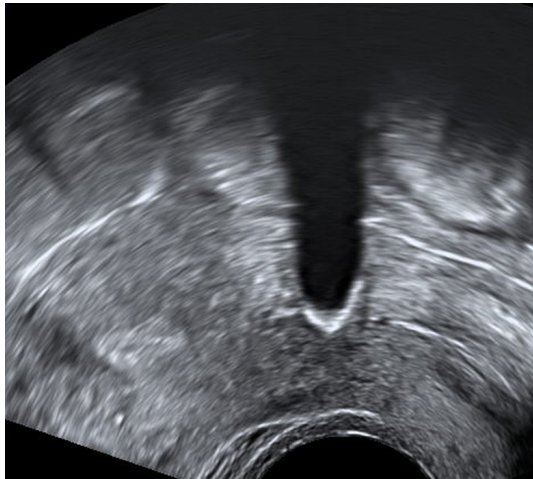

Fig 83. 3D ultrasound coronal plane- hyperechoic area with irregular shape in the isthmic region of the uterus.

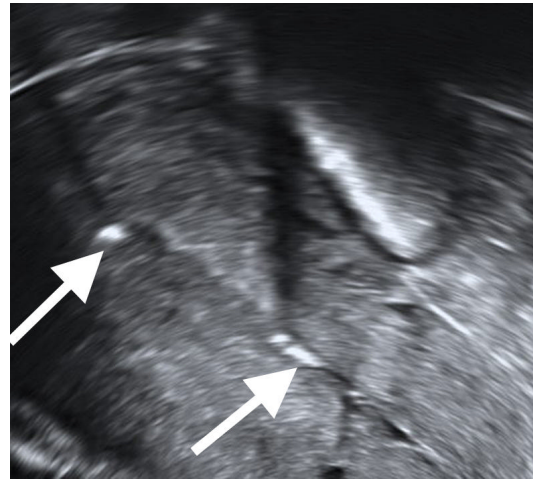


Fig. 84. 2D endovaginal examination- longitudinal plane ultrasound- multiple bright echo within the endometrium with some posterior acoustic shadowing in the uterine cavity.

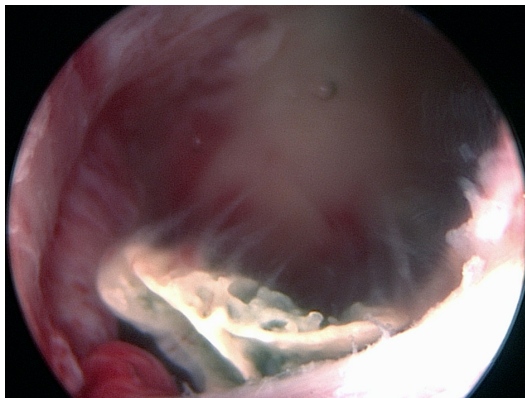


Fig. 85. Hysteroscopic image- bony fragments in the uterine cavity.



Fig. 86. Image of the extracted bony fragments from the uterine cavity.

➤ *Three-dimensional ultrasound and HDlive in tubal serous cystadenofibroma: a case report and literature review*

A 30-year-old woman, gravida 1, parous 1, presented for a gynecologic examination for chronic pelvic pain and secondary infertility. The endovaginal ultrasound revealed a septate uterus and a complex structure between the uterus and left ovary. That structure was 4 cm in diameter, had a regular wall and fine papillae on the internal surface. The two-dimensional (2D) Doppler examination showed no signal inside the papillae (Fig. 87a). The three-dimensional (3D) sonography with HDlive software (Voluson E8, 3D endovaginal probe 4-8 Hz, GE Healthcare) of the

tumor revealed a fine, regular aspect of the vegetation inside the tumor (Fig. 87b). The tumoral markers (CA 125, CA19-9) were in normal range. Because of the complex aspect and lack of connections between the ovary and the tumor, a fallopian tube tumor was suspected. Moreover, because of the 3D HDlive aspect and the normal value of the tumoral markers, we suspected a benign tumor (Fig. 87c). After discussing the management options with the patient, we performed a laparoscopic cystectomy. During the surgery, we confirmed the tubal tumor diagnosis and performed a cystectomy. The tumor was attached to the serosal surface of the tube (Fig. 88d). The histology results confirmed serous cystadenofibroma of the fallopian tube (Fig. 88e). The patient recovered uneventfully and was discharged three days postoperatively. Two months after the surgery, she became spontaneously pregnant. The pregnancy was in the left part of the uterus.

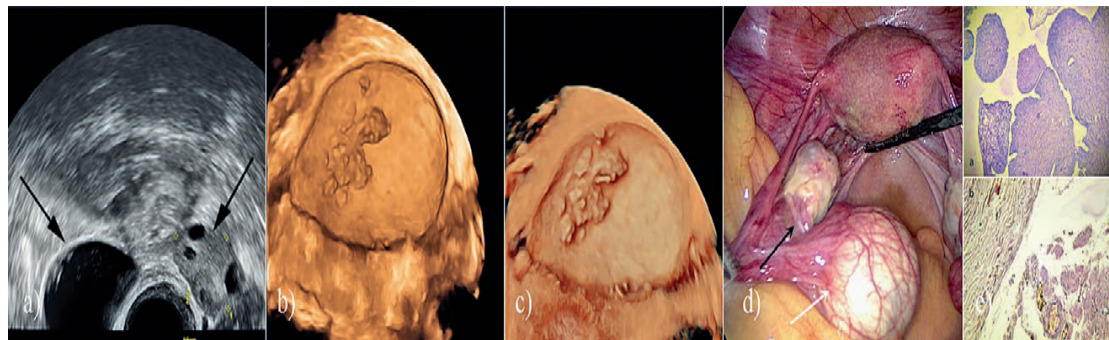


Fig. 87. Endovaginal 2Dultrasonography of the tumour (black arrow – ovary, white arrow – tumour with papillae inside);b) 3D ultrasound of the tumor – tumor pappilae are seen inside of the tumour; c) HDlive three-dimensional ultrasound of the tumor the pappilae are clearly seen; d) Laparoscopic image of the tumor (black arrow – left ovary, white arrow – fallopian tumour); d) histopathological examination – cystadenofibroma (up) and cyst wall and fallopian tube (down) (H&E staining).

I.4.3.4. Discussion

- *Pictorial essay of ultrasound-reconstructed coronal plane images of the uterus in different uterine pathologies*

In this article we provide a pictorial essay focused on the gynecologic clinical applications of coronal plane images of the uterus obtained via 3D ultrasound. This pictorial essay demonstrates that adding 3D US to a routine gynecologic workup can be beneficial for clinicians, enabling a precise diagnosis. In addition, the volumes obtained and stored by 3D US can allow students or residents to become more familiar with normal and abnormal pelvic structures.

Submucosal fibroids are a common cause of abnormal uterine bleeding, subfertility, and early pregnancy loss. Submucosal fibroids may be classified based on their protrusion into the endometrial cavity into three groups: type 0 (the myoma is entirely in the cavity), type I (<50% contained within the myometrium), and type II (>50% contained within the myometrium). It is sometimes difficult to differentiate a submucosal leiomyoma from an intramural leiomyoma, or to establish its relationship with the endometrial cavity, using 2D US. Furthermore, the correct mapping of multiple myomas can be difficult with 2D US. In contrast, 3D US can precisely

delineate the location of the leiomyomas, and depict their intramural and submucosal components. This information is very useful for clinical decision-making in women with fertility problems and recurrent pregnancy failures, when preservation of the uterus is very important. The visualization of the coronal plane enables a careful selection of good candidates for hysteroscopic resection, avoiding classic or laparoscopic surgery. 3D ultrasonography can precisely map the location of leiomyomas and depict their intramural and submucosal components (*Turkgeldi, Urman & Ata, 2015*).

Furthermore, 3D US allows the evaluation of both the IUD type and position inside the uterine cavity. In addition, 3D US has proven to be more sensitive than 2D US, revealing more subtle findings of malposition, particularly side-arm embedment, by showing the coronal plane of the uterus. Abnormally positioned IUDs may be associated with a higher incidence of failed contraception, pain, and bleeding.

Caesarean scar defects, also known as isthmoceles, are an emerging condition affecting women with a history of caesarean section. Their presence is a novel, under-recognized cause of postmenstrual abnormal uterine bleeding, pelvic pain, and infertility. On 2D US, a myometrial-thinning defect can be observed in the myometrium at the level of the previous cesarean section. In clinical practice, measuring the remaining myometrial thickness over the defect is important for assessing cesarean hysterotomy scars in non-pregnant women (*O'Rahilly, 1997*). When planning a hysteroscopic repair, imaging the coronal plane allows the measurement of the defect in all three dimensions, which provide useful information.

3D ultrasound is a very powerful tool in diagnosing uterine congenital anomalies (*Propst, Hill, 2000, Faivre et al., 2012*). Over time, it is possible that 3D US may become the gold standard in diagnosing uterine congenital anomalies, sidelining the use of MRI. Faivre reported that 3D US had higher concordance with laparoscopy than MRI (*Faivre et al., 2012*). 3D US has gained an important place not only in the diagnosis but also in the management of uterine anomalies. It can be used during hysteroscopic metroplasty for uterine septum in order to precisely appreciate how much septum is left in real time. This approach prevent either overzealous incisions either incomplete resection (*Ludwin et al., 2014*). All this studies underline that 3D US is a highly sensitive and specific tool for accurately diagnosing congenital uterine anomalies. It is non-invasive, fast, reproducible, readily available, and relatively cost-effective. Over time, it is strongly possible that 3D USG may become the gold standard in diagnosing uterine anomalies, sidelining MRI. Hysteroscopy and laparoscopy may then be used for therapeutic purposes only.

This pictorial essay demonstrates that adding 3D ultrasound to a routine gynecologic workup can be beneficial for clinicians, enabling a precise diagnosis. Furthermore, 3D ultrasound can replace several investigations that are invasive (hysteroscopy, laparoscopy), involve expose to radiation (hysterosalpingography), or are expensive MRI.

- ***HDlive pictures of a serous ovarian borderline tumor***

In this paper I analyzed the role of 3D US and HDlive in the diagnosis of the ovarian borderline tumors. Borderline ovarian tumors represent approximately 15-20% of ovarian epithelial neoplasms (*Acs, 2005*). In younger women, these tumors typically manifest as low-stage disease, and, if diagnosed early patients have good prognosis. Accurate preoperative diagnosis of borderline tumors is not only useful for optimal surgical excision, especially in patients who desire fertility preservation it is

also essential for planning appropriate management. Currently, with all available imaging technologies, it is still difficult to differentiate between borderline and invasive ovarian tumors. Distinguishing between these two types of tumors is important, particularly for young patients who desire fertility conservation, yet challenging because of the similarity in imaging features that make them difficult to distinguish. During preoperative workup, differentiating between borderline ovarian tumors and early malignancies is crucial, and neither ultrasound nor MRI has provided encouraging results. The ultrasound signs of malignancy include: bilaterality of lesion, large lesion (> 4 cm), thick internal septations (> 2 mm), predominantly solid lesion, contrast enhancement of wall and septate and solid components.

Although 2D sonography is the primary screening imaging modality used to evaluate any suspected ovarian tumor, color Doppler ultrasound may provide additional information regarding the vascular pattern of the tumor. Exacoustos et al analyzed 33 cases with ovarian borderline tumors and concluded that the most common diagnostic feature on ultrasound imaging was the presence of papillae within the cyst. However, neither papillae nor other sonographic features constituted highly sensitive sonographic markers of borderline ovarian tumors (Exacoustos et al., 2005). 3D US and 3D power Doppler could provide supplementary information to diagnose borderline tumor (Kalmantis et al., 2007). Virtual spherical tissue sampling using 3D US power Doppler angiography to enhance the differentiation between normal and abnormal ovaries is another newer technique that may have future potential (Kudla et al., 2008).

One year later after our paper was published another study confirm our results. Hata et al presents a study on HDlive and adnexal tumors. The authors consider that, using HDlive, a better assessment of the tumor is possible. This new technology facilitates the intratumoral features and give natural and anatomically realistic appearance of the smooth thin or irregular thick septum, smooth or irregular papillary projection, and smooth, regular, or irregular inner surface in adnexal tumors. This could be also an advantage for the patient that may better understand the tumor condition during preoperative counseling (Hata et al., 2014).

- **Rare clinical conditions**

- *Ultrasound features of osseous metaplasia of the endometrium- case series and review of the literature*

In this paper we present a case series of four women with osseous metaplasia of the endometrium with different symptomatology. Osseous metaplasia of the endometrium is a rare condition characterized by abnormal bone formation in the uterine endometrium. The prevalence of osseous metaplasia is unknown, but is estimated to be approximately 0.002% among infertile women (Ghaffari, Tehraninejad & Kiani 2009); the prevalence in the general population is evidently considerably lower. Several theories regarding the pathophysiology of uterine osseous metaplasia exist. The most accepted theories for its origin are (1) the dystrophic calcification and ossification of residual fetal tissue after an abortion, and (2) the presence of totipotent cells in the endometrium with the capacity to transform into bone and cartilage (Wolff et al., 2007, Parente et al., 2009). The osseous fragments act like a foreign body in the uterine cavity; thus, infertility, menstrual abnormalities, pelvic pain dysmenorrhea, and dyspareunia are commonly associated. The most common complication associated with this pathology is secondary infertility, like in case 1 and 2; however, patients can also manifest other symptoms, such as pelvic

pain, dysmenorrhea, and menstrual disorders, like in case 3. Osseous metaplasia can sometimes be an incidental finding, as in case 4, and may act as an involuntary contraception.

Ultrasound 2D endovaginal examination played a primary role in the diagnosis in all our cases, the characteristic ultrasound pattern being a hyperechoic image in the uterine cavity, which may mimic a foreign body (most commonly an intrauterine device). Usually the hyperechoic region is located centrally, but it can be located in the isthmic part of the uterus, as in case 2, or in multiple areas, as in case 3. Given its rarity and the presence of calcification, the osseous tissue can be misdiagnosed as an IUD. 3D US, a very useful tool in both obstetrics and gynecology, aids in the diagnosis of osseous metaplasia, especially when the image appears as an IUD. By providing the coronal plane of the uterus, 3D ultrasound shows the irregular form of the osseous fragments, making the difference between an IUD and osseous metaplasia clear. The ultrasound examination should be confirmed by hysteroscopy, the gold standard for the management of this entity.

➤ *Three-dimensional ultrasound and HDlive in tubal serous cystadenofibroma: a case report and literature review*

Cystadenofibromas of the fallopian tubes are very rare benign tumors and very few cases have been reported in the literature worldwide. Usually, the tumor is asymptomatic, and for almost all cases reported, the tumors were incidentally discovered during surgery for other genital pathology. Usually, the diagnosis of cystadenofibroma could be difficult because macroscopically and ultrasonographically these tumors could appear malignant, resulting in radical surgery (*de Silva, Patil, Lawrence, 2010*). In our case, anticipating the diagnosis before surgery was helpful in deciding the type of surgery to perform. We believe that with a careful ultrasound examination, combining 2D Doppler ultrasound and 3D US, the diagnosis could be at least suspected. A helpful tool could be HDlive technology, which uses an adjustable light source, allowing the operator the possibility to create lighting and shadowing effects, thereby increasing depth perception. This technology is useful for a better assessment of the interior wall of the cysts (*Grigore, 2013*).

The most important differential diagnosis before surgery should be performed with primary fallopian tube carcinoma, a rare gynecologic malignancy, that accounts for less than 1% of all malignancies of the female genitalia. Preoperative diagnosis of fallopian tube carcinoma is difficult due to the silent course of this neoplasm and is usually first diagnosed at the time of operation or by a pathologist (*Rexhepi et al., 2017*). Sonographic features of tubal carcinoma are non-specific and include the presence of a fluid-filled adnexal structure with a significant solid component, a sausage-shaped mass, a cystic mass with papillary projections within, and a multilocular mass with cogwheel appearance (*Haratz-Rubinstein, Russell & Gal, 2004*).

1.4.4. STUDIES OF THREE DIMENSIONAL ULTRASONOGRAPHY IN INFERTILITY AND ENDOMETRIOSIS

1.4.4.1. Background

Infertility is considered as a major health care problem of different communities. The most common causes of female infertility include ovulation dysfunction, anomalies of the fallopian tubes or uterus or problems of the uterine cervix. Ultrasound represents a very useful tool in the diagnosis of female infertility. 3D US is used to diagnose uterine congenital anomalies, intrauterine pathology, to assess tubal patency, endometrial receptivity and to evaluate ovarian pathology. A new method of displaying sonographic volumes is called the inversion mode, which displays the cystic portions within the entire volume as echogenic areas. The grayscale portion of the image becomes transparent, and the cystic areas become brightly visible in three dimensions (*Lee, 2005*). Ongoing research will likely continue to define the clinical role of 3D ultrasound and its possible role in the near future to regard to 3D as the gold standard for pelvic imaging.

Color 3D-PDI with surface rendering allowed visualization of the flow of contrast substance through the entire tubal length and free spill of contrast was clearly identified in the majority of cases. The 3D-PDI method has advantages over the conventional HyCoSy technique, especially in terms of visualization of spill from the distal end of the tube, which was achieved twice as often with the 3D technique. The 3D-PDI techniques allowed better storage of the information for re-analysis and archiving than conventional HyCoSy. In addition, the procedure of 3D-HyCoSy appears to be better tolerated, requiring no sedation or anesthesia. In conclusion we can say that 3D-HyCoSy with saline solution, as a contrast medium is feasible and could comprise a routine outpatient procedure in the initial evaluation of infertile women.

Endometriosis is a condition characterized by the presence of uterine mucosal tissue outside the uterus. It affects 6%-10% of women of reproductive age and is usually located in the pelvis (*Burney, Giudice, 2012*). The disease can present as simple peritoneal implants or large areas of fibrosis with multiple intraperitoneal adhesions. Endometriosis can potentially cause irreversible infiltrative alterations and severe adhesive syndromes, and therefore, it is desirable to diagnose the disease in its early stages. Unfortunately, early diagnosis is not always easy, but recent progress in ultrasonography has increased the specificity and sensitivity of the sonographic diagnosis of endometriosis. The correct diagnosis rate was increased recently because of new sonographic technologies and software. Among those, the ones increasing the accuracy of two-dimensional ultrasound images (such as harmonic imaging, speckle reduction imaging and cross beam resolution imaging) as well as the ones allowing the use of three-dimensional sonography and of specific software (tomographic ultrasound imaging and volume contrast imaging). The imaging technologies improvements made easier the diagnosis and consequently a more accurate appraisal of the incidence of the disease but also a correct management in the early stages of this illness. Adenomyosis is a common gynecological disease that is defined as the presence of nonneoplastic ectopic endometrial glands and stroma in the myometrium. These characteristics are associated with reactive overgrowth of the musculature. Imaging techniques play an important role in the diagnosis of adenomyosis, with the main diagnostic techniques being ultrasonography and magnetic resonance imaging.

The obvious advantages are that 3D offers more rapid and reproducible image

acquisition as well as enhanced visualization and post-processing capabilities. Its main applications include assessment of uterine congenital anomalies, intrauterine pathology, tubal patency, polycystic ovaries, ovarian follicular monitoring and endometrial receptivity. Ongoing research will likely continue to define the clinical role of 3D ultrasound and it possible in the near future to regard to 3D as the gold standard for pelvic imaging. Our role is to continue to test it prospectively but to remain realistic and to examine how it may be most appropriately applied in the clinical setting. Although three-dimensional sonography largely remains an exciting research tool 3D will gradually become commonplace in most units.

As part of my research into 3D ultrasound in infertility, I have published 2 articles (original research and review articles) in journals indexed in the ISI Web of Science, and one abstract in a journal indexed in the ISI Web of Science.

Sonography at day three of the menstrual cycle is mandatory during infertility work-up. It allows planning of treatment options through the evaluation of the ovarian reserve. The objective of the study was to determine if 3D ultrasound gives more reliable information than the 2D examination during the ultrasound performed on the 3rd day of the menstrual cycle.

The purpose of our systematic review was to present the latest data regarding, risk factors, clinical findings and imagistic findings and management of abdominal wall endometriosis.

Published papers

1. **Grigore M**, Mares A 2D versus 3D ultrasound assessment for infertility evaluation on the 3-rd day of the cycle, *Giornale Italiano di Ostetrica e Ginecologia*, 2012; 34: 189-191.
2. **Grigore M**, Socolov D, Pavaleanu I, Scripcariu I, Grigore AM, Micu R Abdominal wall endometriosis: an update in clinical, imagistic features, and management options. *Med Ultrason* 2017;19:430-437. **IF 0,8**

I.4.4.2. Material and methods

- ***2D versus 3D ultrasound assessment for infertility evaluation on the 3-rd day of the cycle***

In our study we examine 44 patients with primary or secondary infertility. We examined this group of patients using both 2D and 3D ultrasound in day 2, 3 or 4 of the menstrual cycle with a Voluson E8 machine and 3 D endovaginal probe. We scanned the uterus and the both adnexa and we recorded the anomalies of the uterus for each particular case (detected by 2D or 3D ultrasound, or both), of the ovaries or fallopian tubes. We measured the total number of antral follicles, first by 2D and then automated by 3D ultrasound using sonoAVC software. For the 2D assessment of the antral follicles we used the standard technique which quantifies the size of a follicle by the mean diameter from two linear measurements of the follicle. In order to examine the coronal plane of the uterus with 3D ultrasound we used the "Z" technique developed by Abuhamad (*Abuhamad et al., 2006*).

- ***Abdominal wall endometriosis: an update in clinical, imagistic features, and management options***

We performed a systematic literature search of PubMed/MEDLINE, Google Scholar and Ovid for all research articles using the terms “abdominal wall endometriosis,” “abdominal wall endometriomas”, “abdominal wall mass”, Rectus abdominis scar” published until May 2017. The references of those articles were then reviewed and additional publications were evaluated.

I.4.4.3. Results

- ***2D versus 3D ultrasound assessment for infertility evaluation on the 3-rd day of the cycle***

We have examined 44 patients with primary infertility - 29 cases (65.9%) and secondary infertility - 15 cases (34,1%). Regarding uterine pathology, we had four cases with uterine myoma, one case with endometrial polyp, 3 cases with adenomyosis and one case with an arcuate uterus (table 16).

Table 16. Uterine pathology detected with 2D and 3D ultrasound

Uterine pathology	Nr. of cases	%
No endometrial or myometrial abnormalities	35	79,54%
Myoma	4	9,00%
Endometrial polyp	1	2,20%
Adenomyosis	3	6,80%
Arcuate uterus	1	2.20%

All of these 9 cases, except one were diagnosed first by 2D ultrasound and the diagnosed was then confirmed by 3D ultrasound. In a single case with a uterine malformation the diagnosed was missed by 2D ultrasound and it was established after obtaining the coronal plane of the uterus (table 17).

In all cases with myoma the diagnosis was made with 2D but adding coronal plane gave more information regarding the exact topography of the tumor. In one case the myoma was intracavitary and although this aspect was suggested by 2D, the 3D was more useful in confirming this aspect. The exact position of a myoma, the impact on the ostium tubae and on the uterine cavity may be difficult to assess by conventional ultrasound. Adenomyosis is a disease that regularly affects the endometrial-myometrial junction. The diagnosis is possible to be found by ultrasound if striations of the myometrium, anechoic foci in the myometrium and asymmetri uterine cavity could be visualized. In our cases the diagnosis was evidenced with both 2D and 3D sonography.

Table 17. Comparison between 2D and 3 D regarding detection of uterine anomalies

Uterine pathology	Diagnosis with 2D	Diagnosis with 3D	Diagnosis with 2D and improved by 3D
<i>Myoma</i>	+	+	+
<i>Endometrial polyp</i>	+	+	+

<i>Adenomyosis</i>	+	+	Not the case
<i>Arcuate uterus</i>	-	+	Not the case

Regarding the antral follicle count we performed a double measurement. First we counted them on 2D ultrasound using the standard technique. We measured each follicle with a mean size between 2 and 10 mm. Because some authors consider that is it best to count the follicle up to 8 or 9 mm we analyzed separately these sizes (Table 18).

Table 18. Number of antral follicle with 2D and 3D ultrasound

Follicle size	2D mean +/- SD	3D mean +/- SD	Mean difference
2-8 mm	17.51 +/- 11.51	16.33 +/- 12.13	1,18
2-9 mm	18.24 +/- 11.51	16.67 +/- 9.68	1,57
2-10 mm	18.82 +/- 10.75	17.18 +/- 9.75	1,64

We found no statistical significant difference between the two methods (2D vs 3D) regarding the number of follicles. We must emphasize although that the 3D count is obvious easier than the 2D method.

- *Abdominal wall endometriosis: an update in clinical, imagistic features, and management options*

Our review illustrates the imagistic diagnosis of several cases of abdominal wall endometriosis (AWE). From the imagistic methods useful we mention: 2D ultrasound, Doppler ultrasound, 3D ultrasonography and MRI (Fig.87-90).

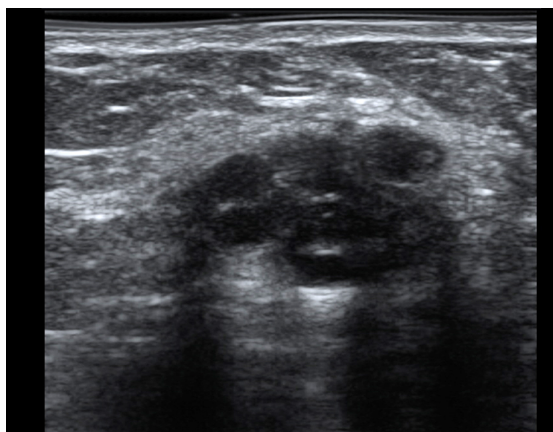


Fig. 87. Transverse sonogram of the abdominal wall showing a nodule with hypoechoic content and cystic images

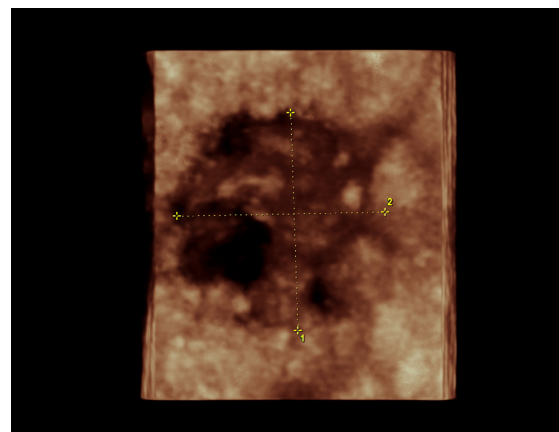


Fig. 88. The reconstructed coronal plane with 3D ultrasound shows the heterogeneous mass with irregular and speculated margins.

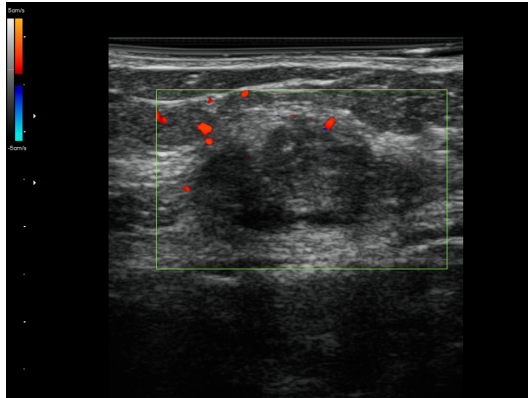


Fig. 89. Color Doppler US image shows peripheral flow within the mass.

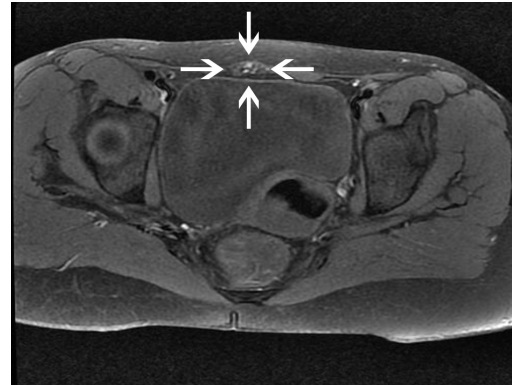


Fig. 90. MRI- Axial T1- enhanced T1-weighted fat-suppressed showing a mass (white arrows) within the anterior abdominal wall abutting the right rectus abdominis muscle with foci of hyper-intensity suggesting hemorrhage.

I.4.4.4. Discussion

- *2D versus 3D ultrasound assessment for infertility evaluation on the 3-rd day of the cycle*

3D US may facilitate diagnosis of endometrial polyps, using static acquisition, in direct or inversion modes. Also, the shape, the dimensions, the origin and the impact on the endometrial cavity are clearly visualized, guiding the therapeutic procedure. In our case the polyp was diagnosed during 2D examination and confirmed by 3D sonography and the coronal examination also confirmed the diagnosis. Uterine myomas are present on 2D ultrasound as focal enlargements of the uterus with a texture similar to the myometrium and posterior shadowing. The exact position, the impact on the ostium tubae and the uterine cavity may be difficult to assess by conventional ultrasound (*Oliveira et al., 2004*). A very easy solution in many cases is offered by a static 3D acquisition or static VCI-C. In our case with submucous myoma, the 3D ultrasound showed clearly its position inside the uterine cavity.

Although the incidence of uterine anomalies is evaluated in the literature as 7,7% and even higher in population with infertility, in our particular study we diagnosed only one case with arcuate uterus (*Saravelos, Cocksedge & Li, 2008*). It is important to emphasize that in our case the diagnosis was missed on 2D ultrasound and only after obtaining the coronal plane this uterine malformation was clearly seen. Uterine anomalies are undoubtedly the area where 3D sonography has contributed the most. While 2D US is an excellent screening examination for uterine anomalies, it is not as effective as 3D US in distinguishing specific malformations. 3D US does not replace 2D ultrasound but, rather, enhances it. Another important element evaluated during the day 3, ultrasound is ovarian reserve (*Haadsma et al., 2007*). It is estimated that the number of primordial follicles in the ovary is in direct correlation with the number of growing antral follicles. Different studies using transvaginal ultrasound have shown decreasing numbers of antral follicles as visualized by transvaginal sonography related to increasing age in both women without known fertility problems and in

women with proven natural fertility (Jayaprakasan *et al.*, 2007). The predictive value of antral follicle counts towards the probability of pregnancy in couples with more or less unexplained infertility or in couples in whom there is an indication for assisted reproductive procedures, has been the subject of many studies. Counting the true number of follicles with 2D transvaginal ultrasound could sometimes be difficult (Jayaprakasan *et al.*, 2007). With the recent availability of 3D ultrasound equipment the assessment of the antral follicle number may become more precise. Moreover, computerized counting on the basis of digitalized three-dimensional recordings is a new possibility today. We found no statistical difference in the number of antral follicle by 2D or 3D ultrasound. The difference could be in the case of measuring automated the follicle, the method being far more rapid than the manually count by 2D (Scheffer *et al.*, 2002).

A study performed by Peres Fagundes *et al* evaluate the usefulness of 3D SonoAVC technology for antral follicle count and its correlation to conventional 2D US and serum levels of anti-Müllerian hormone in infertile women (Peres Fagundes *et al.*, 2017). The study was performed on 42 infertile women that underwent treatment for infertility. On cycle day 3 they analyze the hormonal profile and the number of antral follicles. The scanning was performed through 2D and 3D technology transvaginal ultrasound. In their study antral follicle count was higher using 3D ultrasound technology compared to 2D technology ($p < 0.001$; Wilcoxon test). This finding is mainly remarkable in ovaries with more than 20 antral follicles. This result is in contradiction with our results, where we found no differences between 2D and 3D US when counting the antral follicles. A possible explanation is that in our case the women were not on a stimulation protocol for FIV and the number of follicles was low. The mean time required for manual 2D ultrasound and 3D SonoAVC measurements were 275 ± 109 and 103 ± 57 s, respectively ($p < 0.001$). This represents indeed a great advantage of 3D SonoAVC as it require less time for an examination especially when there are more than 20 follicles (Peres Fagundes *et al.*, 2017).

Ultrasound examination of any patient performing an infertility workup is an integral part of the standard patient management. This is always done by 2D transvaginal ultrasound. It allows proper examination of pelvic organs: uterus, ovaries and possibly tubes. In the last decade 3D ultrasound has been extensively developed and applied and the field of its use has broadened.

- ***Abdominal wall endometriosis: an update in clinical, imagistic features, and management options***

AWE is defined by the presence of endometrial tissue in the subcutaneous fatty layer and the muscles of the abdominal wall. It is usually caused by the dissemination of endometrial tissue in the wound at the time of obstetrical and gynecological surgeries. AWE endometriosis is rare and difficult to diagnose. The most frequent clinical presentation is that of a palpable subcutaneous mass near surgical scars associated with cyclic pain and swelling during menses. AWE may be an underreported pathology partly due to the fact that has scarcely received attention in the radiologic literature. It is expected anyhow its frequency to rise along with the increasing rate of cesarean sections, thus it is important that physicians or sonographers are familiar with this pathology.

Ultrasonography usually represents the first step in the evaluation of soft

tissue masses. Usually AWE appears on two-dimensional ultrasound as a nonhomogeneous hypoechoic mass with echogenic spots or thick echogenic strands that represent a fibrotic component in the abdominal wall (Fig. 126) (*Hensen, Van Breda Vriesman & Puylaert, 2006*). When AWE is compared with other forms of endometriosis, we can say that AWE has features similar to those of deep infiltrating pelvic endometriosis (*Hudelist et al, 2011*).

Regarding the scanning technique, proper magnification of the image is recommended to reduce the field of view to 3–5 cm in depth (*Savelli et al., 2012*). It is important first to identify on a transverse or longitudinal section the normal abdominal layers of the abdominal wall far from the site where the AWE is suspected. The following layers should be identified: the hyperechoic subcutaneous tissue and the hypoechoic muscle layer covered by the thin hyperechoic abdominal fascia. The peritoneum can be identified as a thin hyperechoic line located above the intestine. The peritoneal fat located underneath the muscular layer can help in identifying the peritoneum. Then, sliding the probe while exerting slight pressure will help to locate the AWE, as a result of the pain induced (*Savelli et al., 2012*).

The margins are ill defined and there are blurred outer borders. The mass infiltrates the surrounding tissue due to an inflammatory reaction triggered by the monthly hemorrhage in this tissue (*Francica et al., 2003*). A hyperechoic ring can be observed at the periphery of the nodule, and on histology, it represents edematous adipose tissue filled with cells of inflammatory origin (histiocytes and granulocytes) (*Savelli et al., 2012*). The echogenic patterns are dependent on the haemorrhagic and fibrous components of the lesions and on the phase of the patient's menstrual cycle.

The irregular shapes and borders of the endometriotic nodule appear clearer on the coronal plane of 3D ultrasound. The 3D coronal plane provided a more precise analysis of the surrounding tissue, and the depth of infiltration can be easily seen. 3D US plays an important role in preoperative assessment by measuring the mass in all three planes and assessing whether the AWE invades the abdominal fascia. This is important in preoperative evaluation of the mass, especially if no other imagistic tools like CT or MRI are used. MRI is also important in preoperative management. In case of a large nodule, mesh may be needed to repair the fascia, and these procedures require adequate counselling and precise surgical planning. Therefore, exact knowledge of the AWE location is helpful in planning the surgery, choosing the reference hospital and surgical team, predicting the time of surgery, and securing additional material, such as mesh (*Wozniak et al., 2015*).

The vascular pattern can be different, from small and scanty vascularized lesions to large lesions with several vascular pedicles entering the mass from different points to abundant central vascularization. Doppler velocimetry can show intralesional vascularization if the tumor size is greater than 15 mm (*Francica G et al, 2009*).

SECTION II. FUTURE PROJECTS IN THE ACADEMIC, PROFESSIONAL AND RESEARCH FIELD

II.1. IMPROVEMENTS IN THE ACADEMIC FIELD

Our century is marked by essential changes and development in technologies, science, education and medicine. As such, novel learning techniques are required. The traditional lecture format (teacher-based monologue) is considered monotonous and lecturers have to adapt by moving away from passive learning to new strategies for facilitating learning. Such changes mean that we have to implement innovative techniques to ensure the provision of high-quality medical education. Adopting new and more attractive educational strategies will stimulate the students' desire for knowledge and, at the same time, will ensure quality management in education. One way is to introduce the pre-class preparation lecture, which has the potential to enable an active classroom atmosphere with interactive presentations. This is possible through the e-learning platform where lectures, online applications, and clinical cases scenarios can be accessed before class, having the meeting with the teacher turn from monologue to vivid discussion. In this context, I strive to constantly update the courses designed for students and ensure that they are assessed periodically by means of tests and various evaluation approaches.

I also intend to continue to organize and develop new optional courses for students based on the successful experience of previous ones, organized in cooperation with the Iasi Medical Students Society (e.g. Minimally Invasive Surgery 2016, Ultrasound in Pregnancy 2018, Management of Labor 2019). I plan to propose more courses in the future combining theory and practice in order to cultivate in students a genuine interest in my specialty.

Practice is a key element in teaching obstetrics and gynecology successfully, and medical simulation plays an increasingly important role in the education of medical students, as it ensures a comprehensive and standardized training experience for all learners. The use of simulation in the education of obstetrics and gynecology will provide medical students with the opportunity to acquire the confidence, knowledge, skills, and workplace behaviors required to provide quality patient care in a safe learning environment. The Simulation Center, which will be soon inaugurated at our university, will enable me to improve practical skills in our students and residents. As the coordinator of the Discipline Obstetrics and Gynecology and the Simulation Center, I shall manage the didactic process as best as I can by developing appropriate undergraduate, graduate and postgraduate curricula for students, residents and specialists.

Another important aspect of my academic career consists in my mentorship of young trainees in Obstetrics and Gynecology. By collaborating with my younger colleagues, I will train them and this will, at the same time, motivate me to improve my teaching skills and keep on learning. Together with them, I will also continue to improve my research competences by applying for funding and writing articles for peer-reviewed journals. I will periodically organize sessions of case presentations, allowing the interns to develop the ability to speak in public speaking and to present clinical cases in a cohesive and a coherent manner a clinical case. Concurrently, regarding my relationship with the younger members of the teaching staff, I will

encourage and stimulate their professional development and continue to develop alongside them.

II.2. FURTHER PROFESSIONAL DEVELOPMENT

In a surgical clinical specialty such as this, the teaching activity cannot be separated from medical one, which is why it is important for me to constantly improve my clinical skills. Being a surgeon is a lifelong journey, and most surgeons continue to learn until the day they retire. The rapid evolution of technology and knowledge requires the surgeon to continuously evolve in this renewed environment. I will continue to attend national and international conferences and stay informed with regard to the latest discoveries in the field. One of my main objectives will be to keep our local clinical protocols up to date with global trends. Over the years, the internships and training courses that I completed have allowed me to develop the surgical competences of our team and contribute to the advancement of minimally invasive surgery in our university center (for instance, I am responsible for introducing minimally invasive techniques such as laparoscopic myomectomy and hysterectomy). These are of real benefit to both the patients in terms of postoperative recovery, as well as to the hospital, such approaches lowering costs and the number of hospitalization days required

Another professional goal I wish to accomplish in the following years is to continue and to improve my interdisciplinary collaborations. During the years I developed relationships with colleagues from other departments: pathology, epidemiology, oncology, anatomy. Together, we developed projects in the field of cervical cancer. In the same field of cervical cancer prevention, I developed relationships with the European Federation of Colposcopy and the European Society of Gynecologic Oncology, and renowned colleagues from abroad have visited us. With them, I organized three international workshops in Romania in order to increase the knowledge of my peers in this field.

Internationally, I would also like to continue collaboration with the **Cochrane Gynecology** group, of whom I am a member. In this format, I contributed to a systematic review and I wish to get involved in other projects of this prestigious team. Also, together with my colleagues from U.M.Ph. Tg. Mureș and U.M.Ph. București, we would like to establish a Cochrane group in Romania.

II.3. PERSPECTIVES FOR FUTURE RESEARCH

My development plan research wise is in keeping with the principle of continuous growth. My objectives are to pursue and expand research in the directions presented in this thesis and in new fields, targeting:

- HPV infections, precancerous lesions and colposcopy
- 3D ultrasonography and minimally invasive surgery.

II.3.A HPV infections, precancerous lesions and colposcopy

In the field of precancerous diseases and cervical cancer, I intend to focus on:

II.3.A.1. HPV self-sampling

According to the guidelines of the International Agency for Research in Cancer (IARC), one of the most important factors for screening effectiveness is coverage, defined as the number of women tested within a recommended interval (*IARC Handbook*, 2005). There are many types of barriers that prevent participation in a cervical screening program: feelings of embarrassment and shame, reluctance to having a genital examination, experience of discomfort or pain at a past clinical visit, economic problems, lack of information regarding the importance of the screening.

Offering women the possibility to self-collect vaginal or cervical samples at home for HPV detection has been proposed as a means to increase participation in cervical cancer screening programs. Self-sampling may result in more individuals willing to participate in cervical cancer screening, because it removes many of the above mentioned inhibiting factors, especially for women in low socioeconomic and minority populations. A recent meta-analysis encompassing 37 studies on 18,516 women from 24 countries across five continents indicated strong acceptance of self-sampling and a preference for self-sampling over clinician sampling (*Nelson et al.*, 2017). Women participating in self-sampling trials for cervical cancer screening reported a positive experience with HPV self-sampling.

The participation rate in a self-sampling screening varies among different countries or population in which the study took place. In a study on 667 Swiss women, participation of women offered self-sampling was not higher than that of those offered sampling by a clinician (*Viviano et al.*, 2017). However, a national cervical cancer screening program does not exist in Switzerland and participation in both study cohorts was much higher than in most other countries.

Furthermore, self-collection might be of particular benefit for women of certain socioeconomic groups. A study involving 346 women from underserved rural areas of Northern Greece, of whom only 17.1% had been regularly participating in Pap smear screening, found that 100% were willing to self-sample, with 90% willing to self-sample regularly if this option was available (*Chatzistamatiou et al.*, 2017).

In Romania, during the first four years of cervical screening, the participation rate in the northeastern part of the country was low (16.88%) and continued to decrease at an alarming rate. Thus, several measures should be taken in order to boost participation in the screening program. Self-sampling for HPV is mostly indicated for women living in low-income settings with poor access to health services and might be effective for the cervical cancer screening of non-attenders in the framework of organized screening (*Verdoodt et al.*, 2015). It would be interesting to find out if self-sampling could work as an additional method offered to Romanian women in order to increase their participation in screening program. I would like to develop a pilot study to test the feasibility of HPV self-sampling screening in an underserved rural female population.

II.3.A.2. The vaginal microbiome and its role in HPV infection and the progression of cervical lesions

HPV infection with high-risk types represents an essential condition for developing cervical cancer. HPV infection is very common especially in young women and only persistent infection leads to cervical cancer. Persistent infection with oncogenic HPV is necessary but not sufficient for the development of cervical cancer. Additional recognized factors correlated with persistent HPV infection include immunodeficiency caused by HIV, smoking, oral contraceptives and, more recently reported, vaginal dysbiosis (*Mitra et al.*, 2016).

Normally, the cervicovaginal microbiome is dominated by one or more *Lactobacillus* species (*L. crispatus*, *L. gasseri*, *L. iners*, or *L. jensenii*, and others). However, when in a state of dysbiosis, there is a marked reduction of *Lactobacillus* and a high diversity of bacteria, with an increased abundance of anaerobic bacterial species.

Mitra et al. have shown that a reduction of *Lactobacillus* p combined with increased diversity within the cervico-vaginal microbiome are risk factors for HPV acquisition, persistence, and development of cervical intraepithelial neoplasia leading up to cervical cancer (Mitra et al., 2016). Chao et al. found that, of the 30 most abundant bacteria at the genus level, six bacteria occurrence patterns differed significantly in HPV-positive versus HPV-negative women: *Bacteroides*, *Acinetobacter*, *Faecalibacterium*, *Streptococcus*, *Finegoldia*, and *Moryella*. Also, they reported that anaerobic bacteria such as *Bacteroides plebeius*, *Acinetobacter lwoffii*, and *Prevotella buccae* were found significantly more frequently in HPV-positive women, which is the most important finding of their study (Chao et al., 2019).

These findings suggest that the composition of the vaginal microbiome can play a role in high-risk HPV infection, and specific microbiome species may initiate the changes in the cervical microenvironment associated high-risk HPV infection. An abnormal vaginal microbiome may be a co-factor for the acquisition of HPV. More research is needed focusing on the synergic effect of the vaginal microbiome and HPV acquisition on cervical lesions. Moreover, the molecular mechanism of the vaginal microbiome in the course of high-risk HPV infection and cervical neoplasia should be explored. Future research should include methods for restoring the composition of the vaginal microbiome in order to reverse the course of high-risk HPV infection and the natural history of cervical neoplasia. It is interesting to think that persistent high-risk HPV infection and the natural course of cervical lesions caused by high-risk HPV could be suppressed by interfering with microorganisms in the vagina. In light of this hypothesis, I would like to investigate the relationship between the composition of the vaginal microbiome, the likelihood of high-risk HPV infection and possible ways to restore the normal microbiome of the vagina.

II.3.A.3. 3D-printed learning models (simulators) for cervical surgeries

Three-dimensional (3D) printing is a new and dynamic technology. In recent years, there has been exponential development related to the use of 3D printers used in healthcare education. Inexpensive 3D printers and printing supplies are now available in the consumer market. This technique enables a 3D digital model to be converted into a physical model by printing it layer by layer.

Much research has already gone into developing 3D-printed devices for medical purposes. 3D printing has been shown to be useful in the medical field for a variety of purposes: patient education, education for healthcare professionals, procedure planning, and prosthesis or implant production. (Biglino et al., 2015; Nikitiev et al., 2016; Javan, 2018). In most medical fields, 3D printing applications are still in being designed or assessed or have only just entered clinical practice. Hence, there has been a lack of research into the clinical efficacy, effectiveness and long-term follow-up in comparison to traditional technologies (Mulford, Babazadeh & Mackay, 2016). There is a clear need for validation of new devices, materials and techniques to ensure best patient outcome (Diment, Thompson & Bergmann, 2017).

In surgery, simulation is gaining in importance. There are many advantages attributed to simulation: increased surgical skills, reduced surgical time and fewer surgical complications. Patient-specific models with anatomical fidelity created from

imaging datasets have the potential to significantly improve the knowledge and skills of new generations of surgeons.

In cervical lesion management, it can be a challenging step for trainees to go straight from diagnostic colposcopy to treatment of real life individuals. I would like to introduce 3D printers to create a practical hands-on training device to mimic realistic clinical scenarios for colposcopy and LLETZ/LEEP procedures (Large Loop Excision of the Transformation Zone). This will be valuable for all physicians because they will work with a model that can deliver practical benefits without the risks or potential difficulties of working with a real patient. In addition, such a device could be used for training the ability to perform cervical, vaginal and vulvar biopsies with different types of instruments and especially the same electro-surgical tools that are actually going to be used for treatment, thus making the training experience very realistic. This would be an authentic training simulator for cervical treatments, improving confidence and skills with no risk to patients. It will be useful for both trainees but also to qualified colposcopists who wish to learn a different or alternative procedure.

II.3.B. The role of 3D-ultrasonography in the diagnosis and management of isthmocele

The incidence of the isthmocele (symptomatic cesarean scar defect or niche) has increased in recent years due to a rise in cesareans. Isthmocele could be responsible for several obstetric complications (placenta accreta, scar dehiscence, and ectopic scar pregnancy) or gynecologic conditions (including abnormal uterine bleeding, endometritis, pelvic pain and infertility) and thus requires proper management.

The management of isthmocele implies minimally invasive techniques. Several innovative surgical therapies to reduce these complaints have been developed. The rationale for definite treatment is to remove the old scar and repair it again. The defect can be repaired either by hysteroscopy or by laparoscopy.

The least invasive surgical therapy is the hysteroscopic resection of the niche. Up to now, only a few studies focused on hysteroscopic resections of the niche, reporting high success rates for the reduction of postmenstrual spotting and no major complications (*Fabres et al., 2005; Gubbini, Casadio & Marra, 2008; Feng et al., 2012*) However, sample sizes were small and most studies do not include a clear methodology, follow-up or (validated) tools to measure outcomes.

Overall, the laparoscopy has the advantage of increasing uterine wall in comparison with hysteroscopy. At the same time, the latter approach does not strengthen the uterine wall. Nevertheless, in large niches with thin residual myometrium (less than 3 mm), there is a risk of bladder injury and uterine perforations.

Most of the studies regarding the surgical treatment of the isthmocele are retrospective, so a prospective assessment of the benefits of surgical treatment and the impact on both symptomatology and fertility is needed. Such research should focus on long-term follow up of complaints, niche characteristics and fertility outcomes, and on identifying predictors for clinical failure. The benefit of laparoscopic niche resection in asymptomatic women with large niches and subfertility should be studied in a randomized controlled trial before it is implemented for this indication in daily practice. I would also like to explore the potential role of 3D ultrasonography in planning the type of surgery for a symptomatic niche. Available studies used only measurements from 2D ultrasound. I am interested in seeing if a better assessment of

the niche (with additional depiction of the coronal plane) can help with establishing clear limits for hysteroscopic repair. In this way, we could appraise the limitations of hysteroscopy and opt for the laparoscopic approach in these cases.

II. 4. FINAL REMARKS

This habilitation thesis contains information about my scientific, professional and academic trackrecord during the period 2001-2019, after I obtained my doctoral degree in medical science. The opportunity of supervising PhD candidates would greatly motivate me to continue my development as an academic professor and as a physician.

Last but not least, I intend to get involved in further advancing the reputation the obstetrics and gynecology school from Iași, and to ensure its continuity in the future by improving my training of young physicians. I also plan on increasing international visibility for both my department and the university and on promoting scientific exchanges between Romania and other countries.

SECTION III. REFERENCES

- Abehsera D, de la Calle M, Rodríguez R, et al. Bipolar cord coagulation for selective feticide in a monochorionic twin pregnancy complicated by pentalogy of Cantrell. *Taiwan J Obstet Gynecol* 2016; 55:135-137.
- Abiodun OA, Olu-Abiodun OO, Sotunsa JO, Oluwole FA. Impact of health education intervention on knowledge and perception of cervical cancer and cervical screening uptake among adult women in rural communities in Nigeria. *BMC Public Health* 2014; 14: 814 doi: 10.1186/1471-2458-14-814.
- Abu-Rustum NR, Gemignani ML, Moore K, et al. Total laparoscopic radical hysterectomy with pelvic lymphadenectomy using the argon-beam coagulator: pilot data and comparison to laparotomy. *Gynecol Oncol* 2003; 91:402–409.
- Abuhamad AZ, Singleton S, Zhao Y, Bocca S. The Z technique: an easy approach to the display of the mid-coronal plane of the uterus in volume sonography. *J Ultrasound Med* 2006; 25:607-612.
- Acs G. Serous and mucinous borderline (low malignant potential) tumors of the ovary. *Am J Clin Pathol* 2005; 123: 13-57.
- Åhrlund-Richter A, Cheng L, Hu Yoo, et al. Changes in cervical Human Papillomavirus (HPV) prevalence at a youth clinic in Stockholm, Sweden, a decade after the introduction of the HPV vaccine. *Front Cell Infect Microbiol* 2019; 9:59 doi:10.3389/fcimb.2019.00059.
- Alcazar JL. Transvaginal colour Doppler in patients with ovarian endometriomas and pelvic pain. *Hum Reprod* 2001; 16: 2672-2675.
- Antiel RM, Curlin FA, Lantos JD, et al. Attitudes of paediatric and obstetric specialists towards prenatal surgery for lethal and non-lethal conditions. *J Med Ethics* 2018; 44:234-238.
- Arbyn M, Anttila A, Jordan J. European guidelines for quality assurance in cervical cancer screening. *AnnOncol* 2010; 21: 448–458.
- Arbyn M, Kyrgiou M, Simoens C, Raifu AO, Koliopoulos G, Martin-Hirsch P. Perinatal mortality and other severe adverse pregnancy outcomes associated with treatment of cervical intraepithelial neoplasia: meta-analysis. *BMJ* 2008; 337:a1284doi:10.1136/bmj.a1284.
- ASCUS-LSIL Triage Study (ALTS) Group. A randomized trial on the management of low-grade squamous intraepithelial lesion cytology interpretations. *Am J Obstet Gynecol* 2003; 188:1393-1400.
- Ates O, Karakaya E, Hakguder G, Olguner M, Secil M, Akgur FM. Laparoscopic excision of a giant ovarian cyst after ultrasound-guided drainage. *J Pediatr Surg* 2006; 41:9-11.
- Auekitrungrueng R, Tinnangwattana D, Tantipalakorn C et al. Comparison of the diagnostic accuracy of International Ovarian Tumor Analysis simple rules and the risk of malignancy index to discriminate between benign and malignant adnexal masses. *Int J Gynaecol Obstet* 2019;doi: 10.1002/ijgo.12891.
- Bahmani A, Baghianimoghadam MH, Enjezab B, Mazloomi Mahmoodabad SS, Askarshahi M. Factors affecting cervical cancer screening behaviors based on the precaution adoption process model: a qualitative study. *Glob J Health Sci* 2015; 8:211-218.

- Bansal N, Herzog TJ, Seshan VE, Schiff PB, Burke WM, Cohen CJ. Uterine carcinosarcomas and grade 3 endometrioid cancers: evidence for distinct tumor behavior. *Obstet Gynecol* 2008; 112:64-70.
- Baskaran P, Subramanian P, Rahman RA, Ping WL, Mohd Taib NA. Perceived susceptibility, and cervical cancer screening benefits and barriers in Malaysian women visiting outpatient clinics. *Asian Pac J Cancer Prev* 2013; 14:7693-7699.
- Basu P, Mittal S, Bhadra Vale D, Chami Kharaji Y. Secondary prevention of cervical cancer. *Best Pract Res Clin Obstet Gynaecol* 2018; 47:73–85.
- Batukan C, Ozgun MT, Basbug M. First trimester diagnosis of sacrococcygeal teratoma using two- and three-dimensional ultrasound. *J Clin Ultrasound* 2011; 39:160doi: 10.1002/jcu.20791.
- Biglino G, Capelli C, Wray J et al. 3D-manufactured patient-specific models of congenital heart defects for communication in clinical practice: feasibility and acceptability. *BMJ Open* 2015; 5:e007165 doi:10.1136/bmjopen-2014-007165.
- Bonilla-Musoles F, Raga F, Castillo JC et al. High Definition Real-Time Ultrasound (HDlive) of embryonic and fetal malformations before week 16. *Donald School J Ultrasound Obstet & Gynecol* 2013; 7:1-8.
- Bos AB, Rebolj M, Habbema JD, van Ballegooijen M. Nonattendance is still the main limitation for the effectiveness of screening for cervical cancer in the Netherlands. *Int J Cancer* 2006; 119:2372-2375.
- Bowring J, Strander B, Young M, Evans H, Walker P. The Swede score: evaluation of a scoring system designed to improve the predictive value of colposcopy. *J Low Genit Tract Dis* 2010; 14:301-305.
- Bray F, Ferlay J, Soerjomataram I, Siegel RL, Torre LA, Jemal A. Global cancer statistics 2018: GLOBOCAN estimates of incidence and mortality worldwide for 36 cancers in 185 countries. *CA: A Cancer J Clinic* 2018; 68: 394-424.
- Broberg G, Jonasson JM, Ellis J et al. Increasing participation in cervical cancer screening: telephone contact with long-term non-attendees in Sweden. Results from RACOMIP, a randomized controlled trial. *Int J Cancer* 2013; 133:164-171.
- Brotherton JM, Fridman M, May CL et al. “Early effect of the HPV vaccination programme on cervical abnormalities in Victoria, Australia: an ecological study”. *Lancet* 2011; 377: 2085.
- Brotherton JML, Bloem PN. Population-based HPV vaccination programmes are safe and effective: 2017 update and the impetus for achieving better global coverage. *Best Pract Res Clin Obstet Gynaecol* 2017; 47: 42–58.
- Bucella D, Frédéric B, Noël JC. Giant cervical polyp: a case report and review of a rare entity. *Arch Gynecol Obstet* 2008; 278:295-298.
- Burney RO, Giudice LC. Pathogenesis and pathophysiology of endometriosis. *Fertil Steril* 2012; 98:511-519.
- Caldas R, Rodrigues C, Pina C, Nogueira R. Dichorionic twins discordant for body-stalk anomaly: a management challenge. *BMJ Case Rep* 2018; pii: bcr-2017-223825 doi:10.1136/bcr-2017-223825.
- Campbell S. Prenatal ultrasound examination of the secondary palate. *Ultrasound Obstet Gynecol* 2007; 29:124–127.

- Carmi R, Boughman JA. Pentalogy of Cantrell and associated midline anomalies: A possible ventral midline developmental field. *Am J Med Genet* 1992; 42:90-95.
- Carozzi F, Puliti D, Ocello C, et al. Monitoring vaccine and non-vaccine HPV type prevalence in the post-vaccination era in women living in the Basilicata region, Italy. *BMC Infect Dis* 2018; 18:38<https://doi.org/10.1186/s12879-018-2945-8>.
- Castanon A, Landy R, Brocklehurst P, Evans H, Peebles D, Singh N. Risk of preterm delivery with increasing depth of excision for cervical intraepithelial neoplasia in England: nested case-control study. *BMJ* 2014; 349:g6223doi: 10.1136/bmj.g6223.
- Champaneria R, Abedin P, Daniels J, Balogun M, Khan KS. Ultrasound scan and magnetic resonance imaging for the diagnosis of adenomyosis: systematic review comparing test accuracy. *Acta Obstet Gynecol Scand* 2010; 89:1374-1384.
- Chao XP, Sun TT, Wang S et al. Correlation between the diversity of vaginal microbiota and the risk of high-risk human papillomavirus infection. *Int J Gynecol Cancer* 2019; 29:28-34.
- Chatzistamatiou K, Chatzaki E, Constantinidis T, Nena E, Tsertanidou A, Agorastos T. Self-collected cervicovaginal sampling for site-of-care primary HPV-based cervical cancer screening: a pilot study in a rural underserved Greek population. *J Obstet Gynaecol* 2017; 37:1059-1064.
- Chaubey L, Kumar D, Prakash V, Nath G. Menstrual blood versus endometrial biopsy in detection of genital tuberculosis by using nested polymerase chain reaction in an endemic region. *J Hum Reprod Sci* 2019; 12:35–39.
- Cheng VC, Yew WW, Yuen KY. Molecular diagnostics in tuberculosis. *Eur J Clin Microbiol Infect Dis* 2005; 24:711–720.
- Christian WJ, Christian A, Hopenhayn C. Acceptance of the HPV vaccine for adolescent girls: analysis of state-added questions from the BRFSS. *J Adolesc Health* 2009; 5:437-445.
- Coles VA, Patel AS, Allen FL, Keeping ST, Carroll SM. The association of human papillomavirus vaccination with sexual behaviours and human papillomavirus knowledge: a systematic review. *Int J STD AIDS* 2015;11:777-788.
- Conner SN, Frey HA, Cahill AG, Macones GA, Colditz GA, Tuuli MG. Loop electrosurgical excision procedure and risk of preterm birth: a systematic review and meta-analysis. *Obstet Gynecol* 2014; 123:752–761.
- Cooper K, Lee A, Chien P, Raja E, Timmaraju V, Bhattacharya S. Outcomes following hysterectomy or endometrial ablation for heavy menstrual bleeding: retrospective analysis of hospital episode statistics in Scotland. *BJOG* 2011; 118:1171–1179.
- Cooper N, Khan K. Defining core outcomes for clinical trials of heavy menstrual bleeding: a Core Outcome Sets for Gynaecological conditions (COGS) project. *COMET Initiative* 2018 doi: 10.1186/s13063-017-2244-5.
- Craciun C, Baban A. "Who will take the blame?: understanding the reasons why Romanian mothers decline HPV vaccination for their daughters. *Vaccine* 2012; 30: 6789-6793.

- Cruickshank ME, Pan J, Cotton SC et al. Reduction in colposcopy workload and associated clinical activity following human papillomavirus (HPV) catch-up vaccination programme in Scotland: an ecological study. *BJOG* 2017;124:1386-1393.
- Dannecker C, Siebert U, Thaler CJ, Kiermeir D, Hepp H, Hillemanns P. Primary cervical cancer screening by self-sampling of human papillomavirus DNA in internal medicine outpatient clinics. *AnnOncol* 2004; 15:863–869.
- de Silva TS, Patil A, Lawrence RN. Acute presentation of a benign cystadenofibroma of the fallopian tube: a case report. *J Med Case Rep* 2010; 4:181doi: 10.1186/1752-1947-4-181.
- de Souza S, Camargos A, de Rezende C, Pereira F, Araujo C, Silva Filho A. A randomized prospective trial comparing the levonorgestrel-releasing intrauterine system with thermal balloon ablation for the treatment of heavy menstrual bleeding. *Contraception* 2010; 81:226–231.
- De Villiers, EM. Crossroads in the classification of papillomaviruses. *Virology* 2013; 445, 2–10.
- Deb S, Campbell BK, Clewes JS, Raine-Feninning NJ. Quantitative analysis of antral follicle number and size: a comparison of two-dimensional and automated three-dimensional ultrasound techniques. *Ultrasound Obstet Gynecol* 2010; 35: 354-360.
- Delere Y, Remschmidt C, Leuschner J et al. Human Papillomavirus prevalence and probable first effects of vaccination in 20 to 25 year-old women in Germany: a population-based cross-sectional study via home-based self-sampling *BMC Infect Disease* 2014; 14:87 doi: 10.1186/1471-2334-14-87.
- DeNardis SA, Lavin PT, Livingston J et al. Increased detection of precancerous cervical lesions with adjunctive dynamic spectral imaging. *Int J Womens Health* 2017; 9:717-725.
- Diment LE, Thompson MS, Bergmann JHM. Clinical efficacy and effectiveness of 3D printing: a systematic review *BMJ Open* 2017;7:e016891doi: 10.1136/bmjopen-2017-016891.
- Ditto A, Martinelli F, Bogani G, et al. Implementation of laparoscopic approach for type B radical hysterectomy: a comparison with open surgical operations. *Eur J Surg Oncol* 2015; 41:34–39.
- Döbrössy L, Kovács A, Budai A. Inequalities in cervical screening practices in Europe. *Diversity & Equality in Health and Care* 2015;12: 48-53.
- Droegemueller W. Benign gynecologic lesions. In: Stenchever MA, Droegemueller W, Herbst AL, Mishell DR, eds. *Comprehensive Gynecology*. St. Louis: Mosby Inc.; 2001:495–497.
- Duke P, Godwin M, Ratnam S et al. Effect of vaginal self-sampling on cervical cancer screening rates: a community-based study in Newfoundland. *BMC Women Health* 2015; 15:47doi: 10.1186/s12905-015-0206-1.
- Dunn TS, Burke M, Shwayder JA. “See and treat” management for high-grade squamous intraepithelial lesion pap smears. *J Low Genit Tract Dis* 2003; 7: 104-106.
- Ebisch RM, Rovers MM, Bosgraaf RP et al. Evidence supporting see-and-treat management of cervical intraepithelial neoplasia: a systematic review and meta-analysis. *BJOG* 2016; 123:59-66.

- Ehrmann DA, Liljenquist DR, Kasza K, Azziz R, Legro RS, Ghazzi MN. Prevalence and predictors of the metabolic syndrome in women with polycystic ovary syndrome. *J Clin Endocrinol Metab* 2006; 91:48–53.
- Engels AC, Debeer A, Russo FM, et al. Pericardio-amniotic shunting for incomplete Pentalogy of Cantrell. *Fetal Diagn Ther* 2017; 41:152-156.
- Ergun B, Kuru O, Sen S, Kilic Y, Bastu E. Rollerball endometrial ablation versus levonorgestrel releasing intrauterine system in the management of abnormal uterine bleeding. *Romanian J Soc Ultrason Obstet and Gynecol* 2012; 8:199–201.
- Everett T, Bryan A., Griffin MF, et al. Interventions targeted at women to encourage the uptake of cervical screening. *Cochrane Database Syst Rev*. 2011;11;(5):CD002834. doi: 10.1002/14651858.CD002834.pub2.
- Exacoustos C, Brienza L, Giovanni A, Szabolcs B, Romanini ME, Zupi E. Adenomyosis: three-dimensional sonographic findings of the junctional zone and correlation with histology. *Ultrasound Obstet Gynecol* 2011; 37:471-479.
- Exacoustos C, Romanini ME, Rinaldo D et al. Preoperative sonographic features of borderline ovarian tumors. *Ultrasound Obstet Gynecol* 2005; 25:50-59.
- Fabres C, Arriagada P, Fernández C, Mackenna A, Zegers F, Fernández E. Surgical treatment and follow-up of women with intermenstrual bleeding due to cesarean section scar defect. *J Minim Invasive Gynecol* 2005; 12:25-28.
- Faivre E, Fernandez H, Deffieux X, et al. Accuracy of three-dimensional ultrasonography in differential diagnosis of septate and bicornuate uterus compared with office hysteroscopy and pelvic magnetic resonance imaging. *J Minim Invasive Gynecol* 2012; 19:101–106.
- Feng YL, Li MX, Liang XQ, Li XM. Hysteroscopic treatment of postcesarean scar defect. *J Minim Invasive Gynecol* 2012; 19:498–502.
- Ferlay J, Colombet M, Soerjomataram I, et al. Cancer incidence and mortality patterns in Europe: Estimates for 40 countries and 25 major cancers in 2018. *Eur J Cancer* 2018; 103:356-387.
- Fiander A. Prophylactic human papilloma virus vaccination update. *The Obstetrician & Gynaecologist* 2009; 11:133–135.
- Franceschi S, Herrero R, Clifford GM, et al. Variations in the age-specific curves of human papillomavirus prevalence in women worldwide. *Int J Cancer* 2006; 119: 2677–2684.
- Francica G, Giardiello C, Angelone G, Cristiano S, Finelli R, Tramontano G. Abdominal wall endometriomas near cesarean delivery scars: sonographic and color Doppler findings in a series of 12 patients. *J Ultrasound Med* 2003; 22:1041-1047.
- Francica G, Scarano F, Scotti L, Angelone G, Giardiello C. Endometriomas in the region of a scar from Cesarean section: sonographic appearance and clinical presentation vary with the size of the lesion. *J Clin Ultrasound* 2009; 37: 215-220.
- Galaal K, Bryant A, Fisher AD, Al-Khaduri M, Kew F, Lopes AD. Laparoscopy versus laparotomy for the management of early stage endometrial cancer. *Cochrane Database Syst Rev* 2012; (9):CD006655 doi: 10.1002/14651858.CD006655.pub2.

- Garg S, Kaur A, Mohi JK, Sibia PK, Kaur N. Evaluation of IOTA simple ultrasound rules to distinguish benign and malignant ovarian tumours. *J Clin Diagn Res* 2017; 11:6–9.
- Garne E, Dolk H, Loane M, Boyd PA. “EUROCAT website data on prenatal detection rates of congenital anomalies”. *Journal of Medical Screening* 2010; 17: 97–98.
- Georgalis L, de Sanjosé S, Esnaola M, Bosch FX, Diaz M. Present and future of cervical cancer prevention in Spain: A cost-effectiveness analysis. *Eur J Cancer Prev* 2016; 25: 430–439.
- Getahun F, Mazengia F, Abuhay M, Birhanu Z. Comprehensive knowledge about cervical cancer is low among women in Northwest Ethiopia. *BMC Cancer* 2013; 13:2 <https://doi.org/10.1186/1471-2407-13-2>.
- Ghaffari F, Tehraninejad ES, Kiani K. Retained fetal bone in infertile patients: Two case reports. *Int J Fertil Steril* 2009; 3:153-154.
- Gilks CB, Clement PB, Hart WR, Young RH. Uterine adenomyomas excluding atypical polypoid adenomyomas and adenomyomas of endocervical type: a clinicopathologic study of 30 cases of an underemphasized lesion that may cause diagnostic problems with brief consideration of adenomyomas of other female genital tract sites. *Int J Gynecol Pathol* 2000; 19:195–205.
- Globocan GLOBOCAN. Estimated cancer incidence, mortality and prevalence worldwide in 2012. http://globocan.iarc.fr/pages/fact_sheets_cancer.aspx.
- Gokmen Karasu AF, Sonmez FC, Aydin S, Adanir I, Marasli M, Ilhan GK. Survivin expression in simple endometrial polyps and tamoxifen-associated endometrial polyps. *Int J Gynecol Pathol* 2018; 37:27-31.
- Gräf C, Kupec T, Stickeler E, Goecke T, Meinhold-Heerlein I, Najjari L. Tomographic ultrasound imaging to control the placement of tension-free transobturator tape in female urinary stress incontinence, *BioMed Res Interational* 2016. <http://dx.doi.org/10.1155/2016/6495858>.
- Grasso S, Loizzi V, Minicucci V et al. Malignant mixed müllerian tumour of the uterus: analysis of 44 Cases. *Oncology* 2017; 92:197-204.
- Grigore M. HDlive pictures of a serous ovarian borderline tumor. *Ultrasound Obstet Gynecol*, 2013; 41: 598-599.
- Gubbini G, Casadio P, Marra E. Resectoscopic correction of the “isthmocoele” in women with postmenstrual abnormal uterine bleeding and secondary infertility. *J Minim Invasive Gynecol* 2008; 15:172–175.
- Guducu N, Sidar G, Bassullu N, Turkmen I, Dunder I. Three-step approach versus see-and-treat approach in patients with cytological abnormalities. *Int J Clin Exp Med* 2013; 6:372–376.
- Gupta J, Kai J, Middleton L, et al. ECLIPSE Trial Collaborative Group. Levonorgestrel intrauterine system versus medical therapy for menorrhagia. *N Engl J Med* 2013; 368:128-137.
- Haadsma ML, Bukman A, Groen H, Roeloffzen EM. The number of small antral follicles (2-6 mm) determines the outcome of endocrine ovarian reserve tests in a subfertile population. *Hum Reprod* 2007; 22:1925-1931.
- Haratz-Rubinstein N, Russell B, Gal D. Sonographic diagnosis of Fallopian tube carcinoma. *Ultrasound Obstet Gynecol* 2004; 24:86-88.
- Hasanzadeh M, Naderi HR, Hoshyar AH, Shabane S, Shahidsales S. Female genital tract tuberculosis presenting as ovarian cancer *J Res Med Sci* 2014; 19: 184–189.

- Hata T, Kanenishi K, Hanaoka U, Marumo G. HDlive and 4D US in the assessment of fetal facial expressions. *Donald School J US Obstet Gynecol* 2015; 9:44–50.
- Hata T, Kanenishi K, Mashima M et al. HDlive rendering image of adnexal tumors: preliminary report. *J Med Ultrason* 2014; 41:181-186.
- Heikinheimo O, Fraser I. The current status of hormonal therapies for heavy menstrual bleeding. *Best Pract Res Clin Obstet Gynaecol* 2017; 40:111-120.
- Hensen JH, Van Breda Vriesman AC, Puylaert JB. Abdominal wall endometriosis: clinical presentation and imaging features with emphasis on sonography. *AJR* 2006; 186: 616-620.
- Higham JM, O'Brien PMS, Shaw RW. Assessment of menstrual blood loss using a pictorial chart. *Br J Obstet Gynaecol* 1990; 97:734–739.
- Holowaty P, Miller AB, Rohan T, To T. Natural history of dysplasia of the uterine cervix. *J Natl Cancer Inst* 1999; 91:252–258.
- Homer HA, Li TC, Cooke ID. The septate uterus: a review of management and reproductive outcome. *Fertil Steril* 2000; 73:1-14.
- Hudelist G, Ballard K, English J et al. Transvaginal sonography vs. clinical examination in the preoperative diagnosis of deep infiltrating endometriosis. *Ultrasound Obstet Gynecol* 2011; 37: 480-487.
- IARC Handbooks of Cancer Prevention. IARC Press, Lyon, 2005.
- Irvin WP Jr, Andersen WA, Taylor PT Jr, et al. “See-and treat” loop electrosurgical excision. Has the time come for a reassessment? *J Reprod Med* 2002; 47: 569-574.
- Jacoby VL, Autry A, Jacobson G, et al. Nation- wide use of laparoscopic hysterectomy compared with abdominal and vaginal approaches. *Obstet Gynecol* 2009; 114:1041–1048.
- Jain N, Euler GL, Shefer A, Lu P, Yankey D and Markowitz L. Human papillomavirus (HPV) awareness and vaccination initiation among women in the United States, National Immunization Survey-Adult. *Prev Med* 2009; 5:426-431.
- Javan R, Zeman MN. A prototype educational model for hepatobiliary interventions: unveiling the role of graphic designers in medical 3D printing. *J Digit Imaging* 2018; 31:133-143.
- Jayaprakasan K, Hilwah N, Kendall NR, Hopkisson JF, Campbell BK, Johnson IR. Does 3D ultrasound offer any advantage in the pretreatment assessment of ovarian reserve and prediction of outcome after assisted reproduction treatment? *Hum Reprod* 2007; 22:1932-1941.
- Jeronimo J, Schiffman M. Colposcopy at a crossroads. *Am J Obstet Gynecol* 2006; 195:349-353.
- Jiang T, Yuan Q, Zhou Q, et al. Do endometrial lesions require removal? A retrospective study. *BMC Womens Health* 2019; 19:61.
- Jin Z, Ogata S, Tamura G, Katayama Y, Fukase M, Yajima M. Carcinosarcomas (malignant mullerian mixed tumors) of the uterus and ovary: a genetic study with special reference to histogenesis. *Int J Gynecol Pathol* 2003; 22:368-373.
- Kaijser J, Bourne J, Valentin L, Sayasneh A, Van Holsbeke C, Vergote I. Improving strategies for diagnosing ovarian cancer: a summary of the International Ovarian Tumour Analysis (IOTA) studies. *Ultrasound Obstet Gynaecol* 2013; 41:9–20.

- Kalincsák J, Göcze P, Bódis J et al. Multimodal treatment of malignant mixed Müllerian tumor. *Orv Hetil* 2018; 159:741-747.
- Kalmantis K, Papageorgiou T, Rodolakis A et al. The role of three-dimensional (3D) sonography and 3D power Doppler in the preoperative assessment of borderline ovarian tumors. *Eur J Gynecol Oncol* 2007; 83:81-85.
- Karim, JN, Roberts NW, Salomon LJ, Papageorghiou AT. Systematic review of first-trimester ultrasound screening for detection of fetal structural anomalies and factors that affect screening performance. *Ultrasound Obstet Gynecol* 2017; 50: 429-441.
- Kaunitz AM, Bissonnette F, Monteiro I, et al. Levonorgestrel-releasing intrauterine system or medroxyprogesterone for heavy menstrual bleeding: a randomized controlled trial. *Obstet Gynecol* 2010; 116:625-632.
- Kean SL, Altman AD. Uterine Inversion as a result of a large prolapsed carcinosarcoma of the uterus. *J Obstet Gynaecol Can* 2019; pii: S1701-2163(18)30902-2. doi: 10.1016/j.jogc.2018.11.007.
- Kernochan LE, Garcia RL. Carcinosarcomas (malignant mixed Müllerian tumor) of the uterus: advances in elucidation of biologic and clinical characteristics. *J Natl Compr Canc Netw* 2009; 7:550-556.
- Kisaakye E, Namakula J, Kihembo C, Kisakye A, Nsubuga P, Babirye JN. Level and factors associated with uptake of human papillomavirus infection vaccine among female adolescents in Lira District, Uganda. *Pan Afr Med J* 2018;31:184 doi:10.11604/pamj.2018.31.184.14801.
- Kitchener HC, Almonte M, Wheeler P, Desai M, Gilham C, Bailey A. HPV testing in routine cervical screening: cross sectional data from the ARTISTIC trial. *Br J Cancer* 2006; 95:56–61.
- Kops NL, Hohenberger GF, Bessel M, et al. Knowledge about HPV and vaccination among young adult men and women: Results of a national survey. *Papillomavirus Res* 2019; 7:123–128.
- Kudla MJ, Timor-Trisch IE, Hope JM et al. Spherical tissue sampling in 3-dimensional power Doppler angiography: new approach for evaluation of ovarian tumors. *J Ultrasound Med* 2008; 27:425-433.
- Kupesic S, Kurjak A. Ultrasound and Doppler assessment of uterine anomalies. In: Kupesic S, de Ziegler D, eds. *Ultrasound and infertility*. Pearl River, NY: Parthenon 2000.
- Kurjak A, Kupesic S, Banovic I, Hafner T, Kos M. The study of morphology and circulation of early embryo by three-dimensional ultrasound and power Doppler. *J Perinat Med* 1999; 27:145–157.
- Kurjak A, Miskovic B, Stanojevic M, et al. New scoring system for fetal neurobehavior assessed by three and four-dimensional sonography. *J Perinat Med* 2008; 36:73–81.
- Kyei-Mensah A, Maconochie N, Zaidi J, Pittrof R, Campbell S, Tan SL. Transvaginal three-dimensional ultrasound: accuracy of ovarian follicular volume measurement. *Fertil Steril* 1996; 65:371-376
- Kyrgiou M, Koliopoulos G, Martin-Hirsch P, Arbyn M, Prendiville W, Paraskeva E. Obstetric outcomes after conservative treatment for intraepithelial or early invasive cervical lesions: systematic review and meta-analysis. *Lancet* 2006; 367:489–498.

- Laberge P, Leyland N, Murji A et al. Endometrial ablation in the management of abnormal uterine bleeding. *J Obstet Gynaecol Can* 2015; 37:362-379.
- Lazcano-Ponce E, Lorincz AT, Cruz-Valdez A, Salmerón J, Uribe P, Velasco-Mondragón E. Self-collection of vaginal specimens for human papillomavirus testing in cervical cancer prevention (MARCH): a community-based randomised controlled trial. *Lancet* 2011; 378: 1868–1873.
- Lee EJ, Han JH, Ryu HS. Polypoid adenomyomas: sonohysterographic and color Doppler findings with histopathologic correlation. *J Ultrasound Med* 2004; 23:1421-1429.
- Lee SM, Suh DH, Kim SY et al. Antenatal prediction of neonatal survival in sacrococcygeal teratoma. *J Ultrasound Med* 2018; 37:2003-2009.
- Lee W, Goncalves LF, Espinoza J, Romero R. Inversion mode: a new volume tool for 3-dimensional sonography. *J Ultrasound Med* 2005; 24: 201 - 207.
- Leeson S. Advances in colposcopy: new technologies to challenge current practice. *Eur J Obstet Gynecol Reprod Biol* 2014; 182:140-145.
- Lethaby A, Hickey M. Endometrial destruction techniques for heavy menstrual bleeding: a Cochrane review. *Hum. Reprod* 2002; 17:2795–2806.
- Liu CR, Liang H, Zhang X, et al. Effect of an educational intervention on HPV knowledge and attitudes towards HPV and its vaccines among junior middle school students in Chengdu, China. *BMC Public Health* 2019;19:488<https://doi.org/10.1186/s12889-019-6823-0>
- Louwers JA, Zaal A, Kocken M et al. The performance of Dynamic Spectral Imaging colposcopy depends on indication for referrals. *Gynecol Oncol* 2015; 139:452-457.
- Louwers, JA, Kocken, M, ter Harmsel, WA, Verheijen, RH. Digital colposcopy: ready for use? An overview of literature. *BJOG* 2009; 116:220-229.
- Love GD, Tanjasiri SP. Using entertainment-education to promote cervical cancer screening in Thai women. *J Cancer Educ* 2012; 27:585-590
- Ludwin A, Ludwin I, Pityński K, Banas T, Jach R. Role of morphologic characteristics of the uterine septum in the prediction and prevention of abnormal healing outcomes after hysteroscopic metroplasty. *Hum Reprod* 2014; 29:1420-1431.
- Ma KK, Tsui PZ, Wong WC, Kun KY, Lo LS, Ng TK. Laparoscopic management of large ovarian cysts: more than cosmetic considerations. *Hong Kong Med J* 2004; 10:139-141.
- MacKenzie IZ, Naish C, Rees CM, Manek S. Why remove all cervical polyps and examine them histologically? *BJOG* 2009; 116:1127-1129.
- Maier C, Maier T, Neagu CE, Vlădăreanu R. “Romanian adolescents' knowledge and attitudes towards human papillomavirus infection and prophylactic vaccination”. *Eur J Obstet Gynecol Reprod Biol* 2015; 195:77-82.
- Makkonen P, Sarkeala T, Anttila A, et al. Impact of organized and opportunistic Pap testing on the risk of cervical cancer in young women – A case-control study from Finland. *Gynecol Oncol* 2017; 147: 601 – 606.
- Makris N, Stefanidis K, Loutradis D, et al. The incidence of retained fetal bone revealed in 2000 diagnostic hysteroscopies. *JSLS* 2006; 10:76-77.
- Mallick R, Odejinmi F. Pushing the boundaries of laparoscopic myomectomy: a comparative analysis of peri-operative outcomes in 323 women undergoing

- laparoscopic myomectomy in a tertiary referral centre. *Gynecol Surg* 2017; 14:22.
- Martin-Hirsch PP, Paraskevaidis E, Bryant A, Dickinson HO. Surgery for cervical intraepithelial neoplasia. *Cochrane Database Syst Rev* 2013;(12):CD001318. <https://doi.org/10.1002/14651858.CD001318.pub2>.
 - Martinez-Maestre MA, Gambadauro P, Gonzalez- Cejudo C, et al. Total laparoscopic hysterectomy with and without robotic assistance: a prospective controlled study. *Surg Innov* 2014; 21:250–255.
 - Maselli KM, Badillo A. Advances in fetal surgery. *Ann Transl Med* 2016;4:394. doi: 10.21037/atm.2016.10.34.
 - Matteson K, Scott D, Raker C, Clark M. The menstrual bleeding questionnaire: development and validation of a comprehensive patient-reported outcome instrument for heavy menstrual bleeding. *Br J Obstet Gynaecol* 2015; 122:681–689.
 - Maymon R, Herman A, Ariely S, Dreazen E, Buckovsky I, Weinraub Z. Three-dimensional vaginal sonography in obstetrics and gynecology. *Hum Reprod Update* 2000; 6:475–484.
 - Mitra A, MacIntyre DA, Marchesi JR, et al. The vaginal microbiota, human papillomavirus infection and cervical intraepithelial neoplasia: what do we know and where are we going next? *Microbiome* 2016; 4:58<https://doi.org/10.1186/s40168-016-0203-0>.
 - Moore J, Copley S, Morris J, Lindsell D, Golding S, Kennedy S. A systematic review of the accuracy of ultrasound in the diagnosis of endometriosis. *Ultrasound Obstet Gynecol* 2002; 20:630-634.
 - Moscicki AB, Shiboski S, Hills NK, et al. Regression of low-grade squamous intra epithelial lesions in young women. *Lancet* 2004; 364: 1678–1683.
 - Moss EL, Arbyn M, Dollery E et al. European Federation of Colposcopy quality standards Delphi consultation. *Eur J Obstet Gynecol Reprod Biol* 2013; 170: 255-258.
 - Mulford JS, Babazadeh S, Mackay N. Three-dimensional printing in orthopaedic surgery: review of current and future applications. *ANZ J Surg* 2016; 86:648–653.
 - Munro MG, Critchley HO, Fraser IS. The FIGO systems for nomenclature and classification of causes of abnormal uterine bleeding in the reproductive years: who needs them? *Am J Obstet & Gynecol* 2012; 207: 259–265.
 - Munroe MG. Endometrial ablation: where have we been? Where are we going? *Clin Obstet Gynecol* 2006; 49:736–766.
 - Murphy A, Platt LD. First-trimester diagnosis of body stalk anomaly using 2- and 3-dimensional sonography. *J Ultrasound Med* 2011; 30:1739-1743.
 - Mzarico E, Gómez-Roig D, Guirado L, Lorente N, Gonzalez-Bosquet E. “Relationship between smoking, HPV infection, and risk of cervical cancer”. *Eur J Gynaecol Oncol* 2015; 36: 677-680.
 - Naftalin J, Jurkovic D. The endometrial-myometrial junction: a fresh look at a busy crossing. *Ultrasound Obstet Gynecol* 2009; 34:1-11
 - Namazov A, Gerner O, Ben-Arie A et al. Endometrial polyp size and the risk of malignancy in asymptomatic postmenopausal women. *Obstet Gynaecol Can* 2019; 41:912-915.
 - National Institute of Health and Care Excellence (NICE). Heavy menstrual bleeding. National Institute for Health and Care Excellence (2018) Heavy

- menstrual bleeding (NICE Guideline 88). <https://www.nice.org.uk/guidance/conditions-and-diseases/gynaecological-conditions/heavy-menstrual-bleeding>.
- Nebeker J, Nelson R. Imaging of sound speed reflection ultrasound tomography. *Journal of Ultrasound in Medicine* 2012; 31: 1389-404.
 - Nelson EJ, Maynard BR, Loux T, Fatla J, Gordon R, Arnold LD. The acceptability of self- sampled screening for HPV DNA: a sysytematic revies and meta-analysis. *Sex Transm Infect* 2017; 93:53-61.
 - Nezhat CR, Burrell MO, Nezhat FR, et al. Laparoscopic radical hysterectomy with paraaortic and pelvic node dissection. *Am J Obstet Gynecol* 1992; 166:864–865.
 - Nielsen A, Munk C, Liaw KL, Kjaer SK. “Awareness of human papillomavirus in 23 000 Danish men from the general male population”. *Eur J Cancer Prev* 2009; 18: 236-239.
 - Nikitichev DI, Barburas A, McPherson K, Mari JM, West SJ, Desjardins AE. Construction of 3-dimensional printed ultrasound phantoms with wall-less vessels. *J Ultrasound Med* 2016; 35:1333-1339.
 - Numnum TM, Kirby TO, Leath CA 3rd, et al. A prospective evaluation of “see and treat” in women with HSIL Pap smear results: is this an appropriate strategy? *J Low Genit Tract Dis* 2005; 9: 2-6.
 - O’Rahilly. Making planes plain. *Clin Anat* 1997; 10:128-129.
 - Okamoto Y, Tanaka YO, Tsunoda H, Yoshikawa H, Minami M. Malignant or borderline mucinous cystic neoplasms have a larger number of loculi than mucinous cystadenoma: a retrospective study with MR. *J Magn Reson Imaging* 2007; 26:94-99.
 - Oliveira FG, Abdelmassih VG, Diamond MP, Dozortsev D, Melo NR, Abdelmassih R. Impact of subserosal and intramural uterine fibroids that do not distort the endometrial cavity on the outcome of in vitro fertilization intracytoplasmic sperm injection. *Fertil Steril* 2004; 81:582-587.
 - Onderoglu LS, Yarali H, Gultekin M, Katlan D. Endometrial osseous metaplasia: an evolving cause of secondary infertility. *Fertil Steril* 2008;90:2013.e9-11 doi: 10.1016/j.fertnstert.2008.01.001.
 - Papadopoulos NP, Magos A. First-generation endometrial ablation: rollerball vs loop vs laser. Best Practice and Research. *Clin Obstet Gynaecol* 2007; 21: 915–929.
 - Parente RC, Patriarca MT, de Moura Neto RS, et al. Genetic analysis of the cause of endometrial osseous metaplasia. *Obstet Gynecol* 2009; 114:1103-1109.
 - Paul C, Zosmer N, Jurkovic D, Nicolaidis K. A case of body stalk anomaly at 10 weeks of gestation. *Ultrasound Obstet Gynecol* 2001; 17:157.
 - Păvăleanu I, Gafițanu D, Ioanid N, Grigore M. Preliminary results of the first cervical cancer-screening programme in the North Eastern region of Romania. *J Med Screen* 2018; 25:162-165.
 - Penta MA, Băban A. Dangerous agent or savior? HPV vaccine representations on online discussion forums in Romania. *Int J Behav Med* 2014; 21:20-28.
 - Peres Fagundes PA, Chapon R, Olsen PR, Schuster AK, Mattia MMC, Cunha-Filho JS. Evaluation of three-dimensional SonoAVC ultrasound for antral follicle count in infertile women: its agreement with conventional two-

- dimensional ultrasound and serum levels of anti-Müllerian hormone. *Reprod Biol Endocrinol* 2017;15:96 doi: 10.1186/s12958-017-0314-x.
- Petry KU, Nieminen PJ, Leeson SC, Bergeron C, Redman C. 2017 update of the European Federation for Colposcopy (EFC) performance standards for the practice of colposcopy. *Eur J Obstet Gynecol Reprod Biol* 2018; 224:137-141.
 - Petry, KU. HPV and cervical cancer. *Scand J Clin Lab Investig* 2014; 74: 59-62.
 - Pooh RK, Shiota K, Kurjak A. Imaging of the human embryo with magnetic resonance imaging microscopy and high-resolution transvaginal 3-dimensional sonography: Human embryology in the 21st century. *Am J Obstet Gynecol* 2001; 204:77:1-16.
 - Pretorius DH, Nelson TR. Three-dimensional ultrasound. *Ultrasound Obstet. Gynecol* 1995; 5:219–221.
 - Propst AM, Hill JA. Anatomic factors associated with recurrent pregnancy loss. *Semin Reprod Med* 2000; 18:341-350.
 - Qiu JJ, Liu MH, Zhang ZX, Chen LP, Yang QC, Liu HB. Transvaginal color Doppler sonography predicts ovarian interstitial fibrosis and microvascular injury in women with ovarian endometriotic cysts. *Acta Obstet Gynecol Scand* 2012; 91:605-612.
 - Racey CS, Withrow DR, Gesink D. Self-collected HPV Testing Improves Participation in Cervical Cancer Screening: A Systematic Review and Metaanalysis. *Can J Public Health* 2013; 104:159-166.
 - Raga F, Castillo JC, Bonilla F Jr, Bonilla-Musoles F. HDlive ultrasound images in assisted reproduction treatment. *Reprod Biomed Online* 2013; 26:269-271.
 - Raine-Fenning N, Jayaprakasan K, Clewes J et al. SonoAVC: a novel method of automatic volume calculation. *Ultrasound Obstet Gynecol* 2008; 31: 691-696.
 - Ramirez PT, Frumovitz M, Pareja R, Lopez A, Vieira MA, Ribeiro R. Phase III randomized trial of laparoscopic or robotic vs. abdominal radical hysterectomy in patients with early-stage cervical cancer: LACC trial. *Gynecol Oncol* 2018; 149:245 10.1016/j.ygyno.2018.04.552.
 - Ranga R, Rai S, Kumari A et al. A comparison of the strength of association of Reid colposcopic index and Swede score with cervical histology. *J Low Genit Tract Dis* 2017; 21:55-58.
 - Rees I, Jones D, Chen H, Macleod U. Interventions to improve the uptake of cervical cancer screening among lower socioeconomic groups: A systematic review. *Prev Med* 2018; 111:323-335.
 - Rexhepi M, Trajkovska E, Ismaili H, Besimi F, Rufati N. Primary fallopian tube carcinoma: A case report and literature review. *Open Access Maced J Med Sci* 2017; 5:344–348.
 - Rivara A, James AH. Managing heavy menstrual bleeding in women at risk of thrombosis. *Clin Obstet Gynecol* 2018; 61:250-259.
 - Rodgers EB, Monteagudo A, Santos R, Greco A, Timor-Tritsch IE. Diagnosis of pentalogy of Cantrell using 2- and 3-dimensional sonography. *J Ultrasound Med* 2010; 29:1825–1828.
 - Ronco G, Dillner J, Elfstrom KM, Tunesi S, Snijders PJ, Arbyn M. International HPV screening working group. Efficacy of HPV-based screening

- for prevention of invasive cervical cancer: follow-up of four European randomized controlled trials. *Lancet* 2014; 383:524–532.
- Russo R, D'Armiento M, Angrisani P, Vecchione R. Limb body wall complex: a critical review and a nosological proposal. *Am J Med Genet* 1993; 47:893–900.
 - Rustico MA, Mastromatteo C, Grigio M et al. Two-dimensional vs. two- plus four-dimensional ultrasound in pregnancy and the effect on maternal emotional status: A randomized study. *Ultrasound Obstet Gynecol* 2005; 25: 468–472.
 - Sadan O, Yarden H, Schejter E, Bilevsky E, Bachar R, Lurie S. Treatment of highgrade squamous intraepithelial lesions: a "see and treat" versus a three-step approach. *Eur J Obstet Gynecol Reprod Biol* 2007; 131:73–75.
 - Salem HA. Laparoscopic excision of large ovarian cysts. *J Obstet Gynecol Res* 2002; 28: 290–294.
 - Sankaranarayanan R, Budukh AM, Rajkumar R. Effective screening programmes for cervical cancer in low- and middle-income developing countries. *Bull World Health Organ* 2001; 79:954–962.
 - Saraiya UB. Preventable but not prevented: the reality of cervical cancer. *J Obstet Gynecol Res* 2003; 29:351–359.
 - Saravelos SH, Cocksedge KA, Li TC. Prevalence and diagnosis of congenital uterine anomalies in women with reproductive failure: a critical appraisal. *Hum Reprod* 2008; 14:415–429.
 - Savelli L, Manuzzi L, Di Donato N, et al. Endometriosis of the abdominal wall: ultrasonographic and Doppler characteristics. *Ultrasound Obstet Gynecol* 2012; 39:336–340.
 - Scheffer GJ, Broekmans JMJ, Bancsi J, Habbema JD, Looman CW, te Velde ER. Quantitative transvaginal two- and three-dimensional sonography of the ovaries: reproducibility of antral follicle counts. *Ultrasound Obstet Gynecol* 2002; 20: 270–275.
 - Segnan N, Senore C, Giordano L, Ponti A, Ronco G. Promoting participation in a population screening program for breast and cervical cancer: a randomized trial of different invitation strategies. *Tumori* 1998; 84:348–353.
 - Shaw RW, Symonds IM, Tamizian O, Chaplain J, Mukhopadhyay S. Randomised comparative trial of thermal balloon ablation and levonorgestrel intrauterine system in patients with idiopathic menorrhagia. *Aust N Z J Obstet Gynaecol* 2007; 47:335–340.
 - Sherman SM, Bartholomew K, Denison HJ. Knowledge, attitudes and awareness of the human papillomavirus among health professionals in New Zealand. *PLoS ONE* 2018; 13:e0197648. <https://doi.org/10.1371/journal.pone.0197648>.
 - Sherman SM, Cohen CR, Denison HJ, Bromhead C, Patel H. A survey of knowledge, attitudes and awareness of the human papillomavirus among healthcare professionals across the UK. *Eur J Public Health*. 2019 pii: ckz113. doi: 10.1093/eurpub/ckz113.
 - Socolov G, Anton G, Anton E, et al.: "Human papilloma virus distribution in patients from Moldova region". *Gineco.ro* 2008; 4: 248–252.
 - Sossauer G, Zbinden M, Tebeu PM, et al. Impact of an educational intervention on women's knowledge and acceptability of human

- papillomavirus self-sampling: a randomized controlled trial in Cameroon. *PLoS One* 2015;10(2):e0117927.
- Soutter WP, Diakomanolis E, Lyons D et al. Dynamic spectral imaging: improving colposcopy. *Clin Cancer Res* 2009; 15:1814-1820.
 - Spadea T, Bellini S, Kunst A, Stirbu I, Costa G. The impact of interventions to improve attendance in female cancer screening among lower socioeconomic groups: a review. *Prev Med* 2010; 50:159–164.
 - Spencer JC, Louie M, Moulder JK et al. Cost-effectiveness of treatments for heavy menstrual bleeding. *Am J Obstet Gynecol* 2017; 217:574.e1-574.e9.
 - Starr RA, Wagstaff NV. Implementing a surgical skills training program. *Obstet Gynecol Clin North Am* 2006; 33:247-258.
 - Steiner H, Gregg AR, Bogner G, Graf AH, Weiner CP, Staudach A. First trimester three-dimensional ultrasound volumetry of the gestational sac. *Arch Gynecol Obstet* 1994; 255:165-170.
 - Swamy R, Embleton N, Hale J. Sacrococcygeal teratoma over two decades: birth prevalence, prenatal diagnosis and clinical outcomes. *Prenat Diagn* 2008; 28:1048-1051.
 - Syngelaki A, Chelemen T, Dagklis T, Allan L, Nicolaides KH. Challenges in the diagnosis of fetal non-chromosomal abnormalities at 11–13 weeks. *Prenatal Diagnosis* 2011; 31: 90–102.
 - Tabrizi SN, Brotherton JM, Kaldor JM et al. Fall in human papillomavirus prevalence following a national vaccination program. *J Infect Dis* 2012; 206:1645–1651.
 - Tavasoli SM, Pefoyo AJ, Hader J, Lee A, Kupets R. Impact of invitation and reminder letters on cervical cancer screening participation rates in an organized screening program. *Prev Med* 2016; 88:230-236.
 - Tebeu PM, Major AL, Rapiti E et al. The attitude and knowledge of cervical cancer by Cameroonian women; a clinical survey conducted in Maroua, the capital of Far North Province of Cameroon. *Int J Gynecol Cancer* 2008; 18: 761-765.
 - Temkin SM, Hellmann M, Lee YC, Abulafia O. Early-stage carcinosarcoma of the uterus: the significance of lymph node count. *Int J Gynecol Cancer* 2007; 17:215-219.
 - Thippeveeranna C, Mohan SS, Singh LR, Singh NN. Knowledge, attitude and practice of the pap smear as a screening procedure among nurses in a tertiary hospital in north eastern India. *Asian Pac J Cancer Prev* 2013; 14:849-852.
 - Tidy JA, Brown BH, Healey TJ et al. Accuracy of detection of high-grade cervical intraepithelial neoplasia using electrical impedance spectroscopy with colposcopy. *BJOG* 2013; 120:400–411.
 - Timor-Trisch IE, Peisner DB, Raju S. Sonoembryology: an organ-oriented approach using a high- frequency vaginal probe. *J Clin Ultrasound* 1990; 18:286-298.
 - Toptas T, Simsek T. Total laparoscopic versus open radical hysterectomy in stage IA2-IB1 cervical cancer: disease recurrence and survival comparison. *J Laparoendosc Adv Surg Tech A* 2014; 24:373–378.
 - Tota JE, Chevarie-Davis M, Richardson LA et al. Epidemiology and burden of hpv infection and related diseases: implications for prevention strategies. *Prev Med* 2011; 53:12–21.

- Tranberg M, Larsen MB, Mikkelsen EM, Svanholm H, Andersen B. Impact of opportunistic testing in a systematic cervical cancer screening program: a nationwide registry study. *BMC Public Health* 2015; 15:681doi: 10.1186/s12889-015-2039-0.
- Turkgeldi E, Urman B, Ata B. Role of three-dimensional ultrasound in gynecology. *J Obstet Gynaecol India* 2015;65:146-154.
- Ursu RG, Onofriescu M, Nemescu D, Iancu LS. HPV prevalence and type distribution in women with or without cervical lesions in the Northeast region of Romania. *Virol J* 2011; 22:558doi: 10.1186/1743-422X-8-558.
- Van Allen MI, Curry C, Gallagher L. Limb body wall complex: I.Pathogenesis. *Am J Med Genet* 1987; 28:529-548.
- Van Holsbeke C, Van Calster B, Guerriero S et al. Endometriomas: their ultrasound characteristics. *Ultrasound Obstet Gynecol* 2010; 35:730-740.
- Verdoodt F, Jentschke M, Hillemanns P, Racey CS, Snijders PJ, Arbyn M. Reaching women who do not participate in the regular cervical cancer screening programme by offering self-sampling kits: a systematic review and meta-analysis of randomised trials. *Eur J of Cancer* 2015; 51:2375–2385.
- Vislo AG, Advincula AP. Robotic Gynecologic Surgery. *Obstet Gynecol* 2008; 112: 1369-1384.
- Viviano M, Catarino R, Jeannot E et al. Self-sampling to improve cervical cancer screening coverage in Switzerland: a randomised controlled trial. *Br J Cancer* 2017; 116:1382-1388.
- Vlastos AT, Richards-Kortum R, Zuluaga A, Follen M. New approaches to cervical cancer screening. *Contemporary Ob/Gyn* 2002; 47:87–107.
- Voidazan S, Tarcea M, Morariu SH, Grigore A, Dobreanu M. Human Papillomavirus vaccine - knowledge and attitudes among parents of children aged 10-14 years: a cross-sectional study, Tîrgu Mureş, Romania. *Cent Eur J Public Health* 2016; 24:29-38.
- Von Karsa L, Arbyn A, De Vuyst H et al. Executive summary in European Guidelines for Quality Assurance in Cervical Cancer Screening, 2nd ed - Supplements; *Office for Official Publications of the European Union: Luxembourg*, 2015; pp. XIII–XXIV.
- Walker JL, Piedmonte MR, Spirtos NM, et al. Laparoscopy compared with laparotomy for comprehensive surgical staging of uterine cancer: Gynecologic Oncology Group Study LAP2. *J Clin Oncol* 2009; 27:5331–5336.
- Waller J, McCaffery K, Forrest S et al. Acceptability of unsupervised HPV self-sampling using written instructions, *J Med Screening* 2006; 13:208 – 213.
- Warner P, Critchley HO, Lumsden MA, Campbell-Brown M, Douglas A, Murray G. Referral for menstrual problems: cross sectional survey of symptoms, reasons for referral and management. *Br Med Journal* 2001; 323:2-8.
- Waxman AG. Guidelines for cervical cancer screening, history and scientific rationale. *Clin Obstet Gynecol* 2005; 48: 77-97.
- Wei L, Xie X, Liu J. Efficacy of quadrivalent human papillomavirus vaccine against persistent infection and genital disease in Chinese women: A randomized, placebo-controlled trial with 78-month follow-up. *Vaccine* 2019; 37:3617-3624.

- Wiechec M, Knafel A, Nocun A, Wiercinska E, Ludwin A, Ludwin I. What are the most common first-trimester ultrasound findings in cases of Turner syndrome? *J Matern Fetal Neonatal Med* 2017; 30:1632-1636.
- Williams AP, Marayati R, Beierle EA. Pentalogy of Cantrell. *Semin Pediatr Surg* 2019; 28:106-110.
- Woelfer B, Salim R, Banerjee S, Elson J, Regan L, Jurkovic D. Reproductive outcomes in women with congenital uterine anomalies detected by three-dimensional ultrasound screening. *Obstet Gynecol* 2001; 98:1099-1103.
- Wokoma TT, Adum VL, Gbolade BA. Retained fetal bones masquerading as an intrauterine device with missing threads. *Eur J Contracept Reprod Health Care* 2010; 15:213-215.
- Wolff EF, Wolff AB, Hongling Du, et al. Demonstration of multipotent stem cells in the adult human endometrium by in vitro chondrogenesis. *Reprod Sci* 2007; 14:524-533.
- Wozniak S, Czuczwar P, Szkodziak P et al. Elastography improves the accuracy of ultrasound in the preoperative assessment of abdominal wall endometriosis. *Ultraschall Med* 2015; 36:623-629
- Zakham F, Bazoui H, Akrim M, Lemrabet S, Lahlou O, Elmezibri M et al. Evaluation of conventional molecular diagnosis of *Mycobacterium tuberculosis* in clinical specimens from Morocco. *J Infect Dev Ctries* 2012; 6:40-45.
- Zamudio-Andrade A, Zepeda-Zaragoza J, Rodríguez-Blanco B, Tenorio-Marañón R. Evaluación del Papanicolaou y la colposcopia en el diagnóstico de la infección por el virus del papiloma humano. *Rev Facultad Med UNAM* 2001; 44:5-7.