

Anatomical evidence regarding the existence of *sustentaculum facies*

L. L. FRÂNCU, DELIA HÎNGANU, M. V. HÎNGANU

*Department of Anatomy,
 "Grigore T. Popa" University of Medicine and Pharmacy, Iassy*

Abstract

The face, seen as a unitary region is subject to the gravitational force. Since it is the main relational and socialization region of each individual, it presents unique ways of suspension. The elevation system of the face is complex, and it includes four different elements: the continuity with the epicranial fascia, the adhesion of superficial structures to the peri- and inter-orbital mimic muscles, ligaments adhesions and fixing ligaments of the superficial layers to the zygomatic process, and also to the facial fat pad. Each of these four elements were evaluated on 12 cephalic extremities, dissected in detail, layer by layer, and the images were captured with an informatics system connected to an operating microscope. The purchased mesoscopic images revealed the presence of a superficial musculo-aponeurotic system (SMAS) through which the anti-gravity suspension of the superficial facial structures become possible. This system acts against face aging and all four elevation structures form what the so-called *sustentaculum facies*. The participation of each of the four anatomic components and their approach in the facial rejuvenation surgeries are here in discussion.

Keywords: aging face, face anatomy, SMAS, *sustentaculum facies*.

✉ Introduction

Structurally, the soft tissue of the face is disposed into a series of concentric layers: skin, subcutaneous fat tissue, superficial fascia, muscles of facial expressions, deep fascia (parotidomaseptic), the plan of the facial nerve, the plan of the parotid duct and buccal fat [1]. Superficial fascia covers the muscles of the facial expressions (platysma, orbicularis oculi, and zygomaticus major and minor) and deep facial fascia, the subsistence of the facialize cervical fascia, easily identifiable, covers and protects the terminal branches of the facial nerve located subjacent to fascia at the cheek level.

There are two types of spatial relations between superficial and deep fascia: in some regions facial plans are separated by an areolar plan, in other regions the two fasciae are intimately adherent to each other through a series of dense fibrous attachments.

In the last decades, the easily improving and increasing accessibility to the facial rejuvenation techniques, requested intensified studies regarding the superficial facial structure. Thereby, Tessier P [2] proposed the term of musculo-aponeurotic superficial system (SMAS) to describe an anatomical and surgical structure, which is distinguished from the platysma muscle. Its Princeps description was made by Mitz V and Peyronie M (1976) in the parotid and cheek regions (buccal after NA) [3], which led to some controversy between the surgeons and anatomists, this structure being initially recognized only by the surgeons who use it in various facelift techniques [1, 2, 4, 5].

The superficial layers of the face are under the permanent action of gravitational force in a unique manner, on the one hand due to the bipedal resort, on the other hand as an expression of the human specific functions (mimics, socialization).

The microscopic anatomy and the biomechanics of the superficial facial surface structure include a set of shapes which interpose to the gravitational force and to the aging and “falling” of the face, which consist of the continuity with the epicranial fascia, adhesions and fixing perizygomatic fixation ligaments, the adhesion of the superficial structures to the peri- and inter-orbital muscles, and the presence of fibro-adipose tissue regionally organized, with a role in facilitating/stop dragging during the contractions [1, 6, 7].

In this paper, we are intending to identify the anatomical formations, which can be defined as *sustentaculum facies*, with an important function in supporting the superficial layers and the possibilities of various techniques in rhytidectomy.

✉ Materials and Methods

For this study, we used 12 cephalic extremities, which were meticulously dissected in the Anatomy Institute at “Grigore T. Popa” University of Medicine and Pharmacy, Iassy, Romania. Each specimen was previously preserved in formaldehyde.

Dissections were performed layer by layer started with preauricular region and ascending toward the internal end of the superciliary arches. On each stage of dissection mesoscopic images were captured by using the 62 Kaps SOM operating microscope. On the dissection specimen, the following superimposed layers were identified, in different topographic locations (frontal lateral, inferior temporal, preparotid, premasseteric, infraorbital): dermo-epidermic, subcutaneous fat tissue, superficial fascia, superficial muscular layer, deep fascia, and periosteum and deep musculoglandular items. The conclusive aspects were acquired, examined and further processed to remark the regional stratigraphic differences.

Simultaneously we have conducted microanatomic studies that were made by collecting and interpreting the tissue sample taken from the studied specimens. We have collected all the soft tissues of the face, from skin to bone plane in the form of small blocks. The fragments collected were processed by paraffin technique and stained with Hematoxylin–Eosin and specific staining techniques of the muscular and connective tissue (van Gieson and Szekely).

Results

The occipital–galea aponeurosis–frontal–superficial temporal fascia–platysma–SMAS complex represents a functional unit which defines the individual faces; the facial aging is characterized by a sagging of the soft tissue due to the loss of elasticity, by the subcutaneous fat redistribution, sometimes also submuscular and by losing the capacity of contraction and dragging of the muscles facial expressions (Figure 1).

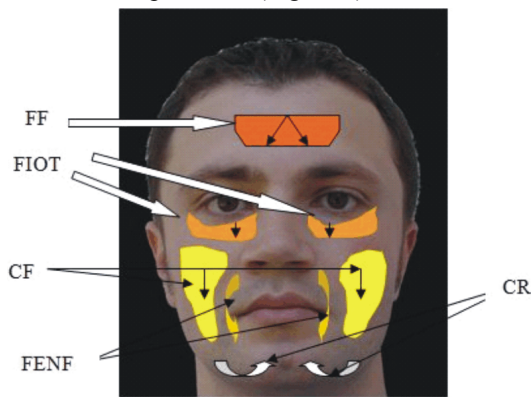


Figure 1 – *Systematization signs of aging face: Forehead fall (FF); Fall of infraorbital tissues (FIOT); Cheeks fall (CF); Fall and enlarge of nasolabial folds (FENF); Chin reduction (CR) – personal casuistry.*

The descending of the forehead can occur when the fixing system of the superciliary superficial structures becomes lax. Dissection shows that at this level are attached to deep facial skin the following: the superficial fascicles of the corrugator supercilii muscle, the orbicularis oculi and also the procerus between them (Figure 2).



Figure 2 – *Insertion of orbicularis oculi muscle and periorbital SMAS. Mesoscopic dissection specimen.*

The superciliary arches represent the limit between the face and the forehead; in this area, there is the junction between the superficial fascia of the frontal region and the musculo–aponeurotic system of the face. Alongside

these muscular transfascial attachments, beside them, there is a temporal ligament (temporofrontal), which is the superior continuation of SMAS at the level of the zygomatic processes (Figure 3).

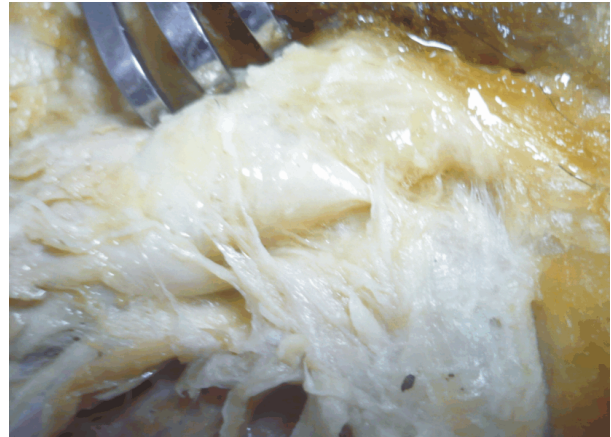


Figure 3 – *Ligamentary adhesions between SMAS, deep fascia and pericranium in temporal region. Mesoscopic dissection specimen.*

The dissection continued downward to the junction between the lower borders of the zygomatic arch with the pretragal region, then it recessive continued, following the same incision line like in the facelift surgery. The SMAS disposals in these regions were captured by the operator microscope.

We have observed that the anatomical pattern of the ligamentary fixation of the superficial fascia to the facial skeleton defines the boundaries, which divide the face into several regions, and also it marks the incision lines in surgery. Three of these, are parts of what is seen from the outside, such as cheek, lateral cheek, pre- and infra-zygomatic parts of the medial cheek, in addition to the other regions: the lower eyelid, the inferior temple, the superior eyelid and the forehead.

The infraorbital SMAS adhesion is a very powerful one, the inferior being limited by the insertion of the great zygomatic muscle and the superior limited by the orbit ledge (Figure 4), and separates the superior regions by the inferior regions of the face. The limit between forehead and face is very distinct at the level of the superficial fascia and it is marked by the SMAS's adhesion orbit aditus, due to the periorbital septum.

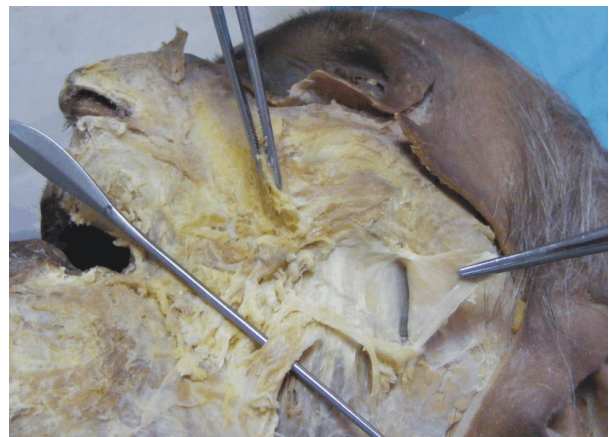


Figure 4 – *Limit between superior and inferior region of the face made by great zygomatic muscle. Mesoscopic dissection specimen.*

Although the SMAS is adherent to profound fascia of the orbital and frontal region and to the periosteum of frontal bone, through these adhesions it continues cranially with the superficial fascia (subgaleal) of the frontal region. Therewith, the lower limit of the face continues with the superficial cervical fascia (superficial fascia of platysma muscle) and form so an interconnected anatomical, functional and embryological unit. The fascia continues one the sided with the temporal one and infraorbital with the zygomatic region's fascia. The SMAS is adherent to the skin. The infraSMAS plan is connected to the profound layers not only by the adhesions but also by a cohesion tissue located between the SMAS and the profound fascia. The infraSMAS space is crossed by branches from the temporal, supraorbital and supratrochlear neurovascular bundles (Figures 5–7).

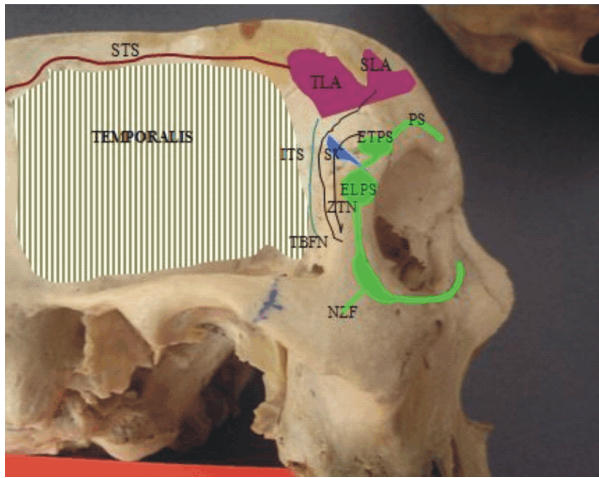


Figure 5 – Periorbital and temporal attachments with the most important neurovascular relations: anterior aspect on a collection skull. Temporal ligamentary adhesion (TLA), adhesion supraorbital ligamentary adhesion (SLA), superior temporal septum (STS), inferior temporal septum (ITS), periorbital septum (PS), extended thinned side of periorbital septum (ETPS), extended latero-orbital side of periorbital septum (ELPS), sentinel vessels (SV), temporal branches of facial nerve (TBFN), zygomaticotemporal nerve (ZTN), zygomaticofacial nerve (ZFN).

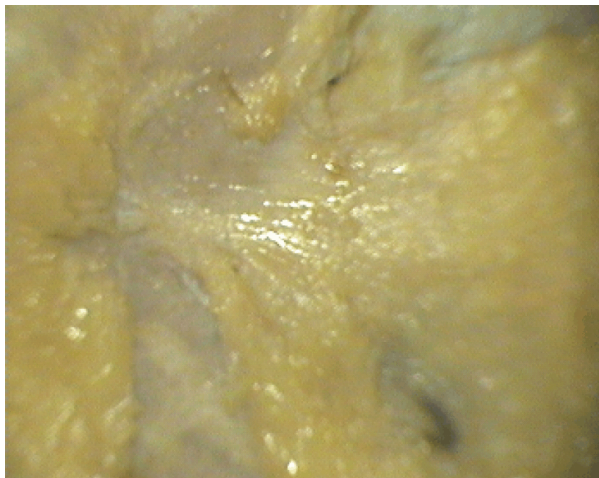

Figure 6 – Convergence of inferior temporal and zygomatic ligaments to the zygomatic process of frontal bone. Mesoscopic dissection specimen.

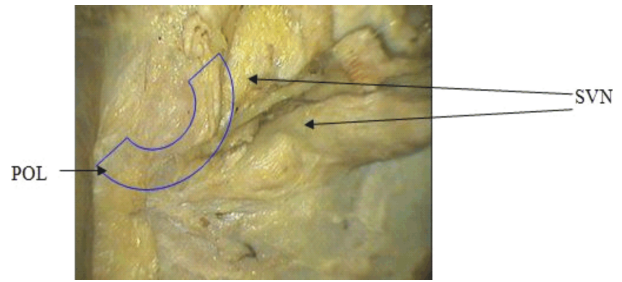


Figure 7 – Periorbital ligament (POL); superficial vessels and nerves (SVN) at temporal angle of the orbit. Mesoscopic dissection specimen.

The periorbital adhesions are hard, extensive, robust, and they are inserted directly to the periosteum but their disinsertion is almost impossible on the dissection specimen. As we have already shown, all the ligaments in the region including the zygomatic one converge towards them. So, together with the zygomatic ligament, they are the main anti-gravity mechanism of face suspension, but unlike the face, they have no elasticity. They are orientated towards those three axes of the space. Another extremely important inter-muscular link of this region is that on the external angle of the orbit, between the frontalis and orbicularis oculi muscles on one hand and the corrugator supercilii on the other hand (Figure 8).

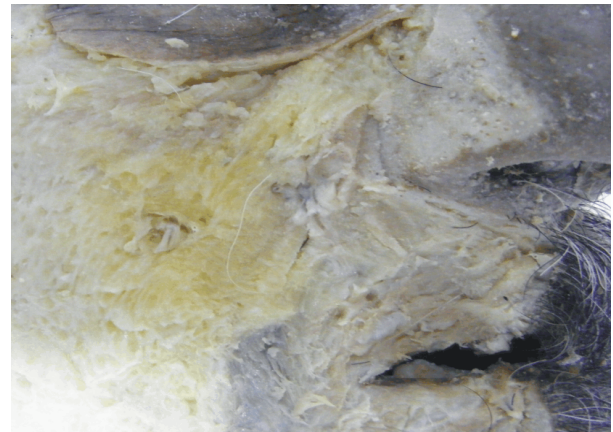


Figure 8 – Connection septa between orbicularis oculi muscle and dermis which cover large and rectangular adipose cells lobules. Mesoscopic dissection specimen.

This study shows that the cervicofacial SMAS is a continue fibromuscular lamina located between two fibro-adipose laminae, and these three overlapped structures establish different spatial regional relations. In the SMAS's structure, collagen fibers with different dimensions and topographic orientation are exceeding. The elastic fibers are consecutive less, even missing in some areas. The collagen fibers are orderly provisioned, on longitudinal and transverse plans, or they are losing their individually structure and forming a variety of shapes and dimensions slides, most evident in the modiolus (Figure 9).

The muscular fibers belong to the cutaneous superficial layer, which forms the SMAS, and they go on with conjunctive fibers (Figure 10). In some areas, they leave the SMAS and cross toward the osteoperiosteum plane.

The inferior border of the temporo-parietal fascia continues with the SMAS from the cheeks level and the anterior border continues with the orbicularis oculi and the frontal muscles. That is why the folding of the

temporoparietal fascia can increase the tension into the SMAS and orbicularis oculi and the frontal muscles in rhytidectomy.

Our microanatomical studies showed the reorganization of the collagen and elastic fibers meanwhile the aging processes, which results in their deformation with the elasticity reducing.

The existence of the collagen fibers of medium dimensions, orderly orientated, especially longitudinal (Figure 11) was observed in the specimens but there are also small-sized elastic fibers, concentrated in plots,

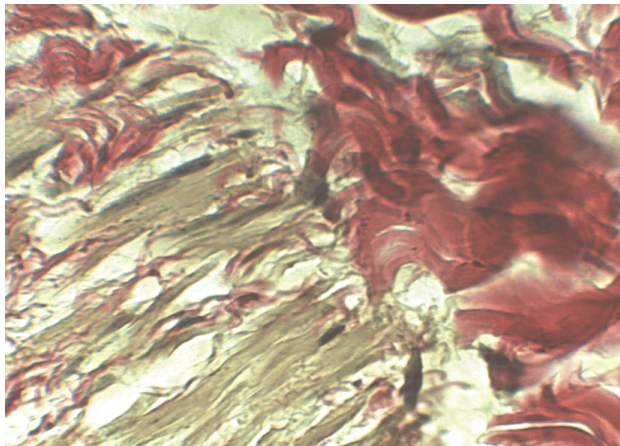


Figure 9 – The adherence of muscular fibers on SMAS, in zygomatic region (van Gieson staining, ×600).

which are the fixation fascicles, separated by large, full of fat spaces. The fragments collecting uninserted these fascicles from their subjacent osseous plans, conferring them a retracted and torsional aspect. Infraorbitally, there are connective microseptum between the *orbicularis oculi* muscle and the dermis (via SMAS) which overlap large, rectangular lobules of the fat cells.

Our studies revealed the decreasing and the fragmentation of the collagen and the elastic fibers from the SMAS structure consecutive with the increasing in the laxity (Figure 12).

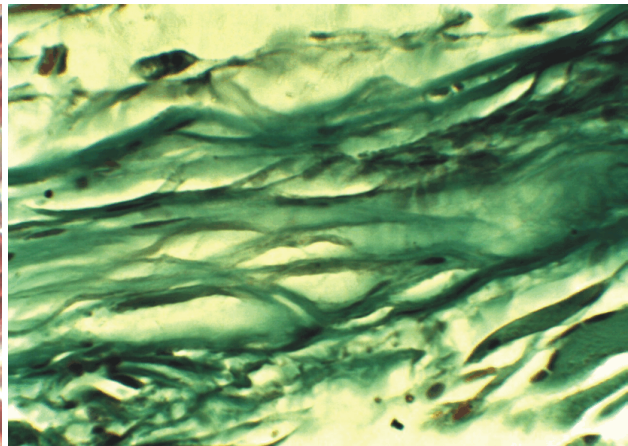


Figure 10 – Powerful fibrous attachments, which cross through the adipose infraSMAS layer (Szekely staining, ×400).

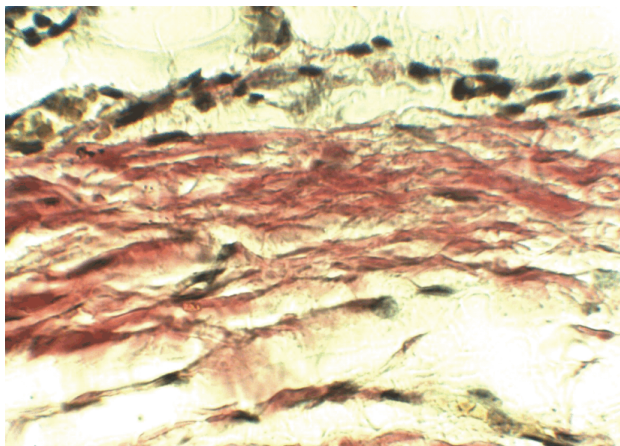


Figure 11 – Periorbital SMAS structure with medium size collagen fibers, longitudinally extended (van Gieson staining, ×400).

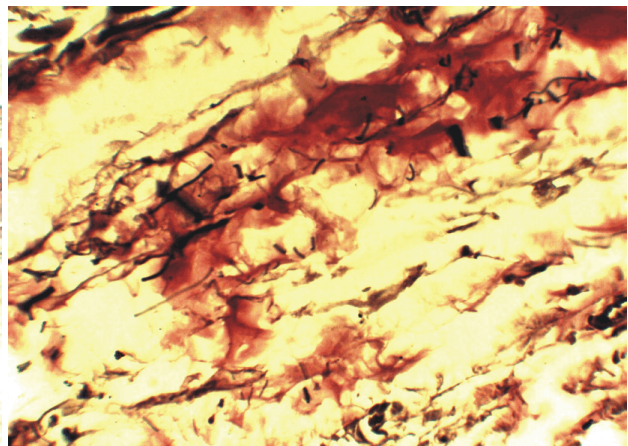


Figure 12 – Reduction of collagen and elastic fibers from SMAS structure at a 70-year-old person (Verhoeff staining, ×400).

Discussion

As our anatomical studies demonstrated, in the periorbital region, the adipose supraSMAS and the infraSMAS layers are crossed by conjunctive fibers fascicles (microseptum) oblique arranged, more or less, which come from the superficial and profound surfaces of the SMAS. The infraSMAS fibrous connecting tissue precisely compartmentalizes the face fat and acts like a barrier, which restrains the progressive movements of the superficial plans. There has been recently demonstrated that these compartments gain and loose in weight in different proportions [8].

In time, the gravity tends to weaken the ligament support and to initiate the progressive tissue migration

[9, 10], with the changing of the face tissues spatial relations. The rate of face aging partially depends on the faces fat modifications in time [11].

The SMAS exists in the periorbital region as a very well defined entity and it is acknowledged by the researchers [12, 13]. We believe that the superficial fascia of the periorbital region and implicitly the SMAS, have some characteristics which apart them from the other regions because there is a *craniofacial junction area*, to passage from one compartment of the head to another (from face to forehead), reflected in profoundness by a *pneumatized craniofacial junction area*, specifically human. There is one similar compartment in another junction area, the *cervicofacial one*, in the submandibular region, a limit that is profoundly continued by the

existence of the buccal floor. It was signaled that there fixing and tense areas of the SMAS, such as the medial side of the mandibular branch or of the orbit [14] assessing their importance is limited.

The stabilizing effect that occurs in these ligamentary connections ensures the movement that results from the muscular contraction of each zone, so that, at least in youth, the movement is not transmitted to the superficial fascia of the adjacent areas [6]. The ligament fixation has a shock-absorbing effect, which modulates the degree of sliding during the muscle contraction. At this level, the SMAS has very powerful fixation means embodied by the supraorbital ligament adhesion and by superior and inferior temporal septum nearby.

In some topographic regions can exist "weak points", which yield first during aging. Periorbital, such areas are only in the inferior and the lateral parts of the region, where the adhesions and the cutaneous muscular attachments are weaker and less dense and where progressive decreasing of fibroadipose infraSMAS layer and the tissue around the eyes is moving inferiorly. Therefore the morphological substrate of lower eyelids fall, the orbital fat herniation ("palpebral bags") and the aspect of descended face are built [7, 13]. In the superior part, the dragging of the frontal tissues is orientated to the resistance point of the supraciliary arch, involving the movement of the eyebrows, which becomes more protruding.

Following the weakening of the periorbital tissue and the change of spatial distribution of the fibroadipose layer [15, 16], the arches and the convexities disappear and give a rounded aspect of young faces [17].

The structural related differences give particular abilities in the emotional face expressions, but also have different capacities of maintaining the anatomical substrate of the face and ensure flaps nutrition in the facial lifting.

✉ Conclusions

At the junction level of the craniofacial and cervico-facial areas, there are muscular transfascial attachments, fibrous adhesions and ligaments, which fix SMAS to the profound layers. Due to the stabilizing role, we have described all these compact structures as the *sustentaculum facies*. The periorbital adhesions represent a support point, which converges toward all the adjacent ligaments orientated to those three axes of the space, and together with the zygomatic ligament form the upper portion of *sustentaculum facies*. They are the main anti-gravity suspension mechanism of the face. The infraSMAS plan is connected to the profound layer by the adhesions and

a connective conjunctive adipose tissue crossed by the neurovascular branches, a port-vessel tissue and a port-nerve similar to one from other regions. The decreasing of the percentage volume of the collagen fibers from their structure or of the sliding fibroadipose tissue during aging, explains the decreasing of the functional capacity followed by face fall.

References

- [1] Stuzin JM, Baker TJ, Gordon HL, *The relationship of the superficial and deep facial fascias: relevance to rhytidectomy and aging*, *Plast Reconstr Surg*, 1992, 89(3):441–449; discussion 450–451.
- [2] Tessier P, *Le lifting facial sous-périosté*, *Ann Chir Plast Esthet*, 1989, 34(3):193–197.
- [3] Mitz V, Peyronie M, *The superficial musculo-aponeurotic system (SMAS) in the parotid and cheek area*, *Plast Reconstr Surg*, 1976, 58(1):80–88.
- [4] Moss CJ, Mendelson BC, Taylor GI, *Surgical anatomy of the ligamentous attachments in the temple and periorbital regions*, *Plast Reconstr Surg*, 2000, 105(4):1475–1490; discussion 1491–1498.
- [5] Mendelson BC, *Surgery of the superficial musculoaponeurotic system: principles of release, vectors, and fixation*, *Plast Reconstr Surg*, 2001, 107(6):1545–1552; discussion 1553–1555, 1556–1557, 1558–1561.
- [6] Mendelson BC, *SMAS fixation to the facial skeleton: rationale and results*, *Plast Reconstr Surg*, 1997, 100(7):1834–1842; discussion 1843–1845.
- [7] Gola R, *Chirurgie esthétique et fonctionnelle de la face*, Springer-Verlag France, Paris, 2005.
- [8] Rohrich RJ, Pessa JE, *The fat compartments of the face: anatomy and clinical implications for cosmetic surgery*, *Plast Reconstr Surg*, 2007, 119(7):2219–2227; discussion 2228–2231.
- [9] Yousif NJ, *Changes of the midface with age*, *Clin Plast Surg*, 1995, 22(2):213–226.
- [10] Marten TJ, *Facelift. Planning and technique*, *Clin Plast Surg*, 1997, 24(2):269–308.
- [11] Dallara JM, *Subcutaneous tissue: anatomy and aging*, *Ann Dermatol Venereol*, 2009, 136(Suppl 6):S270–S272.
- [12] Ghassemi A, Prescher A, Riediger D, Axer H, *Anatomy of the SMAS revisited*, *Aesthet Plast Surg*, 2003, 27(4):258–264.
- [13] Coleman SR, Grover R, *The anatomy of the aging face: volume loss and changes in 3-dimensional topography*, *Aesthet Surg J*, 2006, 26(1S):S4–S9.
- [14] Ghavami A, Pessa JE, Janis J, Khosla R, Reece EM, Rohrich RJ, *The orbicularis retaining ligament of the medial orbit: closing the circle*, *Plast Reconstr Surg*, 2008, 121(3):994–1001.
- [15] Coleman SR, *Structural fat grafting*, Quality Medical Publishing, Inc., St. Louis, MO, 2004.
- [16] Gosain AK, Klein MH, Sudhakar PV, Prost RW, *A volumetric analysis of soft-tissue changes in the aging midface using high-resolution MRI: implications for facial rejuvenation*, *Plast Reconstr Surg*, 2005, 115(4):1143–1152; discussion 1153–1155.
- [17] Hamra ST, *The role of orbital fat preservation in facial aesthetic surgery. A new concept*, *Clin Plast Surg*, 1996, 23(1):17–28.

Corresponding author

Marius Valeriu Hînganu, MD, PhD, Department of Anatomy, "Grigore T. Popa" University of Medicine and Pharmacy, 16 University Street, 700115 Iassy, Romania; Phone +40744–279 704, e-mail: hanganu.marius@yahoo.com

Received: April 30, 2013

Accepted: October 1, 2013

